

Large calcific mass embolization during transfemoral aortic valve implantation

Tanya Salvatore¹, Daniela Gabrielli², Anna Laura Caterino¹,
Laura Ceriello¹, Nicola Maddestra³, Marco Zimarino^{1,3}

¹Institute of Cardiology, “G. d’Annunzio University”, Chieti, Italy

²Department of Neuroscience, Imaging and Clinical Science,
“G. d’Annunzio University”, Chieti, Italy

³Interventional Cath Lab, ASL 2 Abruzzo, Chieti, Italy

In a 82-year-old female a 22-mm stented Soprano (Sorin Biomedica Cardio, Saluggia, Italy), bioprosthesis dysfunction was documented. Computed tomography angiography (CTA) showed diffuse aortic calcifications and the presence of an aberrant right subclavian artery or arteria lusoria (AL) (Fig. 1A–D). A valve-in-valve transcatheter aortic valve implantation (TAVI) with a 26-mm Corevalve Evolut R (Medtronic, Minneapolis, MN, USA) was performed via transfemoral access. Due to blood loss, CTA was required; aside a retroperitoneal hematoma, a large calcified plaque, previously undetected at the thoraco-abdominal passage was unexpectedly detected (Fig. 1E, F), causing a 50% caliber reduction.

A careful review of a previous CTA suggested the migration of a voluminous calcification from the aortic arch, likely during system advancement.

Since the patient was asymptomatic, a conservative approach was recommended.

Six months later another CTA confirmed the entrapment of the calcified plaque in the descending aorta (Fig. 1G) without clinical signs of peripheral hypoperfusion.

Systemic embolization during TAVI remains a major issue and the protective role of filters for cerebral protection is controversial. Peripheral embolization is considered a “minor” complication, and, in the described case, the dimension of plaque caused its entrapment without clinical consequences. Its fracture could have provoked migration toward more “sensible” districts, e.g. causing visceral or limb ischemia. With the exponential growth of TAVI, nowadays proposed also to treat younger patients and lower risk populations, a careful evaluation of the embolic risk and the development of dedicated algorithms should be advocated.

Conflict of interest: None declared

Address for correspondence: Marco Zimarino, MD, PhD, Institute of Cardiology, “G. d’Annunzio” University – Chieti, C/o Ospedale SS, Annunziata, Via dei Vestini, 66013 Chieti, Italy, tel: +39-0871-41512, fax: +39-0871-402817, e-mail: m.zimarino@unich.it

Received: 26.10.2018

Accepted: 6.01.2019

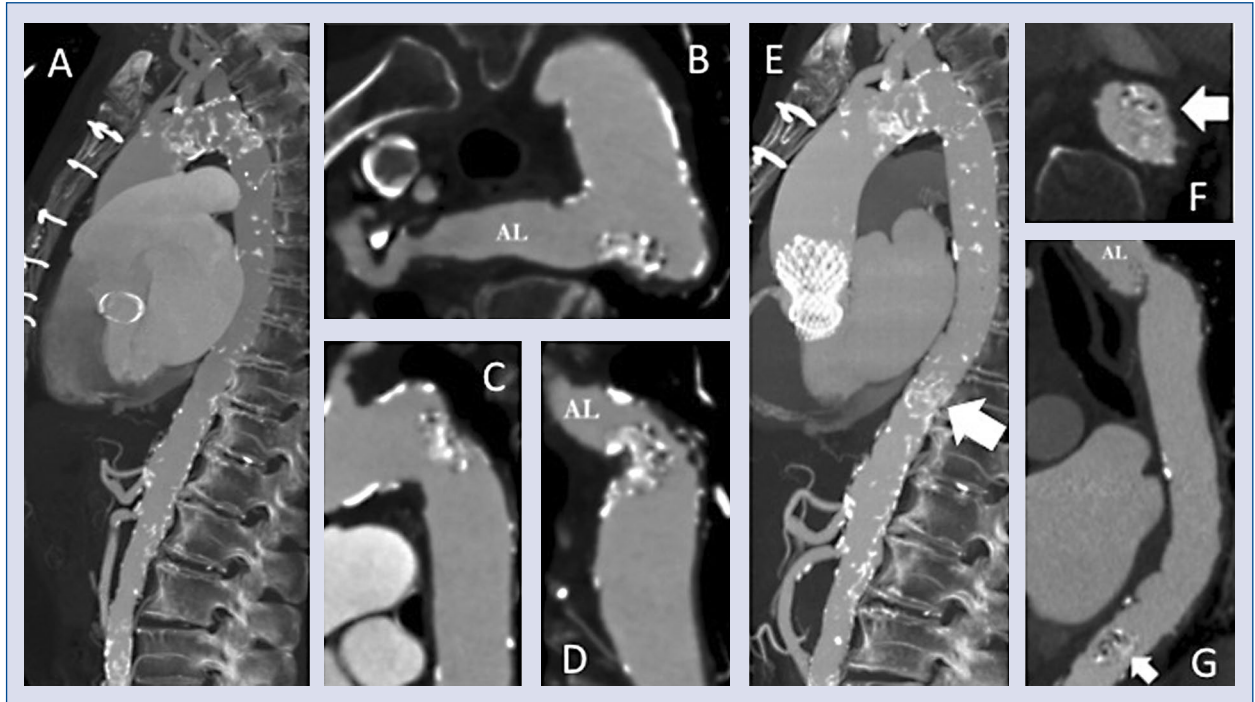


Figure 1. Maximum intensity projection (MIP) documents a severely calcified aortic arch (A). multi planar reformation (MPR) images show an arteria lusoria (AL) in axial (B) and large calcifications of aortic arch in sagittal (C) and coronal (D) views. After transcatheter aortic valve implantation (E), MIP shows the presence of previously undetected calcifications at the thoraco-abdominal district (arrow), with a bulk mass entrapped in the descending aorta (computed tomography axial scan, F), later confirmed at computed tomography angiography performed at 6-month follow-up (coronal view, G).