

Life-threatening acute myocardial infarction due to left main dissection during radiofrequency transcatheter ablation of atrial tachycardia

Alessandro Cafaro¹, Annagrazia Cecere², Roberta Ruggieri², Elia Iorio¹,
Francesco Giardinelli³, Marco Matteo Ciccone², Vito Casamassima¹,
Massimo Grimaldi¹, Tommaso Langialonga¹, Martino Pepe²

¹Department of Cardiology, General Hospital “F. Miulli”, Acquaviva delle Fonti, Bari, Italy

²Cardiovascular Diseases Section, Department of Emergency and Organ Transplantation (DETO),
University of Bari, Bari, Italy

³Department of Cardiology, Hospital “Santissima Annunziata”, Taranto, Italy

A 65-year-old woman was hospitalized for recurrent episodes of atrial tachycardia; echocardiography showed dilated left ventricle with depressed systolic function (ejection fraction 30%), without significant epicardial coronary stenoses at angiography.

An electrophysiological study identified the origin of the arrhythmia in the posterior and mid-septal walls of the right atrium. A radiofrequency transcatheter ablation (RTA) was performed through the right femoral vein approach: the right atrium was reached and a radiofrequency energy application of 35 W was delivered. During an inducibility test the patient complained of retrosternal pain associated with ST elevation in the V1 lead (Fig. 1A–D).

The subsequent emergency angiography showed ostial subocclusion of the left anterior descending (LAD) artery, suggesting a coronary

dissection. At the second contrast injection the distal left main (LM) occluded. A percutaneous coronary intervention with a 3.5 × 38 mm zotarolimus-eluting stent implantation at the LAD ostium was performed (Fig. 1E–J). After restoration of a Thrombolysis in Myocardial Infarction (TIMI) flow grade 3 in the LAD, an intravascular ultrasound (IVUS) run revealed a dissection flap at the level of the LM, managed with a second 4.5 × 15 mm zotarolimus-eluting stent implantation. A good angiographic result was confirmed by a final IVUS run that demonstrated correct stent apposition through the LM-LAD axis (Fig. 1K–O). At 1 month follow-up patient's ejection fraction rose to 45%.

According to available research, this is the only case in the literature of life-threatening LM dissection during right atrium RTA through a venous approach in which a fortuitous coronary ostia engagement can definitely be ruled out.

Conflict of interest: None declared

Address for correspondence: Dr. Annagrazia Cecere, Cardiovascular Diseases Section, Department of Emergency and Organ Transplantation (DETO), University of Bari, Italy, tel: +0039 080 5592996, e-mail: agcecere@gmail.com

Received: 31.10.2018

Accepted: 9.11.2018

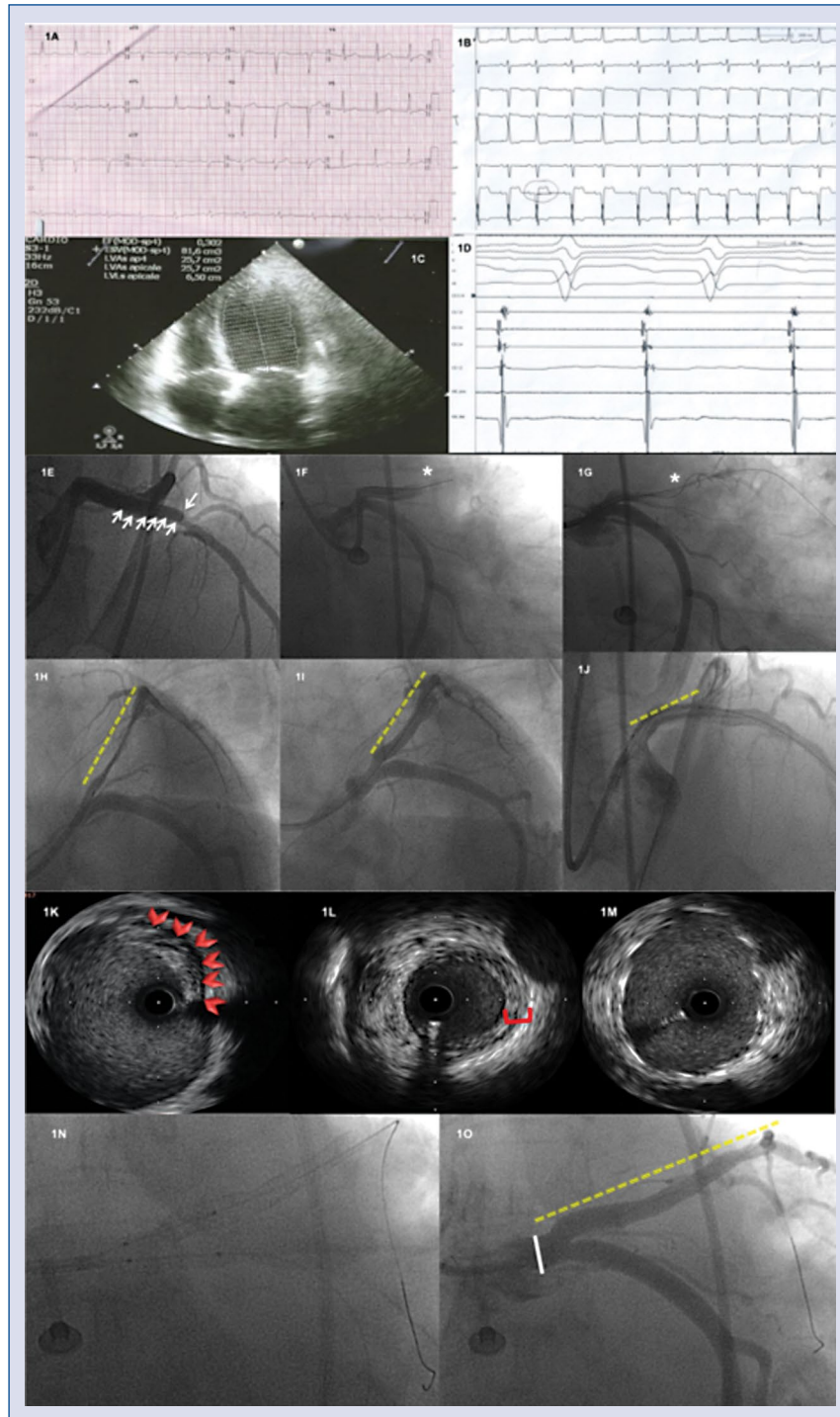


Figure 1. **A.** Normal electrocardiogram at admission; **B.** Electrocardiogram revealing ST elevation in V1; **C.** Trans-thoracic echocardiography at admission showing dilated left ventricle with 30% ejection fraction; **D.** Monitor polygraph record during transcatheter ablation; **E.** Left anterior descending coronary artery (LAD) dissection (white arrowheads); **F, G.** Abrupt total LAD closure (asterisks) and guidewire crossing; **H, I.** LAD drug eluting stent (DES) positioning and implantation (yellow dashed lines); **J.** DES positioning on left main (LM)-LAD (yellow dashed lines); **K, L, M.** Intravascular ultrasound (IVUS) run: IVUS images showing the extension of the dissection flap at the level of the LM (K: red arrowheads) and the optimal stent covering after stenting (M). IVUS at the level of the mid LAD shows medial thickening (L: between brackets); **N:** Final optimization with kissing balloon technique; **O:** Final angiographic result after LM-LAD percutaneous coronary intervention with DES implantation (yellow dashed lines).