

# Multimodal imaging diagnosis and characterization of quadricuspid aortic valve

Jose Antonio Linares Vicente<sup>1</sup>, Victoria Mayoral Campos<sup>2</sup>,  
Gustavo Francisco Angulo Balduzzi<sup>3</sup>

<sup>1</sup>Cardiology Department, Interventional Cardiology Unit,  
“Lozano Blesa” University Hospital, Zaragoza, Spain

<sup>2</sup>Radiology Department, “Lozano Blesa” University Hospital, Zaragoza, Spain

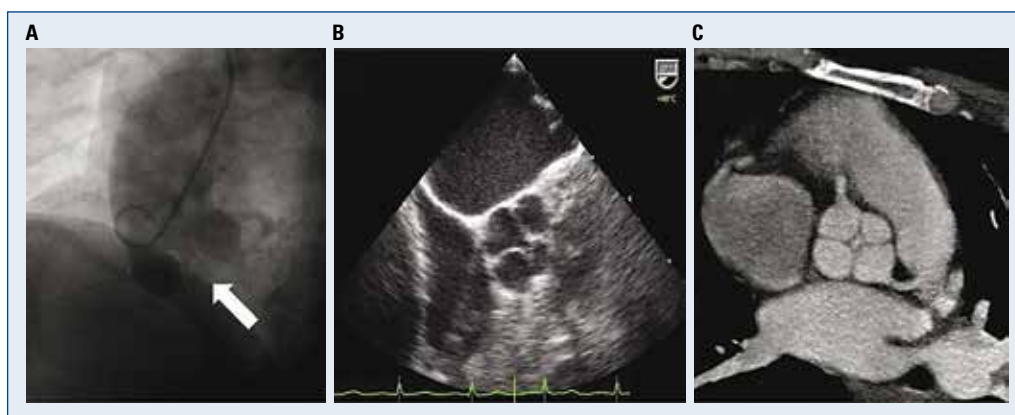
<sup>3</sup>Cardiology Department, Barbastro Hospital, Huesca, Spain

A 46-year-old woman was sent for cardiac catheterization due to symptomatic severe aortic regurgitation (AR) with preserved systolic left ventricular function on transthoracic echocardiogram. Aortography showed an atypical aortic valve morphology, and a remarkable absence of cusps coaptation (Fig. 1A, white arrow). Transesophageal echocardiogram showed a severe AR due to a dysfunctional aortic valve with 4 cusps (Fig. 1B). Retrospective electrocardiography-gated multidetector cardiac computed tomography (MDCCT) confirmed a quadricuspid aortic valve morphology (Fig. 1C), with a smaller anomalous fourth cusp in the anterior position between right and left aortic cusps (type B according to Hurwitz and Robert’s classification), without further aortic root or ascending aortic abnormalities: aortic valve ring area diameters were  $18 \times 26.6$  mm (area  $415 \text{ mm}^2$ ),  $36.7 \times 32.4$  mm for aortic root,  $31.5$  mm for sinotubular junction, and  $34$  mm for

ascending aorta. No other structural cardiac defect was found.

Quadricuspid aortic valve is a rare congenital cardiac defect with an estimated frequency of 0.05%. Approximately 75% present with significant AR due to the absence of central cusps coaptation, typically without other aortic root abnormalities but coexisting congenital cardiac defect in up to 30% of cases. Ascending aortic dilatation has been recently reported also in 30% of cases. Most patients develop symptoms at middle-age (40–60 years old). Surgical aortic valve replacement is the preferred treatment, although in selected cases valve repair (surgical excision of the small fourth cusp and resuspension of the other cusps achieving tricuspid functionality) can be considered. MDCCT provides clear images and definite anatomical information for classification or surgical considerations.

**Conflict of interest:** None declared



**Figure 1.** Atypical angiographic aortic valve morphology and absence of cusps coaptation (A, white arrow). Dysfunctional aortic valve with 4 cusps in transesophageal echocardiogram (B). Confirmed type B quadricuspid aortic valve by multidetector cardiac computed tomography (C).

**Address for correspondence:** Dr. Jose Antonio Linares Vicente, MD PhD, Cardiology Department, Interventional Cardiology Unit, “Lozano Blesa” University Hospital, Avda. San Juan Bosco, 15, 50009, Zaragoza, Spain, tel: +34 620140664, e-mail: joselinares1979@hotmail.com

Received: 06.02.2017

Accepted: 08.07.2017