

# The role of intravascular ultrasound guidance in the treatment of intramural hematoma probably caused by spontaneous coronary artery dissection in a young woman with acute anterior myocardial infarction

Atila Iyisoy<sup>1</sup>, Murat Celik<sup>2</sup>, Turgay Celik<sup>1</sup>, Uygur Cagdas Yuksel<sup>1</sup>

<sup>1</sup>Department of Cardiology, Gulhane Military Medical Academy, School of Medicine, Ankara, Turkey

<sup>2</sup>Department of Cardiology, Van Army District Hospital, Van, Turkey

## Abstract

*Spontaneous coronary artery dissection (SCAD) is known to be a rare but fatal cause of acute coronary syndromes. It is more frequent in young women, particularly in the peripartum period. Intravascular ultrasound (IVUS) has an important role in the diagnosis and management of SCAD. Intramural hematoma that occurs between adventitial and media layer of the vessel wall may occlude the true lumen. IVUS can identify intimal tears, the extension of intramural hematoma and show the adequate compression of intramural hematoma after percutaneous coronary intervention. We present a case of intramural hematoma caused by SCAD in a young woman presenting with acute anterior myocardial infarction, and the role of IVUS in the diagnosis and management of SCAD. (Cardiol J 2012; 19, 5: 532–535)*

**Key words: spontaneous coronary artery dissection, intramural hematoma, intravascular ultrasound, acute myocardial infarction**

## Introduction

Spontaneous coronary artery dissection (SCAD), which is defined as an intramural hematoma occurring between the adventitial layer and the media of the vessel wall, is an unusual cause of acute coronary syndrome (ACS). The number of such cases reported has been increasing due to the growing use of coronary angiography (CAG). The etiology remains uncertain.

Although SCAD has been observed in patients with coronary atherosclerosis, most of them have been reported in young to middle age patients without cardiovascular (CV) risk factors. Women, especially in late pregnancy or the early postpartum pe-

riod, are more commonly involved than men [1]. The prognosis of these patients is generally poor and the majority of them are diagnosed post mortem [2]. Nevertheless, the prognosis is worse in women in the non-peripartum period [1].

Various therapeutic options including medical therapy, percutaneous coronary intervention (PCI) and surgery have been utilized, but the optimal strategy is yet to be defined. The current use of intravascular ultrasound (IVUS) can facilitate the diagnosis and treatment of SCAD [3]. Herein, we report the case of a 30 year-old woman which showed healing of the dissection with coronary artery stenting, and the role of IVUS in this era.

Address for correspondence: Murat Celik, MD, Staff Cardiologist, Department of Cardiology, Van Army District Hospital, 65040 Van, Turkey, tel: +90 432 2220224, fax: +90 432 2220245, e-mail: drcelik00@hotmail.com

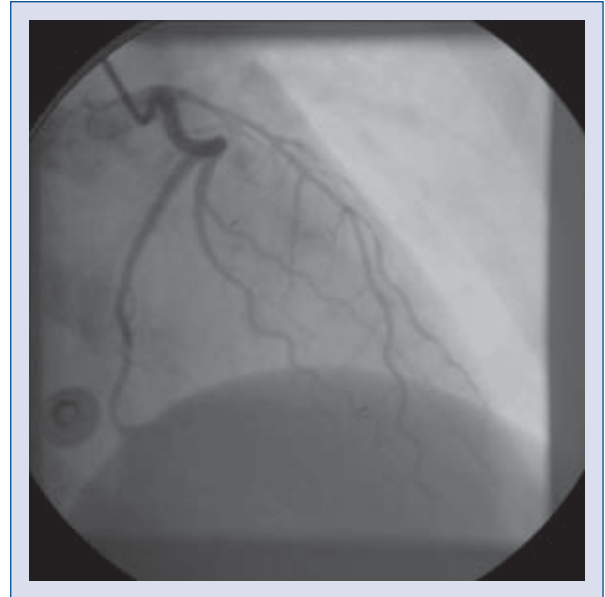
Received: 21.06.2011

Accepted: 21.07.2011

### Case report

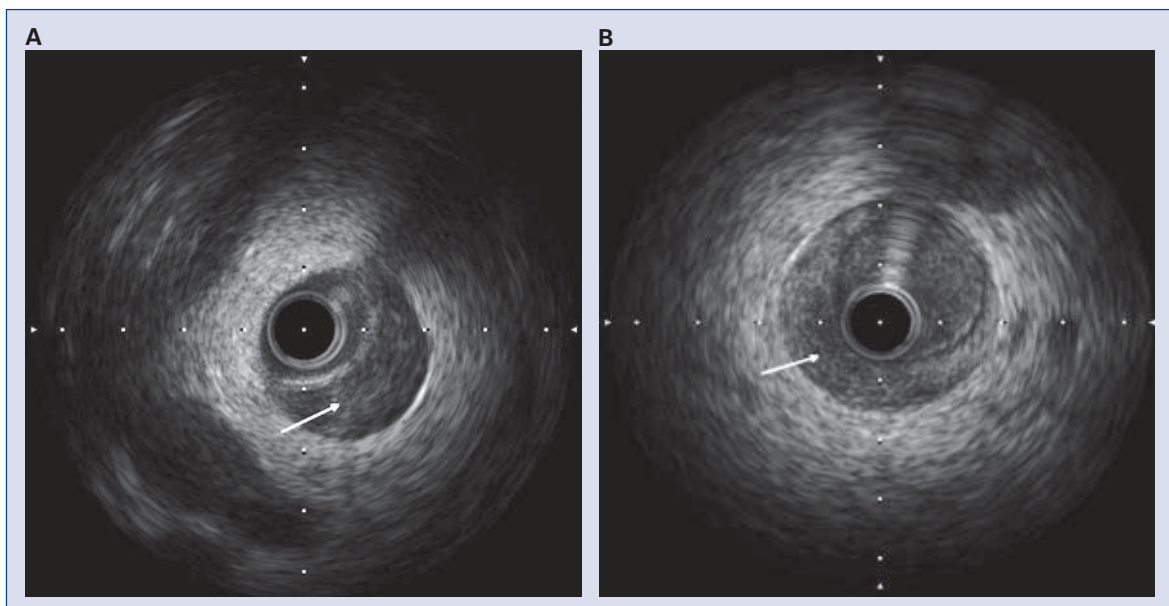
A 30 year-old female without any CV risk factors was admitted to our hospital for resting squeezing chest pain of one hour's duration. She did not have a history of pregnancy. Electrocardiogram (ECG) at admission showed ST segment elevation in leads V2–V6. Transthoracic echocardiography showed hypokinesia in the mid-apical segments of anterolateral left ventricular (LV) wall and apical segment of LV. There was no abnormality in whole blood count and standard biochemical tests at admission. We planned thrombolytic therapy because of early admission. Unfortunately, thrombolytic therapy was stopped in the early period (within 5 min) because of bleeding from her transvenous routes. Afterwards, the patient underwent urgent CAG for the evaluation of coronary arteries.

The CAG revealed a generally very thin artery with probably a long spiral dissection involving the proximal and mid segments of left anterior descending artery (LAD) with TIMI 2 flow (Fig. 1). Because of the disappearance of ST-segment elevation during CAG, primary PCI was not performed and treatment with aspirin, unfractionated heparin and a beta-blocker was started. Her symptoms were resolved completely with this therapy. On the second day of hospitalization, the patient underwent control CAG which revealed that LAD was narrowed without any evidence of intimal flap or coronary flow impairment. Subsequently, we performed IVUS ex-

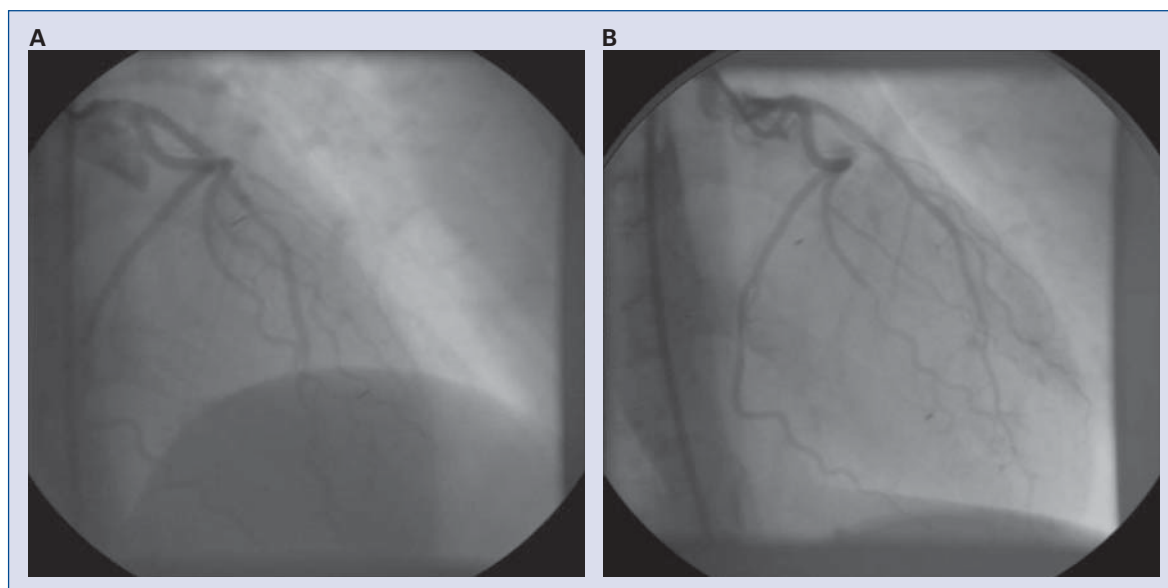


**Figure 1.** Coronary angiography shows a long spiral dissection which caused a narrowed lumen in the proximal and mid segments of left anterior descending artery with TIMI 2 flow distally.

amination to investigate the presence and the extent of the dissection. IVUS examination demonstrated medial dissection with an intramural hematoma starting from the proximal segment of LAD and progressing into distal segment of LAD, and no evidence of atherosclerosis (Figs. 2A, B).



**Figure 2.** Intravascular ultrasound study denotes intramural hematoma compressing lumen area and no evidence of atherosclerosis (A, B), arrows denote intramural hematoma compressing lumen area.



**Figure 3.** The lumen area was optimal and the procedural result was excellent with TIMI-3 flow distally just after stenting (A), and at three-month control (B).

Our medical therapy, including heparin, caused no beneficial effect on spontaneous dissection and intramural hematoma. In light of the foregoing analysis, we decided to implant two stents in LAD. A  $3.0 \times 20$  mm stent was implanted into the proximal segment and a  $2.5 \times 20$  mm stent was implanted into the distal segment of LAD. The lumen area was optimal and the procedural result was excellent with TIMI-3 flow distally (Fig. 3A). Her complaints and ECG changes were resolved after stent implantation at follow-up. She was discharged in a very good condition with an optimal medical treatment. At three-month follow-up she did not have any complaint, and control CAG revealed no significant in-stent restenotic tissue (Fig. 3B).

### Discussion

The principal abnormality observed in SCAD is the development of intramural hematoma, and when present this can result in ACS. The optimal management approach for this challenging condition is still being debated. Therapy depends on the number of vessels involved, the site of dissection and the distal coronary blood flow [4]. Medical therapy (aspirin, unfractionated heparin, beta-blocker), PCI and surgery are the therapeutic options for the treatment of SCAD. Spontaneous healing of the dissection with medical therapy alone has been reported rarely [4].

PCI has been the most frequent therapeutic option in the treatment of SCAD. PCI with stent implantation can be necessary to restore distal flow in a narrowed vessel in patients with intramural hematoma not resolved after medical therapy, especially in single vessel disease. However, it should be kept in mind that stent deployment can cause the displacement and facilitate propagation of the dissection or propagation of hematoma in the absence of significant atheroma plaque, and can cause vessel occlusion, especially at a further site to a fragile vessel wall [5]. Also, PCI carries another potential risk of stent deployment into the false lumen, causing either obliteration of coronary flow or arterial rupture. The use of IVUS can identify intimal tears, provide important information about the length of dissection and vessel size, the extension of intramural hematoma and the adequate compression of intramural hematoma after PCI. Furthermore, the use of IVUS can guide PCI and can minimize the incidence of PCI-related complications [5].

There was a probably excessive coronary dissection and the caliber of LAD was highly narrowed in our patient at CAG. IVUS examination reinforced the findings of CA4G and additionally showed an intramural hematoma. Although the length of stent required in an extensive dissection can be associated with restenosis and the need for repeated interventions, we did not observe restenosis at three-month control CAG in our patient.

In conclusion, the principal abnormality observed in SCAD is the development of intramural hematoma, and when present this can cause ACS. Thrombolytic therapy and medical therapy probably have no beneficial effect in the setting of acute myocardial infarction caused by SCAD, especially in young patients. However, PCI with stent implantation can be necessary to restore distal flow in such a narrowed vessel. Furthermore, IVUS can guide PCI to confirm guidewire placement in the true lumen, minimize the incidence of PCI-related complications, sealing the dissection, adequate stent expansion, the adequate compression of intramural hematoma after stent implantation.

**Conflict of interest:** none declared

## References

1. Mahenthiran J, Revankar R, Koka V, Hoo J, Shenoy M. Spontaneous coronary artery dissection presenting as acute myocardial infarction. *J Natl Med Assoc*, 2000; 92: 87–90.
2. Mortensen KH, Thuesen L, Kristensen IB, Christiansen EH. Spontaneous coronary artery dissection: A Western Denmark Heart Registry study. *Catheter Cardiovasc Interv*, 2009; 74: 710–717.
3. Arnold JR, West NE, van Gaal WJ, Karamitsos TD, Banning AP. The role of intravascular ultrasound in the management of spontaneous coronary artery dissection. *Cardiovasc Ultrasound*, 2008; 6:24.
4. Erdim R, Gormez S, Aytakin V. Spontaneous healing of spontaneous coronary artery dissection: A case report. *J Invasive Cardiol*, 2008; 20: E237–E238.
5. Chue CD, Routledge HC, Townend JN. Spontaneous coronary artery dissection and the role for percutaneous coronary intervention: To treat or not to treat? *J Invasive Cardiol*, 2009; 21: E44–E47.