

Myocarditis after mRNA COVID-19 vaccine administration in adult female

Piotr Hamala, Konrad Szymczyk, Jarosław D. Kasprzak

1st Department and Chair of Cardiology, Medical University of Lodz, Poland

This case study presents a 37-year-old female devoid of antecedent cardiovascular pathology. The subject was hospitalized following the manifestation of fatigue, dyspnea, and peripheral edema. It was observed that her symptoms began shortly (4 days) after receiving her second mRNA COVID-19 vaccination (BNT162b2 — 30 µg). Natriuretic peptides level was 1800 pg/mL while high sensitivity troponin T was normal. Electrocardiogram exhibited a normal electrical activity. The echocardiography demonstrated enlargement of the left ventricle (LV), 58 mm in diastole and 48 mm in systole, along with impaired function indicated by a LV ejection fraction (LVEF) of 30% and a global longitudinal strain (GLS) of –10% (Fig. 1A). Comprehensive infectious tests were conducted, and no communicable agents were detected. Heart

failure pharmacology commenced, bisoprolol 5 mg, perindopril 2.5 mg, eplerenone 50 mg, empagliflozin 10 mg and ivabradine 5 mg bid. 44 days post-symptom onset, magnetic resonance imaging depicted intramural late gadolinium enhancement in the interventricular septum's basal and middle segments, alongside a dilated LV (volumes in diastole and systole: 252 mL, 159 mL) as well as an enhanced LVEF at 37% (Fig. 1C, D; **Suppl. Video 1**). Six months later, during follow-up, the LV systolic function improved, reaching an EF of 50% and GLS of –17.5% (Fig. 1B). Additionally, N-terminal-pro-B-type natriuretic peptide reduced by 218 pg/mL, and the symptoms decreased to first New York Heart Association class. This case underscores the likelihood of reversible dysfunction of the LV, likely tied to myocarditis following vaccination.

Conflict of interest: None declared

Address for correspondence: Jarosław D. Kasprzak, MD, FESC, FACC, FISCU(d), Professor of Medicine, 1st Department and Chair of Cardiology, Medical University of Lodz, Bieganski Hospital, ul. Kniaziewiczza 1/5, 91–347 Łódź, Poland, tel: +48 42 251 62 16, fax: +48 42 251 60 15, e-mail: kardiologia@umed.lodz.pl

Received: 18.12.2022

Accepted: 23.06.2023

This article is available in open access under Creative Common Attribution-Non-Commercial-No Derivatives 4.0 International (CC BY-NC-ND 4.0) license, allowing to download articles and share them with others as long as they credit the authors and the publisher, but without permission to change them in any way or use them commercially.

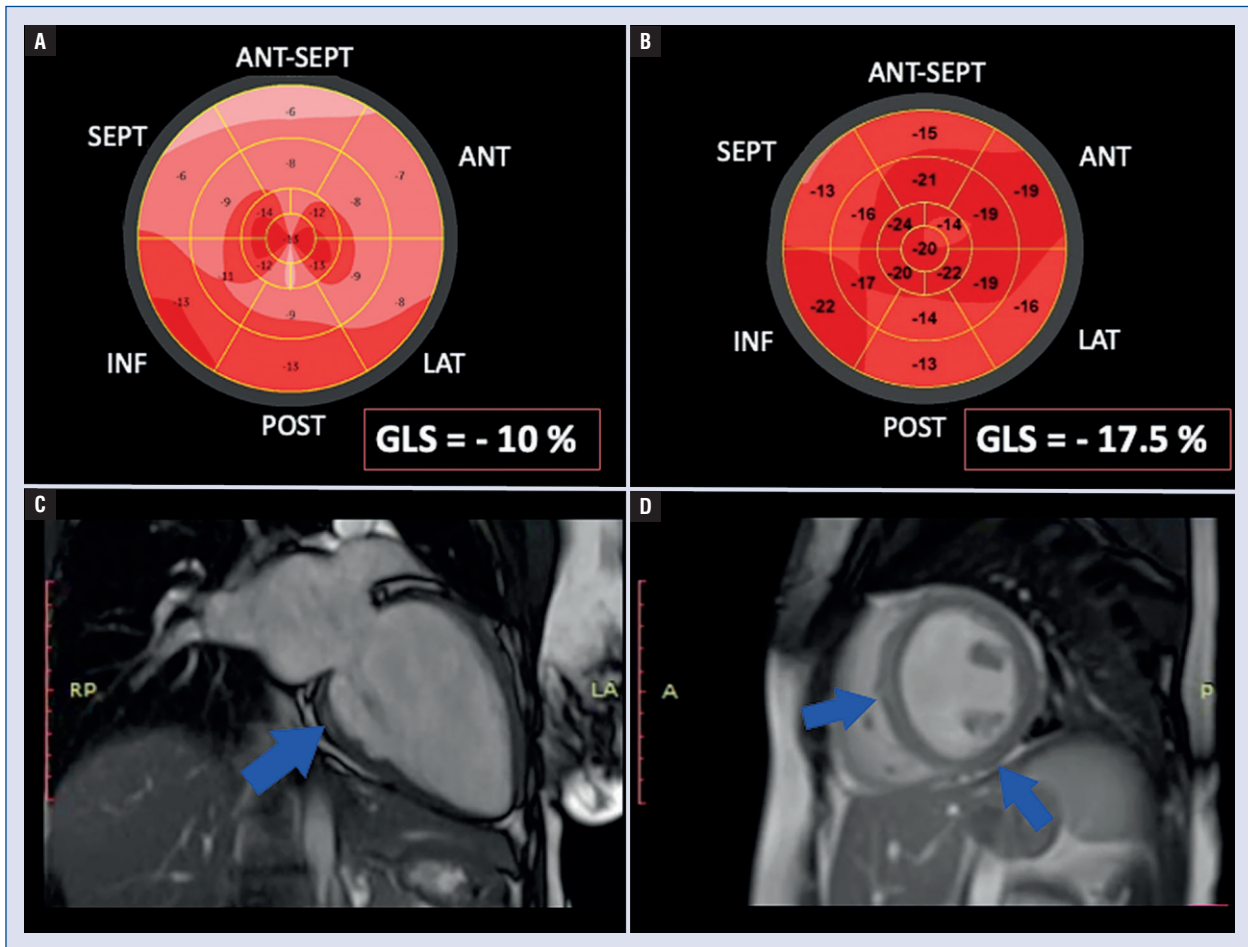


Figure 1. **A.** Left ventricular global longitudinal strain polar map, 4 days after vaccination; **B.** Left ventricular global longitudinal strain polar map after 6 months of follow-up; **C.** Late gadolinium enhancement (blue arrows) in magnetic resonance imaging — 2-chamber view, 44 days after vaccination; **D.** Late gadolinium enhancement (blue arrows) in magnetic resonance imaging — left ventricular short axis, 44 days after vaccination.