

Epicardial fat necrosis: An uncommon etiology of chest pain

Abdur Baig¹, Bruce Campbell², Mark Russell¹, Jai Singh¹, Sonia Borra¹

¹Department of Medicine, Kingsbrook Jewish Medical Center, Brooklyn, NY, USA

²Department of Radiology, Kingsbrook Jewish Medical Center, Brooklyn, NY, USA

Abstract

Epicardial fat necrosis (EFN) is a rare cause of severe chest pain. We present a case of EFN successfully treated conservatively. With the advent of computed tomography and magnetic resonance imaging, the diagnosis can be made more precisely, avoiding the need for surgical intervention. We review the clinical characteristics, pathogenesis and treatment options of EFN. (Cardiol J 2012; 19, 4: 424–428)

Key words: epicardial fat necrosis, chest pain, computed tomography

Introduction

Epicardial fat necrosis (EFN) is a self-limiting, benign cause of chest pain. The first case was reported by Jackson et al. [1] in 1957, and there have since been 25 other cases reported in English-language literature, including the present one. EFN should be suspected in a patient presenting with unexplained severe precordial pain associated with the presence of a juxtacardiac mass on radiological examination of the chest. Once acute coronary syndrome has been ruled out and computed tomography (CT) or magnetic resonance imaging (MRI) has confirmed the presence of necrotic fat tissue, invasive procedures (i.e. thoracotomy) should be deferred.

Case report

A 58 year-old woman with a history of dyslipidemia and gastroesophageal reflux disease presented with intermittent, severe (10 out of 10), non-radiating, left-sided pleuritic chest pain of two weeks' duration. It was not associated with nausea, dyspnea or diaphoresis. Her medications were: esomeprazole 40 mg and rosuvastatin 20 mg daily.

On physical examination, her blood pressure was 129/82 mm Hg, heart rate 80 bpm, respirations 18/min and temperature 98.7°F. Her calculated body

mass index (BMI) was 24.2 kg/m². No significant findings were observed. Cardiac sounds were normal, without any added sounds or murmurs.

Electrocardiogram: sinus rhythm, 76 bpm. No ST-T wave abnormalities. Chest X-ray was unremarkable. Three sets of cardiac enzymes were normal, as well as blood urea nitrogen, serum creatinine, electrolytes, total protein, albumin, liver function tests, hemoglobin and white cell count.

Thallium stress test revealed no ischemia. CT scan of the chest showed a soft tissue lesion interposed between the chest wall and the pericardium, 2.5 cm high × 1.2 cm anterior-posterior × 2.5 cm transverse (Fig. 1A). The lesion was characterized by a streaky infiltration of epicardial fat with mild expansion but without invasion of the deeper cardiac structures or the chest wall. Cardiac MR revealed an epicardial lesion anterior to the right ventricle and pulmonary outflow tract that was high signal on T2 weighted images, typical of soft tissue edema, and with mild enhancement after gadolinium, typical of an active disease process (Fig. 1B). Epicardial fat necrosis was suspected.

She was treated with analgesics and this resolved her symptoms. Follow-up chest CT (Fig. 2) and cardiac MR after ten weeks showed interval resolution of the infiltrative changes, expansion, edema and enhancement of the lesion.

Address for correspondence: Sonia Borra, MD, FACP, Department of Medicine, Kingsbrook Jewish Medical Center, 585 Schenectady Avenue, Brooklyn, NY 11203, USA, tel: +1/718 604 55 91, fax: +1/718 604 55 36, e-mail: sbnephro@gmail.com

Received: 08.05.2011

Accepted: 12.05.2011

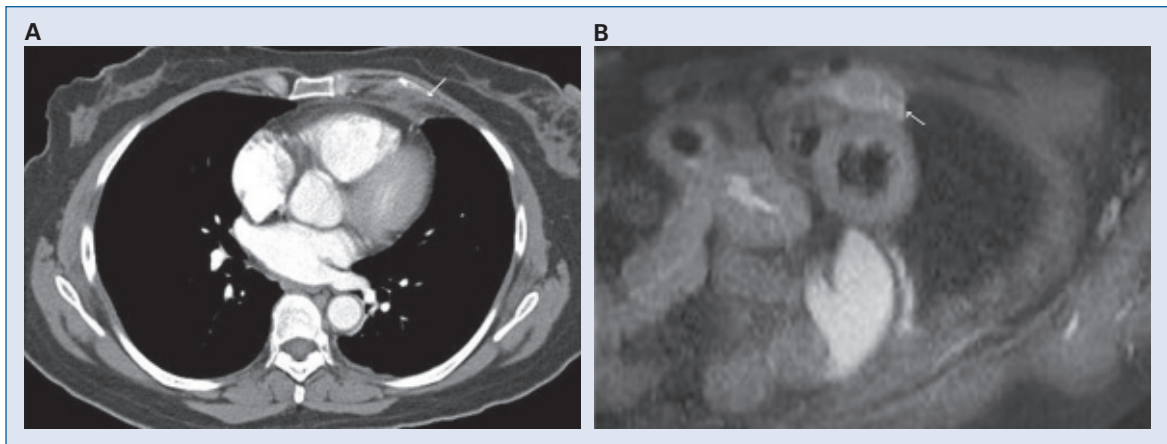


Figure 1. A. Computed tomography scan of the chest showing soft tissue lesion with patchy infiltration without invasion of the overlying chest wall, consistent with epicardial fat necrosis; **B.** Cardiac magnetic resonance reveals an epicardial lesion anterior to the right ventricle and pulmonary outflow tract demonstrating high signal on the T2 weighted images.

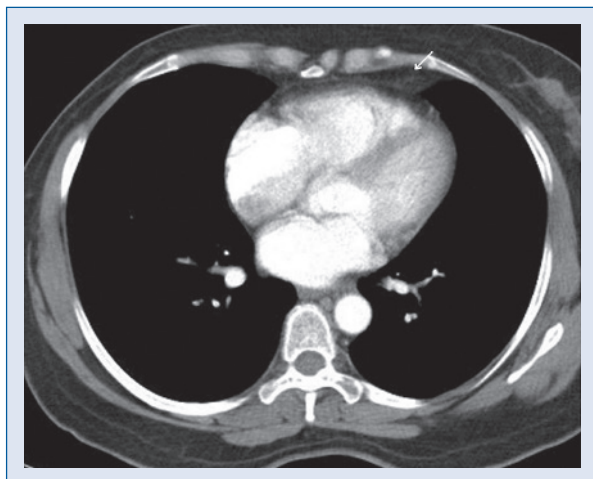


Figure 2. Follow-up computed tomography chest after 10 weeks shows marked resolution of the lesion.

Discussion

The epicardial or visceral layer of fat tissue is found in the atrioventricular and interventricular grooves and along the atria and two appendages of

the heart. In obese individuals, it can sometimes completely cover the epicardial surface. The myocardium and epicardial fat are in close contact and share the same microcirculation.

Epicardial fat evolves from the brown adipose tissue during embryogenesis, and has a characteristically smaller adipocyte size and higher uptake and release of fatty acids compared to other fat tissues. Pericardial fat has a different embryologic origin, and does not share the metabolic properties of epicardial fat (Table 1). The functions of epicardial fat may include protection of the myocardium against hypothermia, and as a provider of energy source during periods of high energy demand.

Several proinflammatory cytokines are also produced by the epicardial fat. These include tumor necrosis factor-alpha, interleukin-6, leptin, and angiotensinogen. Due to its proximity to the myocardium, they could influence or amplify the atherogenic inflammation of underlying plaques. Factors that modulate the equilibrium between protective and unfavorable functions are unknown. The Framingham heart study showed a correlation between the volume of epicardial fat and the risk of coronary artery disease, independently of other indicators [2].

Table 1. Difference between epicardial and pericardial fat; source [2].

	Epicardial fat	Pericardial fat
Amount	20% to 50% of cardiac mass	20% of cardiac mass
Location	Between the myocardium and the visceral pericardium	Outside the visceral pericardium and on the external surface of the parietal pericardium
Embryologic origin	Splanchnopleuric mesoderm	Primitive thoracic mesenchyme
Blood supply	Branches of the coronary arteries	Non-coronary sources, like pericardiophrenic branch of the internal mammary artery

Table 2. Cases of epicardial/pericardial fat necrosis published in English-language literature.

Pt. no.	Age (years)/Sex	Initial symptom	Physical examination	ECG/Holter	Chest radiography findings	Computed tomography findings	Size [cm]	Treatment	Author, year
1	52/M	CP, right side	BMI 29.8, overweight, tenderness over right fifth rib	Normal	Mass over right dome of diaphragm	Not available	5 × 2.5 × 2	Surgery	Jackson et al., 1957
2	63/M	CP, left side	BMI 31.6, obese, fever, cough	An ancient healed posterior MI	Rounded juxtacardiac mass	Not available	8 × 4.5 × 2.5	Surgery	Jackson et al., 1957
3	47/F	CP, left side	BMI 39.3, obese	Normal	Mass over left interlobar fissure	Not available	7.4 × 6 × 2.5	Surgery	Jackson et al., 1957
4	23/M	CP, left side	BMI 21.9, normal weight, dyspnea	Normal	Left lower lung density	Not available	7 × 4.5 × 2	Surgery	Kasserman, 1958
5	46/M	CP, left side, syncope	BMI 21.9, normal weight, dyspnea, low BP, tachycardia	Occasional ventricular pre-systole	Juxtacardiac mass, left cardiac border	Not available	10 × 7.5 × 3	Surgery	Chester et al., 1959
6	56/M	CP, right side	Normal	Not available middle lobe	Oval density, right	Not available	9 × 7 × 1.5	Surgery	Perrin, 1960
7	42/F	CP, left side	Fever	Normal	Mass lateral to cardiac apex	Not available	3 × 2.5 × 2.5	Surgery	Kyllonen et al., 1961
8	40/M	CP, left side	Obese, fever, tenderness on left chest wall	Not available	Mass attached with cardiac silhouette	Not available	7.5 × 5 × 4.5	Surgery	Chipman et al., 1962
9	51/M	CP, left side	Not available	Normal	Shadow lateral to the heart	Not available	2.5 × 5	Surgery	Kylloenen, 1964
10	23/F	CP, left then right	Moderately obese, otherwise normal findings	Normal	Right costophrenic angle mass	Not available	4.5 × 1.5 × 1	Surgery	Behrendt et al., 1968
11	50/M	CP, left side	Moderately obese, otherwise normal findings	Normal	Shadow to left of the apex of the heart	Not available	1.5	Surgery	Takkunen et al., 1970
12	52/M	Acute severe	Obese	Normal	In three, masses adjacent to the heart, and one had an opacity extending between the left lower lobe and lingula	Not available	Ranged from	Surgery	Wychulis et al., 1971
13	63/M	low anterior CP	Obese	Normal		Not available	5 × 2.5 × 2 to	Surgery	Wychulis et al., 1971
14	64/M	on the side of the lesion (three on	Obese	Normal		Not available	8 × 4.5 × 1.5	Surgery	Wychulis et al., 1971
15	47/F	left, one on right)	Obese	Normal		Not available		Surgery	Wychulis et al., 1971



Table 2. cont. Cases of epicardial/pericardial fat necrosis published in English-language literature.

Pt. no. (years)/Sex	Age	Initial symptom	Physical examination	ECG/Holter	Chest radiography findings	Computed tomography findings	Size [cm]	Treatment	Author, Year
16	58/F	CP, left side	BMI 28.1, overweight, rales in the left lung base	Tachycardia, RBBB, ST abnormalities	Left pericardial mass	Not available	3 × 1.5	Surgery	Webster et al., 1974
17	37/F	CP, right side	BMI 19.7, normal weight, right chest tenderness	Normal	Tissue density right cardiophrenic angle	Not available	4 × 1.5 × 1	Surgery	Stephens et al., 1988
18	67/F	CP, left side	Non-obese, fever, diminished breath sound	Nonspecific ST-T wave changes	Left lower lobe mass, left pleural effusion	Anterior left chest mass, abutting left heart margin	3 × 3	Surgery	Bensard et al., 1990
19	55/M	CP, left side	BMI 25.9, overweight, diminished breath sound	Nonspecific ST-T wave changes	Left pleural effusion, fracture sternum	Anterior left chest mass, abutting left heart margin	5 × 3.5 × 2	Surgery (VATS)	Inoue et al., 2000
20	45/M	Coughing up of blood	Not reported	Not reported	Not reported	Increased attenuation in pericardial fat	Not reported	Not reported	Takao et al., 2004
21	54/F	CP	Normal	Normal	Left paracardiac density	Lesion adjacent to pericardium	Not reported	Analgesics	Pineda et al., 2005
22	50/M	CP, left side	Normal	Not reported	Left paracardiac mass	Low attenuation	Not reported	Surgery	Pineda et al., 2005
23	47/M	Dizziness	BMI 22.3, normal weight, mild leg edema	Paroxysmal atrial tachycardia	Mass, right side base of cardiac silhouette	Unenhanced solid mass to the right atrium	6 × 5	Surgery	Lee et al., 2007
24	55/F	CP, left side	Shortness of breath	Not reported	Normal	Pericardial fat necrosis	Not reported	NSAID	v d Heuvel et al., 2010
25	53/Not reported	CP, left side	Normal	Not reported	Normal	Inflammatory fatty mass	Not reported	NSAID	Coulier, 2010
26	58/F	CP, left side	BMI 24.2, normal weight	Normal sinus rhythm	Left basilar subsegmental atelectasis	Focal soft tissue lesion, infiltration with epicardial fat	2.5 × 1.2 × 2.5	NSAID	Present case

Pt — patient; M — male; F — female; ECG — electrocardiogram; CP — chest pain; MI — myocardial infarction; NSAID — non-steroidal anti-inflammatory drug; BMI — body mass index; RBBB — right bundle branch block; VATS — video-assisted thoracoscopic surgery

Table 2 shows the clinical characteristics, treatments and outcomes of all 26 cases of EFN reported in the English-language literature including this present one. The mean age was 49.9 years (range 23 to 67). There were 15 males and ten females with the sex of one patient unreported. Obesity was reported in nine patients, overweight in three and normal BMI in five. In nine cases, no information about BMI is provided.

The presenting symptom was mostly left-sided chest pain in a previously healthy individual, sudden and severe, radiating to the left shoulder and associated with dizziness, syncope, dyspnea, tachycardia and diaphoresis in some. One patient reported hemoptysis (case 20), and case 5 presented with shock requiring vasopressors. A pericardial friction rub was heard in cases 5 and 9.

Electrocardiogram was normal in 14 patients and showed non-specific ST-T wave changes in two cases (18 and 19). Paroxysmal atrial tachycardia was recorded in case 23, right bundle branch block in case 16, and an old myocardial infarction in case 2.

The roentgenographic findings were: paracardiac opacity, pleural effusion, left lower lung density or normal.

The differential diagnosis of a juxtacardiac mass includes primary or secondary pericardial neoplasms, pericardial cyst, lung cancer, diaphragmatic herniation, bronchogenic or enteric cysts. With the advent of the CT scan, many of these diagnoses can nowadays be excluded.

The CT scan was not available in earlier cases, but it was obtained in the most recent nine, including our own. The findings were of a mass non-homogeneous with the density of fat surrounded by inflammatory changes, or fibrosis in some. The location (epicardial or pericardial) was not specified in the earlier CT scans.

In two cases (21 and 22), Pineda et al. [3] described the lesion as 'epipericardial fat necrosis'.

MRI obtained by us and in two other cases demonstrated the necrotic lesion more clearly with mild gadolinium enhancement.

Surgery was carried out in 21 of the 26 patients. No information as to treatment is given in case 20. Necrotic fat tissue of varying sizes (the largest being 10 × 7.5 × 3 cm, and the smallest 1.5 cm in diameter) was removed during the procedures. Pathological examination revealed necrotic fat cells surrounded by macrophages and neutrophils or fibrous tissue.

After surgery, all patients were reported as cured. Four patients (cases 21, 24, 25 and the present one) were treated with analgesics or non-steroidal anti-inflammatory agents. All patients treated conservatively had CT alone or CT and MRI

imaging. These techniques permitted proper identification and accurate diagnosis, resulting in the avoidance of surgery.

The mechanisms leading to EFN remain unknown. Structural anomalies of the tissue (like lipoma) may make it vulnerable to the trauma of the beating heart. Changes in pressure such as those caused by a Valsalva maneuver might cause hemorrhage in the adipose tissue and trigger the necrosis. Acute torsion of a fat pedicle has also been described. Obesity may be a contributory factor (although non-obese patients, like our own, have been diagnosed with EFN).

The histopathological description of the surgical specimens showed highly abnormal arterioles with subintimal thickening and fibrosis of moderate to severe degree, as well as medial hypertrophy with narrowing of the lumen [1] and thrombosis [4]. We hypothesize that thrombosis occurred in these abnormal vessels that irrigate the epicardial or pericardial fat tissue leading to necrosis: an 'Epipericardial Fat Infarction'.

As Fred writes [5] "textbooks of internal medicine and cardiology offer nothing on this ailment, and only one of three books devoted solely to the pericardium mentions it". Physicians should include EFN in a differential diagnosis of chest pain.

Clinical pearls

- EFN is a benign cause of chest pain.
- The classic presentation is unexplained precordial, pleuritic pain in the left lower chest with an associated juxtacardiac mass seen in chest radiography.
- The disease is self-limiting and the etiology is unknown.
- CT scans can detect the mass as having fat, sometimes clearly enough to diagnose EFN.
- Conservative management is sufficient in most instances, unless the patient's symptoms are intolerable and the diagnosis is not confirmed.

Conflict of interest: none declared

References

1. Jackson RC, Clagett OT, McDonald JR. Pericardial fat necrosis: Report of three cases. *J Thorac Surg*, 1957; 33: 723–729.
2. Iacobellis G, Willens HJ. Echocardiographic epicardial fat: A review of research and clinical applications. *J Am Soc Echocardiogr*, 2009; 22: 1311–1319.
3. Pineda V, Caceres J, Andreu J et al. Epipericardial fat necrosis: Radiologic diagnosis and follow-up. *Am J Roentgenol*, 2005; 185: 1234–1236.
4. Webster MW Jr, Bahnson HT. Pericardial fat necrosis. Case report and review. *J Thorac Cardiovasc Surg*, 1974; 67: 430–433.
5. Fred HL. Pericardial fat necrosis: A review and update. *Tex Heart Inst J*, 2010; 37: 82–84.