

# Severe cardiac insufficiency as a result of complicated myocardial infarction — choice of therapy

Agata Bielecka<sup>1</sup>, Magdalena Wierzbicka<sup>1</sup>, Gerry O'Driscoll<sup>2</sup> and Jan Henryk Goch<sup>1</sup>

<sup>1</sup>Department of Cardiology and Cardiosurgery No. 1, Medical University, Łódź, Poland

<sup>2</sup>Advanced Heart Failure and Cardiac Transplant Service, Royal Perth Hospital, Australia

## Abstract

*On 28<sup>th</sup> January 2004 patient P.T., aged 56, suffered an extensive and complicated anterolateral myocardial infarction with low output syndrome and double ventricular tachycardia interrupted by electrical cardioversion. Emergency coronary angiography and percutaneous coronary intervention of the left anterior descending artery with a result of 100% → 5% and left circumflex with a result of 99% → 0% were performed with simultaneous implantation of stents at the Royal Perth Hospital in Australia. The patient required intubation, intra-aortal counterpulsatio, ECG assessment, blood pressure measurement and invasive haemodynamic monitoring (CI, CO, PAWP, PAP). On the fifth day, in the face of lack of haemodynamic improvement, an additional infusion of levosimendan was added to the infusion of noradrenalin and dobutamine, which resulted in a slight transient improvement in the clinical status of the patient. In view of the unsatisfactory haemodynamic parameters and following a preliminary qualification for cardiac transplant (OHTx), a mechanical device supporting the function of the left ventricle was implanted without complications into the abdominal cavity on the 30<sup>th</sup> day of hospitalisation. On 15<sup>th</sup> April 2005 OHTx was performed with good clinical results. (Folia Cardiol. 2006; 13: 524–529)*

**Key words:** cardiogenic shock, levosimendan, intracorporeal left ventricular assist device, cardiac transplant

## Introduction

Artherosclerosis is the most frequent cause of heart failure in Poland (75% cases) and in Western Europe, Northern America and Australia (50% of cases). The condition leads to myocardial ischaemia [1, 2]. The growing number of patients with heart defects results from the ageing of the population but is also

linked to pharmacotherapeutical development and improvement in the survival of patients undergoing immediate percutaneous coronary intervention (PCI) in the course of acute coronary syndromes. However, some of the patients saved by PCI go on to develop congestive heart failure (CHF).

Cardiogenic shock is a complication of approximately 10% of myocardial infarctions and constitutes a major cause of death in acute coronary syndrome with ST-elevation myocardial infarction (STEMI) [3]. Hospital mortality of patients with STEMI and with fully symptomatic cardiogenic shock is 70–90% and is not significantly reduced with the application of thrombolytic treatment [4]. Gruppo Italiano per lo Studio della Streptochinasi nell'Infarto Miocardico (GISSI) study showed that

Address for correspondence: Lek. Agata Bielecka  
Department of Cardiology and Cardiosurgery No. 1  
Medical University of Łódź  
Sterlinga 1/3, 91–425 Łódź, Poland  
Tel./fax: +48 42 636 44 71; e-mail: agatbiel7@poczta.onet.pl  
Received: 13.02.2006 Accepted: 12.06.2006

mortality among patients with cardiogenic shock receiving intravenous streptokinase reached 70% [5]. The introduction into clinical practice of PCI as a mode of treatment for STEMI patients has enabled a significant improvement in prognosis to be achieved, which has been expressed by a decrease in hospital mortality from 78% to 46% [6]. In some patients, despite mechanical restoration of patency of the artery responsible for the myocardial infarction and restoration of a normal TIMI 3 flow, heavy progressive dysfunction of the left ventricle occurs.

The American Society of Cardiology puts the number of new CHF cases at 400 000 per year [7]. Some of these patients may be saved only through heart transplantation. An extreme form of coronary disease and primary dilated cardiomyopathy are currently the most frequent indications for heart transplant, accounting for 46.1% and 45.3% of cases respectively [8].

We present a description of a patient with STEMI of the anterolateral wall complicated by cardiogenic shock who was hospitalised at the Royal Perth Hospital in Australia in 2004.

### Case description

A 56-year-old Australian male with a positive family history of premature atherosclerosis and who had suffered an inferior myocardial infarction in 1995 was admitted to the Intensive Care Unit of the Royal Perth Hospital on 28<sup>th</sup> January 2004 in the fourth hour of anterolateral STEMI complicated with cardiogenic shock, low output syndrome (LOS) and double ventricular tachycardia interrupted by electrical cardioversion during transfer to hospital. On admission the patient was intubated, after which continuous positive airway pressure (CPAP) had to be applied for three days. In ECG pathological Q waves were noticed in leads II, III and AVF and 3 mm ST elevation in leads V1–V6. Coronarography performed 5 hours after the onset of retrosternal pain revealed occlusion of the proximal left anterior descending artery (LAD) in segment 6 and 99% narrowing of the left circumflex (LCx) in segment 11. PCI of LAD with a Boston Scientific Taxus 3.0/28 mm implantation stent with a result of 100% to 5% (TIMI 2) and PCI of the LCx with a Boston Scientific Taxus 3.0/20.0 mm stent with a result of 99% to 0% were performed simultaneously. The following were administered: aspirin in a preliminary dose of 300 mg and then 150 mg daily, abciximab — bolus 0.25 mg/kg 10 min before the start of intervention followed by an infusion of 0.125  $\mu$ g/kg/min for

12 hours, clopidogrel in a preliminary dose of 300 mg then 75 mg daily and simvastatin at a dose of 40 mg daily. The patient had intra-aortic balloon counterpulsation (IABP) support with 1:1 temporary 2:1 augmentation for the first 12 days of hospitalisation. Heart rate monitoring and blood pressure measurement were required. Haemodynamic parameters such as cardiac output (CO), cardiac index (CI), pulmonary artery wedge pressure (PAWP), and pulmonary artery pressure (PAP) were measured with a Swan-Ganz catheter. Immediately after PCI the following results were obtained: CO amounted to 4.4 l/min, CI: 2.5 l/min/m<sup>2</sup>, PAWP: 22 mm Hg and PAP: 40 mm Hg. Echocardiography revealed extensive anterolateral wall and interventricular septum akinesis. Persistent foramen ovale was excluded. Left ventricular ejection fraction (LVEF) was 16%.

During the first four days of hospitalisation the following were used in medication for LOS: dobutamine at a maximum dose of 10  $\mu$ g/kg/min in association with noradrenalin at a maximum daily dose of 4 mg, furosemide, aldacton, ramipril and digoxin (with the use of serum levels to guide digoxin dosing). As there was no haemodynamic improvement (CO: 4.4 l/min, CI: 2.1 l/min/m<sup>2</sup>, PAWP: 30 mm Hg, PAP: 44 mm Hg), the patient was moved to the Advanced Heart Failure and Cardiac Transplant Service on the fifth day of hospitalisation and here levosimendan was administered at a loading dose of 6  $\mu$ g/kg over 10 minutes and then at an infusion rate of 0.1  $\mu$ g/kg/min. If systolic blood pressure was > 90 mm Hg after 1 hour, the dose was increased to 0.2  $\mu$ g/kg/min until finished. Levosimendan was administered to the full dose of 12.5 mg, which resulted in a transient improvement in clinical status of the patient, expressed in decreased dyspnoea and fatigue. Echocardiography, in contrast, revealed left ventricular failure.

By the 30<sup>th</sup> day of hospitalisation, in view of the unsatisfactory haemodynamic parameters (CO: 4.4 l/min, CI: 2.1 l/min/m<sup>2</sup>, PAWP: 38 mm Hg), the patient qualified for control coronarography, which showed a good result from PCI of LAD and LCx. Indications for heart transplantation (OHTx) were established and immediately after eligibility had been established a mechanical device supporting the function of the left ventricle (LVAD), HeartMate XVE (Thoratec), was implanted without complications into the abdominal cavity, resulting in gradual haemodynamic improvement (CI: 3.17 l/min/m<sup>2</sup>, PAWP: 30 mm Hg, LVEF: 23%). Figure 1 illustrates the HeartMate XVE implantation.



**Figure 1.** Diagram of the HeartMate XVE implantation.

After LVAD implantation the application of  $\beta$ -adrenolytics (carvedilol and next bisoprolol) was possible in the therapy of heart failure. Embolic complications (microembolia to the cerebral arteries) and inflammatory complications (local infection of the post-surgical wound) were observed but these were not life-threatening. Staphylococcus aureus and Citrobacter Koseri were cultured on material taken from the LVAD cannula. In targeted antibiotic therapy vancomicine and ticarcillin with clavulanic acid *i.v.* were used temporarily and flucloxacillin in intracardiac infusion (PICC line) and moxifloxacin 400 mg *per os*.

In the case of the patient described by us LVAD implantation was a bridge to heart transplantation. On 15<sup>th</sup> April 2005, after a period of 13.5 months with LVAD, OHTx was performed. The patient remains in the care of the Cardiac Transplant Service of the Royal Perth Hospital.

## Discussion

Cardiogenic shock is a clinical condition in which the critical decrease of cardiac output caused by damage to the myocardium and disturbances in the autoregulation of the circulatory system cause deep disruption of tissue metabolism, oxygen demand and energy-bearing substrates and impairment of metabolite elimination [9]. The most frequent reason for cardiogenic shock is disturbance of the myocardium structure and function during the acute phase of infarction. On the basis of pathomorphological studies it has been found that the shock develops when contractility irregularity caused by heart infarction or ischaemia cover over 40% of the

left ventricle muscle weight [10]. The most frequently accepted clinical criteria of cardiogenic shock include systolic pressure below 80 mm Hg and symptoms of circulatory hyperperfusion, including cold marble-like skin and hourly diuresis below 20 ml/h. In haemodynamic assessment cardiogenic shock is diagnosed when CI is below 1.8 l/min/m<sup>2</sup>, PAWP is above 20 mm Hg and peripheral resistance is over 25 Wood units [5, 10, 11, 12]. In the majority of Polish hospitals diagnosis of cardiogenic shock and LOS is based on clinical criteria. It should be noted that in the Royal Perth Hospital diagnosis of cardiogenic shock and LOS is based on haemodynamic measurements: CO, CI, PAWP, PAP. Prospects for survival and improvement in cardiogenic shock complicating a massive heart infarction are linked to the temporary application of mechanical circulatory support methods: intra-aortic balloon pump contrapulsation (IABP), percutaneous cardiopulmonary support (PCS) and the System Nimbus Haemopump [13].

PCI with mechanical circulation support using IABP was immediately applied. Because of the persistent LOS the measures were continued for as long as 12 days following the successful coronary intervention. An additional advantage of the treatment applied, along improvement in left ventricular function, was improvement of coronary perfusion and the prevention of early thrombosis in the implanted stent [9]. The application of catecholamine along with IABP was not sufficient to control the LOS symptoms.

In the patient described here, the index event from which remodelling begins was the inferior myocardial infarction in 1995. According to the pathogenesis of cardiac insufficiency, the multiple compensation mechanisms activating the adrenergic nervous system, the renin-angiotensin-aldosterone system and the cytokine system were aimed at fast restoration of the cardiovascular system and were to lead to the asymptomatic clinical course of the first myocardial infarction. Compensation mechanism action was favourable in the short-term. However, chronic activation of the plasmatic and systemic compensation mechanisms led in time to regional and global remodelling of the left ventricle and a subsequent myocardial infarction caused by damage and ischaemia as well as by successive activation of the compensation mechanisms. This resulted in massive damage to the left ventricle and its extension and a drop in LVEF to 16% with an acute clinical manifestation in the form of the cardiogenic shock and subsequent LOS, giving rise to serious circulatory insufficiency [14].

The factor which seems to be of crucial importance in determining the scope of left ventricle remodelling following the myocardial infarction is the patency of the coronary artery responsible for the infarction. In the patient with cardiogenic shock described by us the patency of the LAD responsible for the myocardial infarction was restored in the fifth hour of the infarction with implantation of the anti-mitotic coronary stent. Simultaneously, the critically stenosed LCx responsible for the inferior myocardial infarction nine years previously was dilated with the implantation of the anti-mitotic coronary stent. Despite restoring patency and the stent implantation into two coronary arteries, block of the platelet receptor Gp IIb/IIIa by intravenous abciximab and application of anti-aggregation treatment with clopidogrel combined with aspirin, the patient incurred LOS. In this case the risk factors for progression of disruption of left ventricular function were the anterior localisation of the myocardial infarction, LVEF below 20% and extensive akinesis covering the anteriolateral wall and the interventricular septum.

Despite the restoration of LAD patency, arterial flow was assessed as TIMI 2. Lack of efficient flow in the coronary micro-circulation could be an additional cause of cardiac muscle remodelling [15]. Currently applied pharmacotherapy with angiotensin convertase inhibitors and/or angiotensin II receptor blockers, aldosterone antagonists and  $\beta$ -adrenolytics is associated with a significant reduction in the morbidity and mortality of patients with circulatory insufficiency and acts to stabilise and in some cases to reverse the cardiac remodelling process. Ramipril, aldacton, furosemide and digoxin were applied in the case reported here. No  $\beta$ -adrenolytic drugs were successfully used for treatment of acute cardiac insufficiency.

In some patients cardiac damage still ensues, despite the application of drugs inhibiting the adrenergic system and the renin-angiotensin-aldosterone system. In the Royal Perth Hospital levosimendan was used, a drug which has an inotropic and vasodilative action on the arteries, veins and coronary vessels. Its application leads to a reduction in preload and afterload, an increase in coronary flow and a potential anti-arrhythmic effect as a result of opening ATP-dependent potassium channels [16, 17]. Levosimendan increases the sensitivity of Troponin C to intracellular  $\text{Ca}^{2+}$  ions. Better contractibility of the cardiac muscle cells is obtained by intensification of the releasing factor for the contraction, without changes in the total intercellular  $\text{Ca}^{2+}$  level, with simultaneous reduction of preload and afterload.

Owing to an increase in sensitivity to  $\text{Ca}^{2+}$  ions heart capacity increases, relaxation improves, and this causes potential anti-arrhythmic action and an anti-stunning effect [18]. The lack of persistent improvement in the objective haemodynamic parameters in the 30 days after the myocardial infarction with the maintained patency of both PCI-subjected arteries was a reason for stating indications for OHTx and the decision concerning LVAD implantation.

LVAD implantation is the most obvious example of left ventricle remodelling reversal and is expressed in an increase in wall thickness and a decrease in left ventricle volume [19]. A study by Dipla et al. [20] on the possibility of a potential reversal of myocyte contractile defects by LVAD support showed improvement of their contractility and decontractility compared to the defective myocytes isolated from LVAD-unsupported hearts. A recently published study by Mueller et al. [21] showed that in 24% of mechanically supported patients sufficient left ventricular function may be restored to allow the LVAD to be disconnected. In the patient described here CO before LVAD implantation was 4.5 l/min, CI: 2.1 l/min/m<sup>2</sup>, PAWP: 30 mm Hg, systolic pressure: 90 mm Hg, LVEF: 16%. Thus the decision on LVAD implantation as a bridge to OHTx was in this case based mainly on the clinical image of the pharmacotherapy-resistant LOS, haemodynamic criteria being treated as secondary.

HeartMate XVE, was used as a device for mechanical support of the left ventricle and may be used both as a bridge for transplantation and as a final therapy. In this device the inflow cannula is fixed in the apex of the left ventricle and the outflow cannula is connected to the aorta. Blood from the left ventricle flows into the device and is pumped into the aorta. A small electrical engine serves as a pump. Because of the special construction of the device embolic and thrombotic incidents may, very rarely, follow its implantation. As a result patients do not require systemic anticoagulation [22]. Inflammatory complications (described in 30 ± 50% of the total cases following HeartMate XVE implantation) and embolic complications (rarely reported) that were not life-threatening occurred in the patient described here. Fast intervention with targeted antibiotic therapy and the introduction of anti-thrombosis treatment were possible owing to the excellent co-operation between the patient and his family and the medical team of the Advanced Heart Failure and Cardiac Transplant Service. Staphylococcus aureus MRSA and Citrobacter Koseri were cultured from the LVAD cannula. The antibiotic treatment included intravenous vancomycin and

ticarcillin with clavulanic acid, intracardiac infusion of flucloxacillin (through the PICC line, and oral moxifloxacin 400 mg.

No post-surgery bleeding (which constitutes a complication in approximately 50% of cases) was observed in this patient, nor was there any development of right ventricle insufficiency (observed in  $20 \pm 30\%$  of cases following LVAD implantation). However, microembolism into the central nervous system occurred, which is rarely reported in this group of patients. It should be noted that the warfarin applied as anti-thrombosis treatment did not cause the bleeding that frequently occurs in these patients. The device itself does not require a prolonged application of oral anticoagulants. At present patients with the implanted internal devices, HeartMate or Novacor, may live outside hospitals in their own homes awaiting heart transplant. In many cases they can participate in social life, which increases their quality of life greatly [2]. Because of the limited number of donors and the long wait for a heart transplant, ventricle supporting devices have begun to play an increasing role in heart insufficiency therapy, both as a bridge to OHTx and as a final solution to decadent heart insufficiency. They save the lives of patients whose condition is not improved or stabilised by intravenous inotropic vasodilative drugs, IABP support or mechanical ventilation. The results of randomised assessment of mechanical support in the treatment of dilated cardiomyopathy (REMATCH) [23] suggest an improvement in survival during the follow-up period of over two years. In the case of the patient described by us the device implantation resulted in gradual haemodynamic improvement (CI:  $3.17 \text{ l/min/m}^2$ , PAWP: 30 mm Hg), which was also expressed by good tolerance towards  $\beta$ -blockers (carvedilol, bisoprolol). This enabled the patient to tolerate the waiting period of 13.5 months for the OHTx, which was finally performed on 15<sup>th</sup> April 2005. While waiting for the heart transplant the patient was able to lead an active life (Fig. 2).

### Conclusions

1. Full coronary revascularisation with PCI method in extensive complicated myocardial infarction further complicated by cardiogenic shock does not always improve the haemodynamic status of the patient in a satisfactory way, despite the application of pharmacotherapy and IABP.
2. Levosimendan is a new inotropically positive drug to be transiently applied in acute heart failure during myocardial infarction.

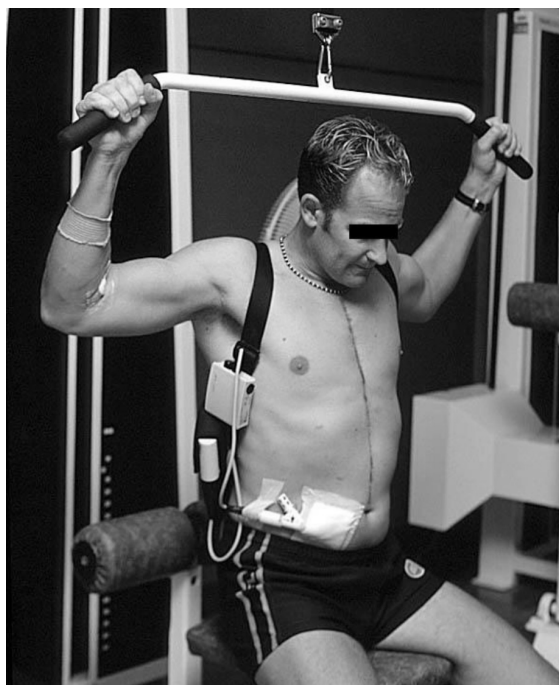


Figure 2. Patient P.T. with LVAD during physical exercise.

3. Devices for internal mechanical support of heart ventricles enable OHTx waiting time to be extended while allowing the patient to maintain an active lifestyle.

### References

1. Cleland JGF, Khand A, Clark AC. The heart failure epidemic: exactly how big is it? *Eur Heart J*, 2001; 22: 623–626.
2. Hunt SA, Frazier OH. Mechanical circulatory support and cardiac transplantation. *Circulation*, 1998; 97: 2079–2090.
3. Hands ME, Rutherford JD, Muller JE et al. The in-hospital development of cardiogenic shock after acute myocardial infarction: incidence, predictors of occurrence, outcome and prognostic factors. *J Am Coll Cardiol*, 1989; 14: 40–46.
4. Gruppo Italiano per lo Studio della Streptochinasi nell'Infarto Miocardico (GISSI). Effectiveness of intravenous thrombolytic treatment in acute myocardial infarction. *Lancet* 1986; 1: 397–402.
5. Emmerich K, Ulbricht LJ. Cardiogenic shock in acute myocardial infarction. Improving survival rates by primary coronary angioplasty. *Z Kardiol*, 1995; 1: 225–242.
6. Sanborn TA, Sleeper LA, Bates ER et al. Impact of thrombolysis, intra-aortic balloon pump counterpulsation, and their combination in cardiogenic shock

- complicating acute myocardial infarction: a report from the SHOCK Trial Registry. Should we emergently revascularize occluded coronaries for cardiogenic shock? *J Am Coll Cardiol*, 2000; 36: 1123–1129.
7. American Heart Association. Heart and Stroke Facts: Statistical Supplement. Dallas, Tex: American Heart Association. *Circulation*, 1998; 98: I1–1016.
  8. Przybyłowski P, Wierzbicki K, Sadowisk J et al. Przeszczepianie serca. *Terapia*, 2003; 3: 134.
  9. Bieńkowska M. Współczesne metody leczenia wstrząsu wywołanego świeżym zawałem serca. *Medipress. Kardiologia*, 2000; 4: 25–30.
  10. Eltchaninoff H, Simpfordorfer C. Early and 1-year survival rates in acute myocardial infarction complicated by cardiogenic shock retrospective study comparing coronary angioplasty with medical treatment. *Am Heart J*, 1995; 9: 459–464.
  11. Gaszyński W, Przygoda M. Współczesne poglądy na patogenezę wstrząsu kardiogenego. *Atest Inten Ter*, 1991; 23: 130–137.
  12. Mueller HS. Role of Intra-aortic counterpulsation in cardiogenic shock and acute myocardial infarction. *Cardiology*, 1994; 84: 168–174.
  13. Zembala M, Religia Z. Wstrząs kardiogeny. Chirurgicalna reperfuzja mięśnia sercowego. *Kardiol Pol*, 1991; 11: 284–291.
  14. Mann DL, Bristow MR. Mechanisms and models in heart failure: the biomechanical model and beyond. *Circulation*, 2005; 111: 2837–2849.
  15. Ito H, Maruyama A, Iwakura K et al. Clinical implication of the “no-reflow” phenomenon: a predictor of complication and left ventricular remodeling in reperfused anterior wall myocardial infarction. *Circulation*, 1996; 93: 223–228.
  16. Kaheinen P, Pollesello P, Levijoki J, Haikala H. Levosimendan increases diastolic coronary flow in isolated guinea-pig heart by opening ATP-sensitive potassium channels. *J Cardiovasc Pharmacol*, 2001; 37: 367–374.
  17. Lilleberg J, Niemenen MS, Akkila J et al. Effects of a new calcium sensitiser, levosimendan, on haemodynamics, coronary blood flow and myocardial substrate utilization early after coronary artery bypass grafting. *Eur Heart J*, 1998; 19: 660–668.
  18. Hasenfuss G, Pieske B, Castell M, Kretschmann B, Maier LS, Just H. Influence of the novel inotropic agent levosimendan on isometric tension and calcium cycling in failing human myocardium. *Circulation*, 1998; 98: 2141–2147.
  19. McCarthy PM, Nakatani S, Vargo R et al. Structural and left ventricular histologic changes after implantable LVAD insertion. *Ann Thorac Surg*, 1995; 59: 609–613.
  20. Dipla K, Mattiello JA, Jeevanandam V et al. Myocyte recovery after mechanical circulatory support in humans with end-stage heart failure. *Circulation*, 1998; 97: 2316–2322.
  21. Mueller J, Wallukat G, Weng YG et al. Weaning from mechanical cardiac support in patients with idiopathic dilated cardiomyopathy. *Circulation*, 1997; 96: 542–549.
  22. Cooley DA, Liotta D, Hallman GL, Bloodwell RD, Leachman RD, Milam JD. Orthotopic cardiac prothesis for two-staged cardiac replacement. *Am J Cardiol*, 1969; 24: 723–730.
  23. Stevenson LW, Miller LW, Desvigne-Nickens P et al, for the REMATCH Investigators Left Ventricular Assist Device as Destination for Patients Undergoing Intravenous Inotropic Therapy: a A Subset Analysis From REMATCH (Randomized Evaluation of Mechanical Assistance in Treatment of Chronic Heart Failure). *Circulation*, 2004; 110: 975–981.