

Electrocardiographic diagnosis of acute coronary syndromes in patients with left bundle branch block or paced rhythm

Artur Klimczak¹, Jerzy K. Wranicz¹, Iwona Cygankiewicz¹,
Michał Chudzik¹, Jan H. Goch¹ and Rafał Baranowski²

¹Department of Cardiology, Medical University of Łódź, Poland

²Department of Cardiac Rehabilitation and Noninvasive Electrocardiology,
Institute of Cardiology, Warsaw, Poland

Abstract

The population of patients with a pacemaker is constantly growing in number. Myocardial infarction in these patients, like in patients with left bundle branch block (LBBB), is called the undetermined type and characterizes the highest risk of death. Therefore the early and correct diagnosis of AMI is very important. The electrocardiographic criteria of the recognition of acute myocardial infarction (AMI) in patients with a ventricular pacing are similar to the electrocardiographic criteria of the recognition of AMI in patients with LBBB. They are applicable in the first phase of AMI's diagnostic process and they are known as Sgarbossa's criteria. However, one should remember about differences between these two groups of patients and therefore particular criteria have got different significance in patients from each group.

There are three Sgarbossa's criteria: ST-segment elevation of ≥ 5 mm in the presence of a negative QRS complex, ST-segment elevation of ≥ 1 mm in the presence of a positive QRS complex and ST-segment depression of ≥ 1 mm in lead V1, V2 or V3. In spite of all limitations of use ECG records in the recognition of AMI in patients with a ventricular pacing it should be remembered, that this method (together with a typical medical history) is still the simplest, the cheapest and the most available means of an early diagnosis of AMI. In patients with chest pain, the presence of a pacemaker should not defer the execution of ECG recording because ECG may be very helpful in establishing of the diagnosis. (Cardiol J 2007; 14: 207–213)

Key words: acute coronary syndrome, pacing, left bundle branch block, electrocardiogram

Introduction

Common clinical feature of acute myocardial infarction (AMI) regardless of its cause is characteristic chest pain [1], manifestation of which starts

the diagnostic process. One of the first steps in this process is standard 12-lead electrocardiogram (ECG), which is cheap and highly specific and sensitive. Therefore it is commonly used for recognition and diagnosis of AMI. However in patients with implanted pacemaker or with left bundle branch block (LBBB), the recognition of AMI on the basis of ECG is difficult and standard criteria can not be used in these patients [2].

The aim of this study was presentation of ECG criteria that can be helpful in recognition of AMI in patients with a pacemaker or LBBB.

Address for correspondence: Jerzy K. Wranicz, MD, PhD
Department of Cardiology, Medical University of Łódź
Sterlinga 1/3, 91–425 Łódź, Poland
Tel./fax: +48 42 636 44 71, e-mail: holter@csk.umed.lodz.pl

The undetermined type of acute myocardial infarction

QRS complex in ECG has got similar morphology in presence of ventricular pacing as well as LBBB, because pathway of ventricular depolarization runs similarly in these two cases. AMI in patients with ventricular pacing or LBBB is called the undetermined type. This type is recognized in 6.5% patients with AMI and intrahospital mortality of these patients is 11.8% [3]. Patients with the undetermined type of AMI make up a group with the highest risk of death because they have statistically the most extensive coronary disease and numerous comorbidities [3]. Clinical characteristic of that group of patients is shown in Table 1. The number of patients with the implanted pacemaker is rising and therefore the accurate and fast diagnosis of AMI, which is essential to right therapy, is very important.




The acute myocardial infarction in patients with left bundle branch block

The recognition of AMI on the basis of ECG in patients with LBBB (contrary to patients without disturbances in intraventricular conduction or with right bundle branch block) is very difficult and sometimes even impossible. Electrocardiographic algorithms which are used to recognition of AMI, are useless in patients with LBBB [5]. In these patients there is a change in repolarization whose direction in ECG is discordant with QRS complex. As a result, it comes to ST-segment elevation in leads with presence of a negative QRS complex and ST-segment depression in leads with presence of positive QRS complex. It mimics myocardial injury as a result of a occlusion of a coronary artery. In case of occlusion of a coronary artery in patients with LBBB changes in ECG record can be observed, which is

Table 1. Clinical profile of patients with the undetermined type of acute myocardial infarction. Adapted from: Karpiński et al. [4].

Advanced age
Frequent history of heart diseases and revascularization
Diabetes mellitus
Arterial hypertension
Chronic kidney disease
Chronic lung diseases
Chronic diseases of peripheral circulation

Table 2. Sgarbossa’s criteria for diagnosis of the acute myocardial infarction in patients with left bundle branch block [8].

	↑ST of ≥ 5 mm in the presence of a negative QRS complex
	↑ST of ≥ 1 mm in the presence of a positive QRS complex
	↓ST of ≥ 1 mm in lead V1, V2 or V3

↑ST — ST-segment elevation, ↓ST — ST-segment depression

expressed in the form of more intensive ST-segment elevation in relation to standard image [6, 7].

The above-mentioned dissimilarities in ECG in patients with LBBB in relation to patients without conduction disturbances cause the necessity of using special criteria to recognize AMI in those patients. In 1996 the criteria of AMI recognition in patients with LBBB were put forward [8]. They were known as Sgarbossa’s criteria but acquaintance of these rules among physicians seems to be far insufficient. There are three Sgarbossa’s criteria:

- ST-segment elevation of ≥ 5 mm in the presence of a negative QRS complex;
- ST-segment elevation of ≥ 1 mm in the presence of a positive QRS complex;
- ST-segment depression of ≥ 1 mm in lead V1, V2 or V3.

Table 2 shows AMI recognition’s criteria in LBBB by Sgarbossa [8]. Figures 1 and 2 show ECG samples of AMI in patients with LBBB.

The above-mentioned criteria were established on the basis of the analysis of a group of patients from GUSTO trial [9]. Two strategies of thrombolytic therapy were analyzed in 26 000 of patients with AMI. In 131 of them LBBB was observed in ECG and the changes, which were in relationship with the appearance of AMI, became Sgarbossa’s criteria.

Sgarbossa’s criteria (known also as GUSTO criteria) usually allow to recognize AMI but localization of infarction is still difficult or even impossible [10].

The limitations of Sgarbossa’s criteria should be kept in mind, especially the criterion of ST-segment elevation of 5 mm. This criterion is often fulfilled (usually in patients with high voltage of QRS complexes due to the hypertrophy of left ventricle) but sometimes we can see ST-segment elevation of ≤ 5 mm, but then shape of changes in ST-segment indicates the presence of AMI. It’s about ST-segment uphill convex elevation, like on the Figure 3.

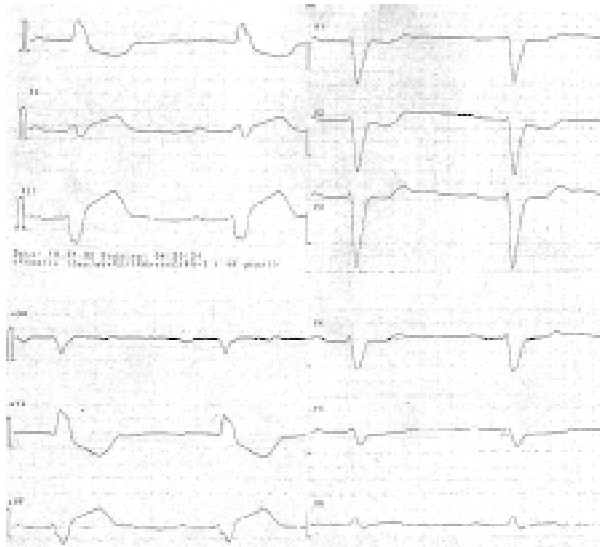


Figure 1. Electrocardiogram of a patient with acute myocardial infarction and left bundle branch block (LBBB). Sinus rhythm: 55 bpm. Pathological left axis deviation, atrio-ventricular block II° 2:1. QRS complex with morphology of LBBB. Suspicion of the acute myocardial infarction on the basis of presence of the Sgarbossa's criteria: ST-segment depression in lead V1, V2 and V3, ST-segment elevation in lead III and aVF of only 5 mm (limit value, measurement in J point) but nature of elevation suggests acute myocardial infarction. ST-segment elevation of 5 mm in lead II. There is also positive T-wave in lead V6 (positive QRS complex) and presence of S-wave in this lead. In lead V6 in LBBB we shouldn't see T-wave — it's presence suggests the old myocardial infarction, S-wave is an equivalent of Q-wave.

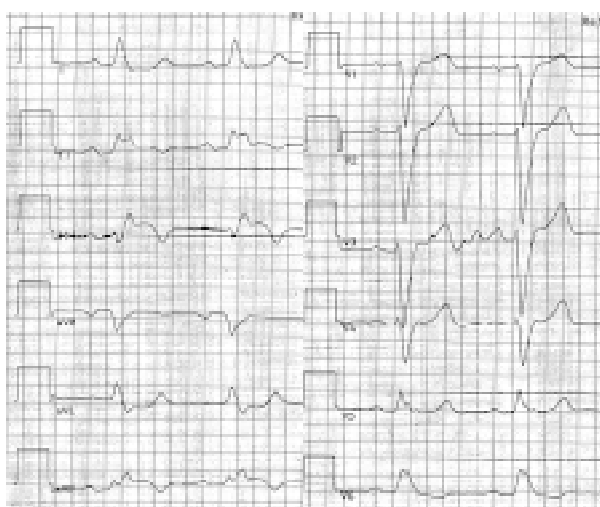


Figure 2. The acute myocardial infarction of inferior wall in a patient with left bundle branch block. ST-segment elevation in lead II, III and aVF in the presence of a positive QRS complex. Positive T-wave in lead V5.

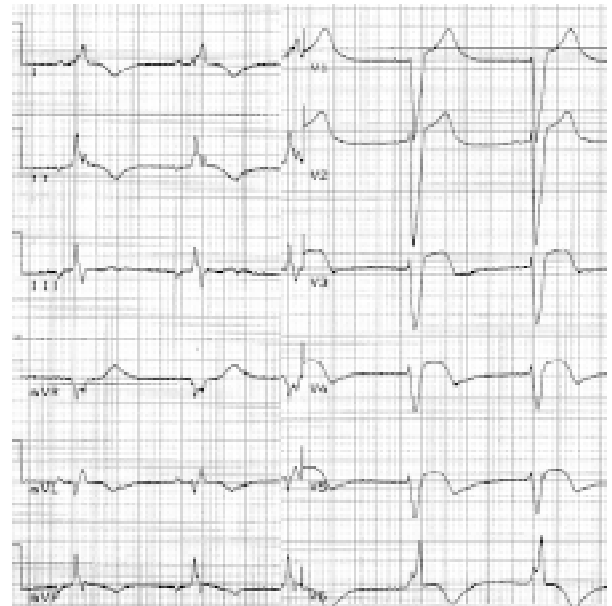


Figure 3. Electrocardiogram of a patient with left bundle branch block (LBBB) and acute myocardial infarction. Inferoatrial rhythm. ST-segment elevation in lead V1, V2 with LBBB morphology. In lead V3, V4 and V5 ST-segment elevation is of ≤ 5 mm, but its shape isn't typical for LBBB — uphill convex. Changes in ST-segment atypical for LBBB are always seen in lead V6, I and aVL — long isoelectric phase before T-wave; ST-segment in LBBB usually starts lowering at J point.

The acute myocardial infarction in patients with a pacemaker

The electrocardiographic diagnosis of AMI in patients with paced rhythm is difficult. Acute myocardial injury can be masked in ECG by the presence of paced QRS complexes. In paced rhythm, like in LBBB, activation of left ventricle is delayed in comparison with right ventricle. The pacemaker can be temporarily reprogrammed, so as to avoid imposition of its paced rhythm but it requires specialistic equipment and therefore it's not possible in every hospital. Furthermore, temporary switching off the pacing can be dangerous and sometimes even impossible in case of complete atrio-ventricular block. It's also important to take notice of so called T-wave memory phenomenon, known as electrical heart memory, which makes T-wave analysis difficult, even after pacing is terminated [11]. However not all the repolarization changes can be qualified as a result of "electrical memory" (Fig. 4).

The recognition of AMI on the basis of ECG in patients with implanted pacemaker depends on the pacing mode and the presence of the intrinsic QRS-complexes.

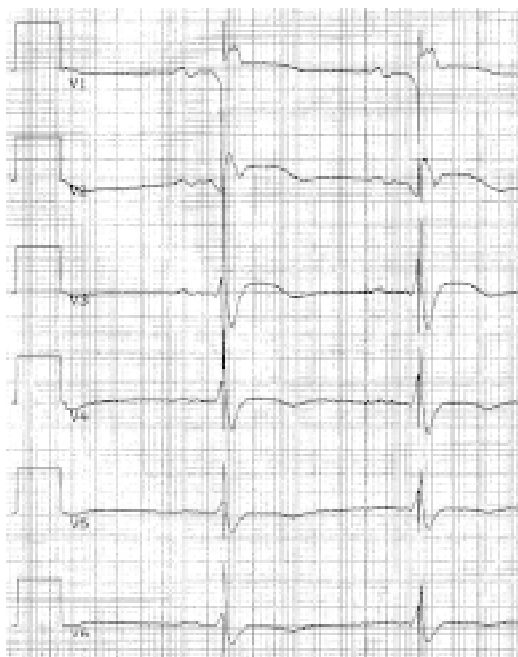


Figure 4. The acute myocardial infarction in patients with DDD pacing. Sinus rhythm. Impulses of a ventricular pacing hit in QRS complexes — sensing disturbances in acute myocardial infarction period. ST-segment elevation in the lead V1, V2 and V3 can't be explained as an electrical memory phenomenon.

Atrial pacing

In patients with atrial pacing (AAI) AMI recognition criteria are similar with standard criteria for patients without implanted pacemaker, because in AAI mode ventricles are stimulated via the physiologic conduction system. The exemplary ECG of AMI in patients with a pacemaker in AAI mode is shown in Figure 5.

Ventricular pacing

There are two possibilities in patients with pacing in VVI mode (ventricular pacing, ventricular sensing), VDD mode (ventricular pacing, atrial and ventricular sensing), and DDD mode (atrial and ventricular pacing, atrial and ventricular sensing), namely: the presence of a sinus rhythm or the presence of a paced rhythm.

If a physiologic ventricle depolarization is visible in ECG recording, the standard AMI recognition criteria are in force. On the other hand, in case of a paced rhythm we can use Sgarbossa's criteria (which are shown in Table 2) [8].

The exemplary ECG of AMI in patients with ventricular pacing is shown in Figure 6.

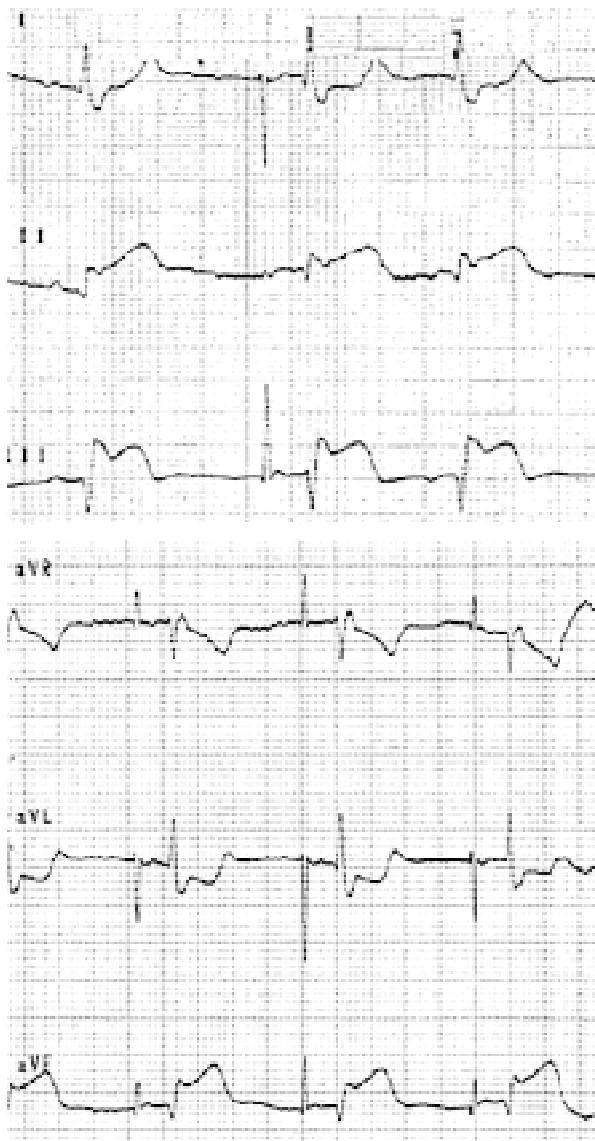

Figure 5. Myocardial infarction in a patients with an atrial pacing (AAI). Paced rhythm in an atrial pacing mode (AAI), Spikes precede stimulated P-waves. Further conduction tract takes place in a physiologic pathway, so the pacemaker doesn't influence on morphology of QRS-complexes. ST-segment elevation in lead II, III and aVF and ST-segment depression in lead aVL. The above example suggests the recognition of acute myocardial infarction of inferior wall.

The above-mentioned criteria are the same as the criteria of a recognition of AMI in patients with LBBB.

Although the Sgarbossa's criteria in patients with LBBB and in patients with ventricular pacing are convergent, the criteria present a different diagnostic value in the two clinical settings.

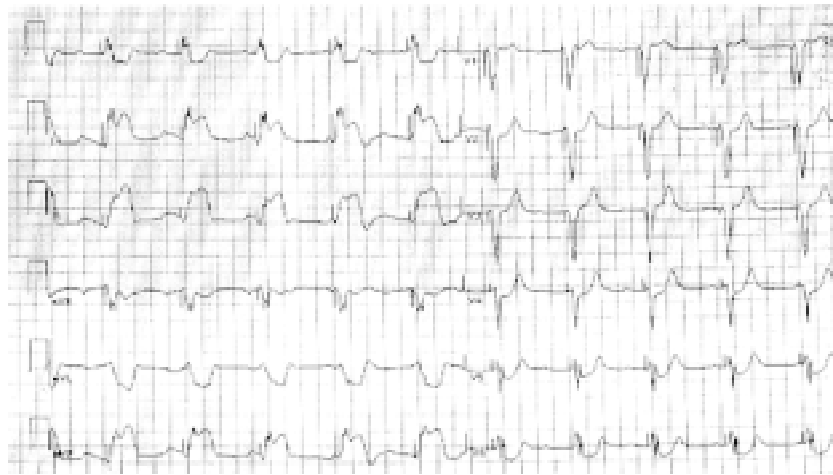

Figure 6. Acute myocardial infarction in patient with a ventricular pacing (VVI). The paced rhythm in a ventricular pacing mode (VVI): 66 bpm. The basic rhythm (“under the pacemaker”) is a sinus rhythm, about 100 bpm with an advanced or complete atrio-ventricular block. According to the Sgarbossa’s criteria ST-elevation in the lead II, III and aVF suggests the recognition of acute myocardial infarction, probably of inferior wall.

Among three Sgarbossa’s criteria, the highest diagnostic value in a recognition of AMI in patients with LBBB, is attributed to ST-segment elevation of ≥ 1 mm in the presence of a positive QRS complex while ST-segment elevation of ≥ 5 mm in the presence of a negative QRS complex is of the lowest value [9]. The diagnostic value of the above-mentioned criteria in a recognition of AMI in patients with LBBB are shown in Figure 7. The diagnostic value of the Sgarbossa’s criteria in patients with LBBB is the highest (and the probability of AMI reaches 100%), when, apart from a typical chest pain, three of them are fulfilled.

In patients with a pacemaker it is different. In GUSTO trial, ECGs of 17 patients (which were selected from 26,003 patients with AMI) with a pacemaker were analyzed and it was stated that the only one of Sgarbossa’s criteria was relatively highly sensitive and statistically significant: ST-segment elevation of ≥ 5 mm in the presence of a negative QRS complex [12]. Additionally it was observed, that any ST-segment elevation in leads in the presence of a positive QRS-complexes and ST-segment depression in lead V1, V2 and V3 were characterised by high sensitivity in diagnostic of myocardial infarction (Table 3).

In the electrocardiographic evaluation of AMI in patients with ventricular pacing, as well as in patients with LBBB, the precise localization of infarction site is difficult. ST-segment depression of ≥ 1 mm in lead V1, V2 or V3 does not allow to predict the localization of AMI. The pacing site also influences the morphology of QRS-complexes, which can be seen on ECG recording. The electrode

can be placed in a right ventricular apex (RVA), right ventricular outflow tract or in left ventricle through coronary sinus. In each of these cases the electrocardiographic record of ventricular depolarization is different and therefore the evaluation of ischemic changes in the myocardium may be problematic. It seems, that Sgarbossa’s criteria can be applied mainly in RVA pacing because in this case QRS morphology on ECG-recording is the most similar to LBBB. Thus, above-mentioned Sgarbossa’s criteria of the recognition of AMI lose their value in patients with a pacemaker and an electrode implanted in position other than RVA.

Nowadays, it is said, that the RVA pacing should be avoided, because it can cause the series of the unfavourable haemodynamic consequences and remodeling of the heart, which eventually leads to development of heart failure [13, 14]. As a result of that, the percentage of RVA pacing (for the advantage of alternative pacing sites) will decrease in the near future, and the present criteria of AMI recognition will lose their significance.

It should be underlined, that Sgarbossa’s criteria, which compose the electrocardiographic guidelines for the diagnosis of AMI in patients with ventricular pacing, were developed on the basis of the analysis of only 17 patients selected from GUSTO trial.

In clinical practice in patients with LBBB, Sgarbossa’s criteria appear relatively rare occurrence, low sensitivity and significant difference of opinions among many observers [15]. Therefore, it seems, that standard Sgarbossa’s criteria should additionally take into consideration the amplitude of

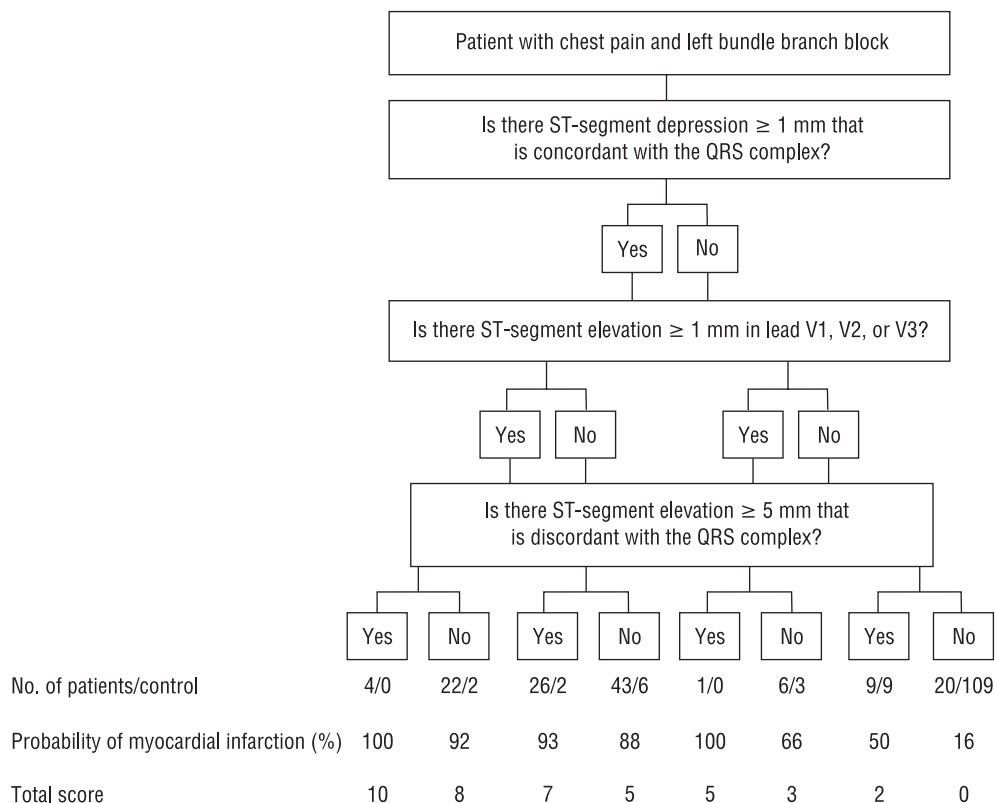


Figure 7. The diagnostic value of the Scarbossa’s criteria in a diagnosis of acute myocardial infarction and left bundle branch block. Flow chart for the prediction of acute myocardial infarction in the presence of left bundle-branch block, with the use of all possible combinations of the three independent electrocardiographic criteria. The discriminatory power of each combination of criteria for the diagnosis of acute myocardial infarction is indicated by the total score at the bottom, with higher scores indicating better discriminatory power. Adapted from: Sgarbossa et al. [9].

Table 3. Sensitivity and specificity of each criteria for the diagnosis of acute myocardial infarction in patients with ventricular pacing. Adapted from: Sgarbossa et al. [12].

Criterion	Sensitivity (%)	Specificity (%)	p value
↑ST of ≥ 1 mm in the presence of a positive QRS complex	18	94	NS
↑ST of ≥ 5 mm in the presence of a negative QRS complex	53	88	0.025
↓ST of ≥ 1 mm in lead V1, V2 or V3	29	82	NS

↑ST — ST-segment elevation, ↓ST — ST-segment depression

QRS-complexes, so that the degree of ST-segment elevation would relate to the amplitude of QRS-complex [4].

The recognition of AMI, according to the contemporary definition, requires measurement of biochemical enzymes (CK-MB and/or troponin). Hence ECG recording and typical clinical symptoms enable only the preliminary diagnosis of AMI [16].

Conclusion

Myocardial infarction in patients with a pacemaker, like in patients with LBBB, is called the undetermined type and is characterized by the highest risk of death. Therefore the early and correct diagnosis of AMI is very important. The electrocardiographic criteria of the recognition of AMI in

patients with ventricular pacing are similar to the electrocardiographic criteria of the recognition of AMI in patients with LBBB and they are applicable in the first phase of AMI's diagnostic process. However, one should remember about differences between these two groups of patients and therefore particular criteria have got different significance in patients from each groups.

It seems that present criteria of the recognition of AMI in patients with pacemaker have got serious limitations and we need further, prospective studies that include larger population of patients with new methods of pacing and alternative localizations of electrodes. In spite of all limitations of use ECG recordings in the recognition of AMI in patients with a ventricular pacing it should be remembered, that this method (together with a typical medical history) is still the simplest, the cheapest and the most available form of an early diagnosis of AMI. In patients with chest pain, the presence of a pacemaker can not defer the execution of ECG recording because ECG may be very helpful in establishing the diagnosis.

References

1. Budaj A, Beręsewicz A, Undas A et al. Choroba niedokrwienne serca. In: Szczeklik A ed. Choroby wewnętrzne. Medycyna Praktyczna, Kraków 2005: 137–181.
2. Schweitzer P. The electrocardiographic diagnosis of acute myocardial infarction in the thrombolytic era. *Am Heart J*, 1990; 119: 642–654.
3. Hasdai D, Behar S, Wallentin L et al. A prospective survey of the characteristics, treatments and outcomes of patients with acute coronary syndromes in Europe and the Mediterranean basin; the Euro Heart Survey of Acute Coronary Syndromes (Euro Heart Survey ACS). *Eur Heart J*, 2002; 23: 1190–1201.
4. Ostry zespół wieńcowy u pacjentów z blokiem lewej odnogi pęczka Hisa i stałą stymulacją serca. In: Karpiński G, Grabowski M, Filipiak KJ, Opolski G eds. Ostre zespoły wieńcowe. Atlas elektrokardiograficzny. Urban & Partner, Wrocław 2004: 173–207.
5. Rude RE, Poole WK, Muller JE et al. Electrocardiographic and clinical criteria for recognition of acute myocardial infarction based on analysis of 3,697 patients. *Am J Cardiol*, 1983; 52: 936–942.
6. Stark KS, Krucoff MW, Schryver B, Kent KM. Quantification of ST-segment changes during coronary angioplasty in patients with left bundle branch block. *Am J Cardiol*, 1991; 67: 1219–1222.
7. Sclarovsky S, Sagie A, Strasberg B et al. Ischemic blocks during early phase of anterior myocardial infarction: correlation with ST-segment shift. *Clin Cardiol*, 1988; 11: 757–762.
8. Sgarbossa EB, Pinski SL, Gates KB et al. Early electrocardiographic diagnosis of acute myocardial infarction in the presence of ventricular paced rhythm. *Am J Cardiol*, 1996; 77: 423–424.
9. Sgarbossa EB, Pinski SL, Barbagelata A et al.; for the GUSTO-1 investigators: Electrocardiographic diagnosis of evolving acute myocardial infarction in the presence of left bundle-branch block. *N Engl J Med*, 1996; 334: 481–487.
10. Kogiadakis GE, Kaleboubas MD, Igoumenidis NE et al. Electrocardiographic diagnosis of acute myocardial infarction in the presence of ventricular paced rhythm. *PACE*. 2001; 24: 1289–1290.
11. Kolb James C. Cardiac memory: Persistent T wave changes after ventricular pacing. *J Emerg Med*, 2002; 23: 191–197.
12. Sgarbossa EB. Recent advances in the electrocardiographic diagnosis of myocardial infarction: left bundle branch block and pacing. *PACE*, 1996; 19: 1370–1379.
13. Wilkoff BL. Dual-chamber pacing or ventricular back-up pacing in patients with an implantable defibrillator: the Dual Chamber and VVI Implantable Defibrillator (DAVID) Trial. *JAMA*, 2002; 288: 3115–3123.
14. Kutarski A. Right ventricular apical pacing sequelae: Time for conclusions? *Folia Cardiol*, 2005; 12: 613–627.
15. Gula LJ, Dick A, Massel D. Diagnosing acute myocardial infarction in the setting of left bundle branch block: prevalence and observer variability from a large community study. *Cor Artery Dis*, 2003; 14: 387–393.
16. Opolski G, Filipiak KJ. Ostre zespoły wieńcowe: definicja i klasyfikacja. In: Opolski G ed. Ostre zespoły wieńcowe. Urban & Partner, Wrocław 2002: 1–6.