

# Acute aortic dissection imitating ST elevation myocardial infarction with accompanying pulmonary embolism

Kazimierz Radwan<sup>1,2</sup>, Ewa Peszek-Przybyła<sup>1,2</sup>, Agata Gruszka<sup>1</sup>,  
Maciej Sosnowski<sup>2,3</sup> and Paweł Buszman<sup>1,3</sup>

<sup>1</sup>Silesian Medical Centre Coronary Care Unit, Katowice, Poland

<sup>2</sup>Silesian Medical Centre Department of Noninvasive Cardiovascular Diagnostics, Katowice, Poland

<sup>3</sup>3<sup>rd</sup> Division of Cardiology, Silesian Medical Centre, Katowice, Poland

Acute aortic dissection is an uncommon disease with a high mortality rate, and its proper diagnosis remains essential for further treatment.

A female, aged 66, with a history of hypertension, hyperthyroidism and arthritis at a young age, with no preceding complaints was admitted to the acute coronary syndrome (ACS) Unit because of transitory mild chest pain with initial diagnosis of ST elevation myocardial infarction.

Physical examination revealed low arterial blood pressure (90/60 mm Hg). Laboratory examinations performed on admission to the hospital showed mild leucocytosis ( $12.6 \times 10^3/\text{mm}^3$ ) and an elevated level of D-dimers (6403 ng/mL). Cardiac markers were within normal levels. A 12-lead ECG showed normal axis, ST segment elevation in III, aVF leads up to 2 mm and negative T waves in leads V1–V3.

Transthoracic echocardiography revealed moderate right ventricle enlargement and hypokinesis of the basal segment of the inferior wall.

Emergency coronary angiography did not show any coronary artery lesions.

A chest multi-slice computed tomography (MSCT) revealed dilated pulmonary trunk, small

thrombi in the tiny pulmonary artery branches and aortic dissection spreading from the coronary sinus to the abdominal aorta. The true lumen diameter of the ascending aorta was 10 mm. Transverse diameter of the ascending aorta was 42 mm and of the descending aorta was 32 mm.

The patient subsequently experienced cardiac arrest caused by asystole. After short resuscitation, recovery of sinus rhythm was achieved. Transthoracic echocardiography showed over 2 cm of pericardial fluid and tamponade features, caused by rupture of the aneurysm into the pericardium.

The patient was qualified for life-saving cardiac surgery. Using cardio-pulmonary bypass, the aneurysm was removed. The patient was reoperated because of features of chest bleeding.

One month after the operation, transthoracic echocardiography showed normal ventricular function, and the patient felt well.

The correct diagnosis was made in this case on the basis of MSCT of the chest. In the case of chest pain with no coronary artery lesions, MSCT may be a valuable clinical tool.

---

Address for correspondence:

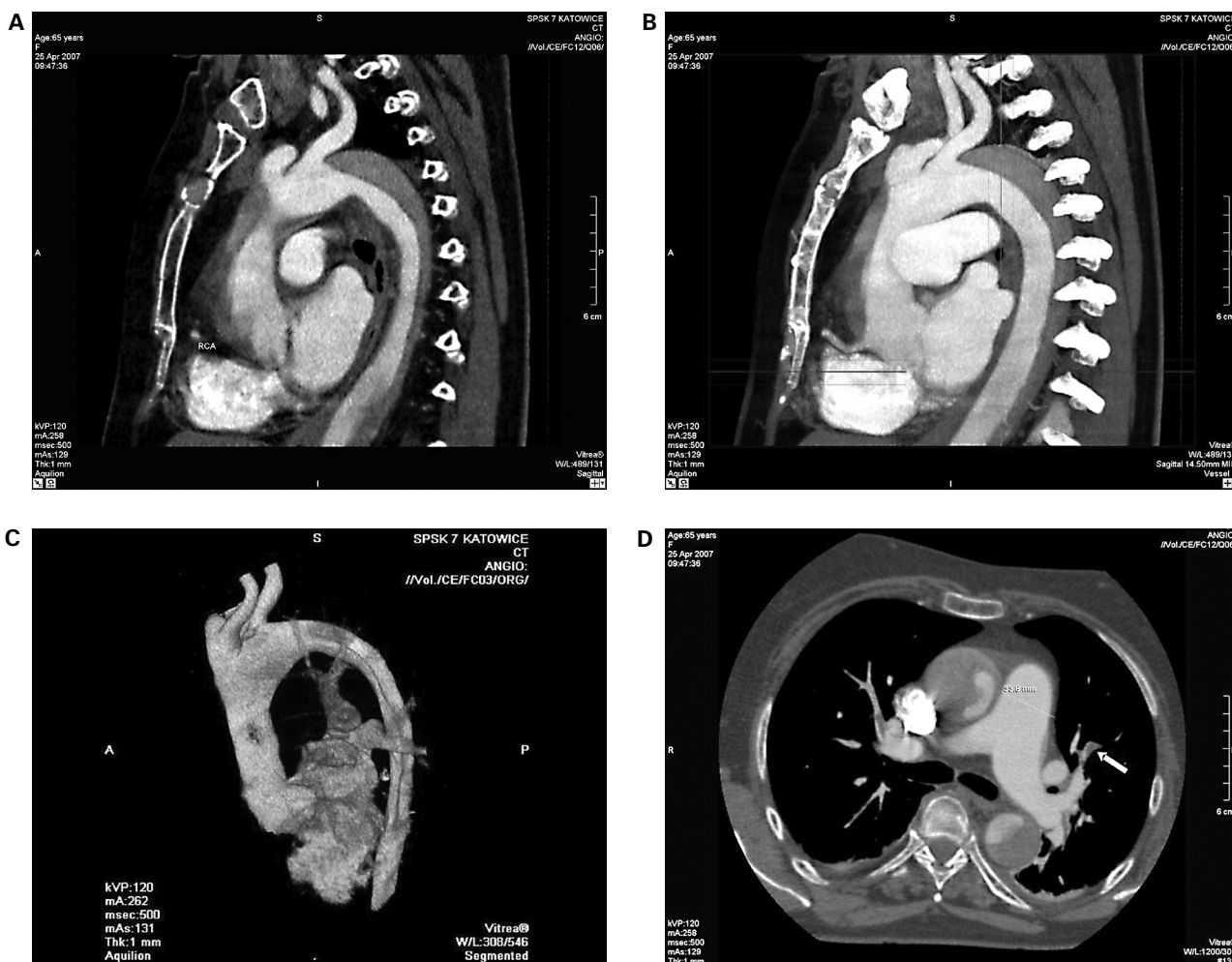
Dr. Kazimierz Radwan

Silesian Medical Centre

Department of Noninvasive Cardiovascular Diagnostics

Ziołowa 47, 40–635 Katowice, Poland

e-mail: kradwan@neostrada.pl



**Figure 1.** Acute aortic dissection imitating ST elevation myocardial infarction with accompanying pulmonary embolism. **A, B, C.** Aortic dissection type I according to DeBakey classification (consistent with type A according to Stanford). The dissection includes: ascending aorta, aortic arch and descending aorta. **A.** Multiplanar reformation (MPR) of longitudinal section with visible ascending aorta, aortic arch and thoracic part of descending aorta. Right coronary artery origin compressed by aortic aneurysm in its middle part. Dissection alongside aortic axis, including about 50% of aortic diameter, with thrombus — partially covering origins of neck arteries. Darker areas — false aneurysm channel, light areas — true lumen of aneurysm; **B.** The same picture reconstructed with MIP method; **C.** 3D-VR reconstruction of aorta. Three-diameter reconstruction of aorta, the aneurysm border clearly visible in aortic arch and descending aorta; **D.** Dilated pulmonary trunk with thrombi (darker points — one flagged by an arrow) in pulmonary arteries and its branches.