

# Recurrent myocardial infarction in a young football player with antithrombin III deficiency

Irena Peovska, Jelena Maksimovic, Oliver Kalpak, Hristo Pejkov, Marijan Bosevski

St. Cyril and Methodius University, Medical Faculty, Cardiology Clinic, Skopje, Macedonia

## Abstract

*Acute myocardial infarction is a rare condition in young athletes. One of the causes could be a hypercoagulable state due to congenital antithrombin III deficiency, together with a prothrombotic state soon after strenuous physical training. We present the case of myocardial reinfarction in young football player with antithrombin III deficiency, treated with primary percutaneous coronary intervention and drug eluting stent, as well as the functional repercussions of continuous intensive physical activity. (Cardiol J 2008; 15: 463–466)*

**Key words:** acute myocardial infarction, antithrombin III deficiency

## Case report

A 24-year-old active football player was admitted to the coronary unit (ICU) with severe chest pain that developed 1 hour after intensive physical training and 2 hours prior to admission. Acute myocardial infarction (MI) was diagnosed based on electrocardiographic (ECG) changes, which showed ST segment elevation of 4 mm in V1–V4 and reciprocal ST segment depression of 2 mm in DII, DIII and aVF, with no Q waves. The levels of CK-MB and troponin T were 25.0 and 0.117 ng/mL, respectively. He had no risk factors, absent family history and no previous anamnesis of cardiovascular disease. He denied use of any steroids or protein supplements. There were no abnormalities on physical examination. His blood pressure was 130/80 mm Hg. Laboratory data showed white blood cell count of  $9.5 \times 10^9/L$ , fibrinogen 2.37 g/L (2–4), C-reactive protein 1.1 mg/L (0–6) and other parameters within normal limits. He received a bolus dose of 10,000 units of unfractionated heparin, and emergent coronary angiography was performed. Coronary angiography showed a total occlusion with thrombus and TIMI 0 distal flow in the proximal portion of the left

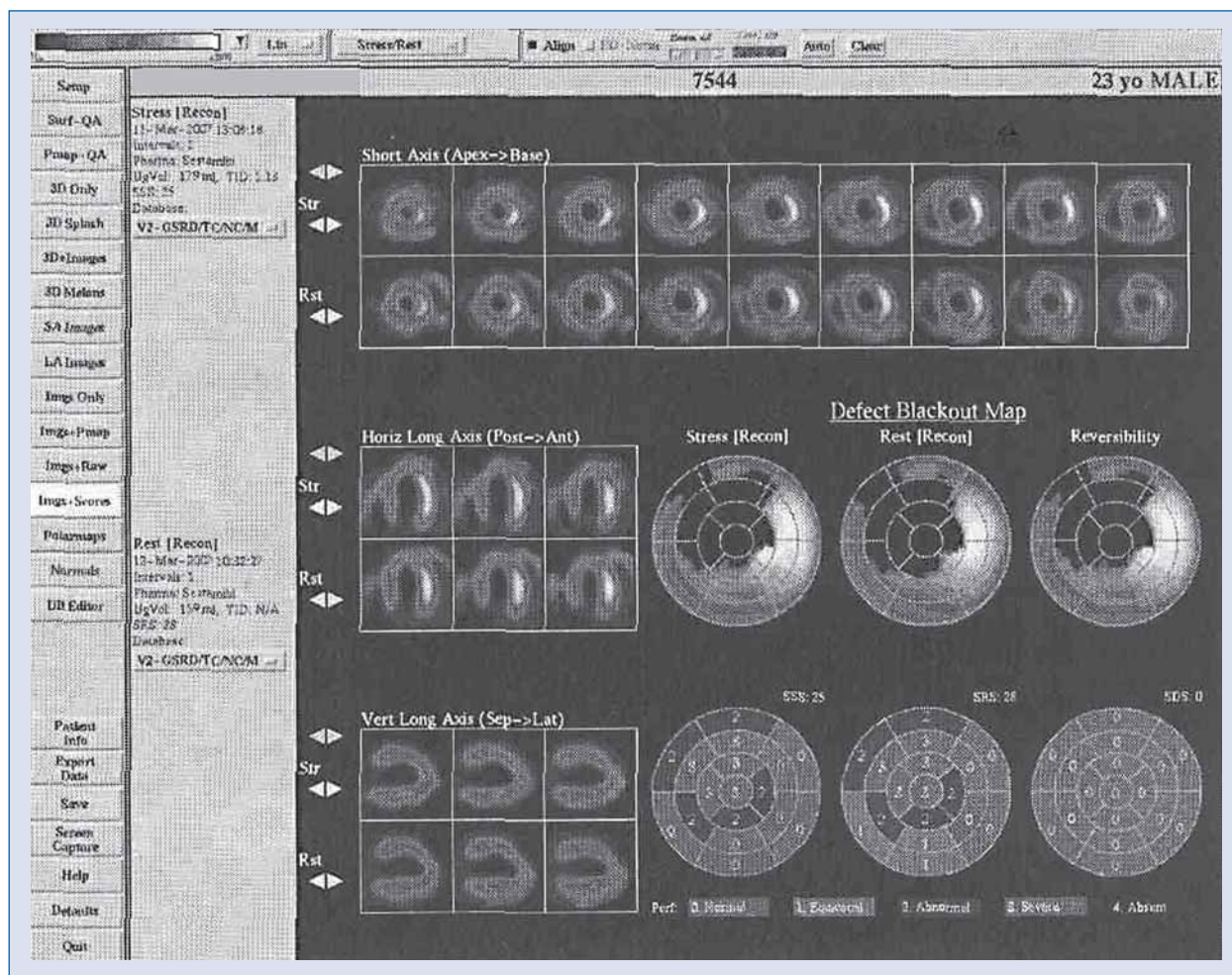
anterior descending coronary artery (LAD), which was successfully treated with a Taxus stent. After percutaneous coronary intervention (PCI), the patient became stable without chest pain and was discharged on the fifth hospital day. Hematological analyses performed two weeks after acute myocardial infarction showed the following results: fibrinolysis activators 62% (60–120%); fibrinolysis inhibitors 55% (60–120%); D-dimer 133  $\mu\text{g/mL}$  ( $< 250$ ); antiphospholipid antibodies 8 SAU (0–20) and antithrombin III (AT III) 0.13 (0.17–0.3 g/L). Due to AT III deficiency, he was put on anticoagulant therapy. Patient lipid profile before discharge was: total cholesterol 9.5 mmol/L, LDL cholesterol 3.8 mmol/L, HDL cholesterol 1.2 mmol/L and triglycerides 0.9 mmol/L. Echocardiography before discharge showed apical hypokinesia with ejection fraction of 62%, end diastolic dimension 62mm and hypertrophy of the septum 16 mm. His therapy included the beta blocker Bisoprolol 5 mg per day, anticoagulant acenocoumarin (Sintrom) — according to international normalized ratio (INR) values, Plavix 75 mg per day for one year and simvastatin 20 mg per day.

After this event he was asymptomatic and he stopped anticoagulant therapy after 6 months,

**Address for correspondence:** Dr. Irena Peovska, Cardiology Clinic, St. Cyril and Methodius University, Medical Faculty, Vodnjanska 17, 1000 Skopje, Republic of Macedonia, tel: ++389 2 3225 895; fax: ++389 2 3110 159; e-mail: irena\_peovska@yahoo.com

Received: 2.05.2008

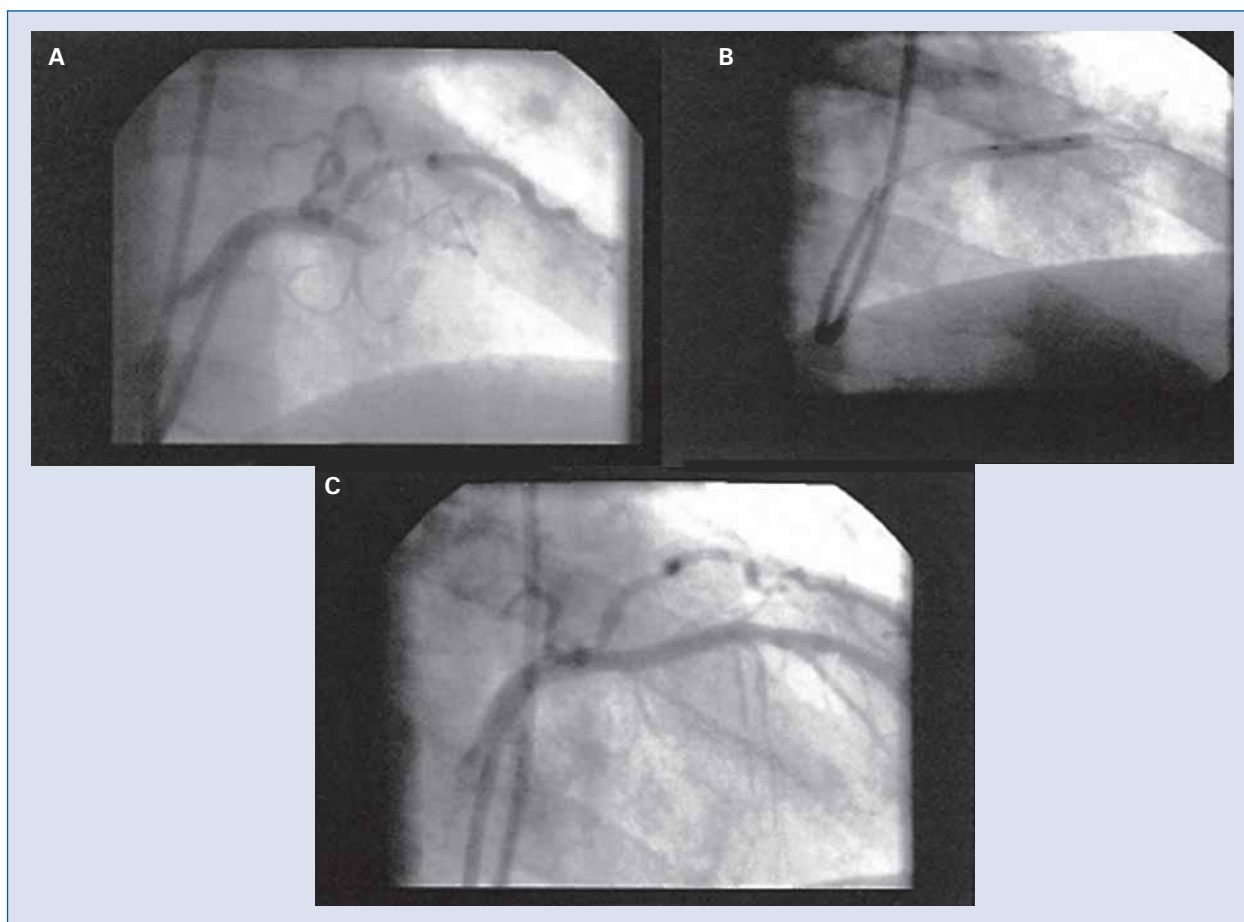
Accepted: 7.06.2008



**Figure 1.** Myocardial perfusion imaging showed severe fixed perfusion defect at the anterior, antero-septal and apical wall (vascular region left anterior descending), which takes 42% of left ventricular myocardium, with 10% of peri-infarction hibernated myocardium. Left ventricular function is severely reduced, with ejection fraction 35% and large remodelled left ventricle with increased left ventricular volumes.

continuing active football playing and physical training, regardless of his physician’s advice. Hematological analyses were repeated 7 months after the myocardial infarction and showed the following results: fibrinolysis activators 65% (60–120%); fibrinolysis inhibitors 58% (60–120%); D-dimer 137  $\mu\text{g/mL}$  ( $< 250$ ); antiphospholipid antibodies 8 SAU (0–20) and AT III 0.12 (0.17–0.3 g/L). One month after he stopped Plavix therapy (13 months after MI), again 1 hour after intensive training, he felt severe chest pain. He was admitted to an ICU with ECG showing anteroseptal reinfarction with ST segment elevation in V1–V3, Q waves in these leads and ST segment depression in DII, DIII, aVF, V5 and V6 (Fig. 1). The levels of CK-MB and troponin T were 22.0 and 0.113 ng/mL, respectively. Emergent coronary angiography showed a total occlusion of the Taxus stent with thrombus and

TIMI 0 distal flow in the proximal portion of LAD which was successfully treated with in-stent dilatation (Fig. 2). After intervention, the patient became stable without chest pain and was discharged on the sixth hospital day. Despite his physician’s advice to reduce physical activity and active football training, he still continues his training. Echocardiography 6 months after reinfarction showed ejection fraction 50%, septum 10 mm, and hypokinesia of the distal septum and apical wall. One-day rest/stress Tc-99m sestamibi myocardial perfusion gated SPECT imaging (MPI) was performed 10 months after the reinfarction. Treadmill stress test was negative, with 100% cardio respiratory activity, MET 11, and 70% of maximal HR achieved, without chest pain or dyspnoea. MPI showed severe fixed perfusion defect at the anterior, antero-septal and apical wall (vascular region LAD), which takes



**Figure 2.** **A.** Angiographic presentation of proximal left anterior descending thrombosis during the first myocardial infarction; **B.** A view of ballooning to implant the stent; **C.** Final view of left anterior descending and diagonal branch subsequent to stenting.

42% of left ventricular myocardium, with 10% of peri-infarction hibernated myocardium. Left ventricular function was severely reduced, with ejection fraction 35% and large remodelled left ventricle with increased left ventricular volumes. Coronary angiography showed patent Taxus stent (no in-stent restenosis and no changes in other coronary vessels). The patient was put on intensive therapy for heart failure (ACE-inhibitor — enalapril 20 mg per day, beta-blocker — carvedilol 2.5 mg twice per day, anticoagulant acenocoumarin (Sintrom) according to INR values, atorvastatin 20 mg per day). He was advised to stop football playing and intense physical activity.

### Discussion

To our knowledge, this is the first report of myocardial reinfarction in a young athlete with AT III deficiency treated with a Taxus stent. He has no traditional risk factors and normal C-reactive pro-

tein and fibrinogen values. Acute myocardial infarction is rare in teenagers and young adults. Myocardial infarction in young adults can be broadly divided into two groups: those with angiographically normal coronary arteries and those with coronary artery disease of different etiology [1]. The pathophysiology of myocardial infarction in the presence of “normal” coronary arteries remains unclear but can be explained based on coronary artery thrombosis, embolisation, spasm, or a combination of these processes. Coronary thrombosis can be seen in hypercoagulable states such as in the nephrotic syndrome, antiphospholipid syndrome, and protein S and factor XII deficiencies [1–4]. A reduction in the concentration of antithrombin III is particularly responsible for the thrombophilic tendency in most of the subjects. Factor V Leiden mutation is associated with a procoagulant state and has been reported to result in MI in young people [1].



Coronary artery spasm causing MI is recognised with both the recreational and therapeutic use of cocaine, alcohol binges and amphetamine use. Systemic collagen tissue disorders, like systemic lupus are considered one for the rare factors for MI in young adults, caused by increased inflammatory response.

Myocardial infarction in young adults might be the result of premature atherosclerosis due to genetic polymorphisms of apoL, hyperhomocysteinemia, and other procoagulant disorders [5]. Mutations in the gene encoding the low-density lipoprotein receptor produce familial hypercholesterolemia, clinically characterised by high serum cholesterol (low-density lipoprotein fraction) concentrations, xanthomas and premature atherosclerosis. Other risk factors include smoking, hypertension, insulin resistance, obesity and a family history of premature cardiovascular events. Anomalous origins of either left or right coronary arteries have been associated with myocardial infarction and are related to acute angulations and compression of the artery at its origin or along its course.

Antithrombin III is a potent inhibitor of the coagulation cascade. Congenital AT III deficiency is an autosomal dominant disorder. This condition leads to an increased risk of venous and arterial thrombosis, with an onset of clinical manifestations typically appearing in young adulthood. Once a patient with congenital AT III deficiency has developed thrombosis, anticoagulation is indicated. Prognosis depends on 3 variables: the degree of the deficiency, the nature of the observed clot and the number of clots seen [5, 6].

Acute myocardial infarction in young athletes can be caused by several mechanisms. Clinical observations suggest that continuous, prolonged, moderate-intensity exercise is associated with markedly elevated IL-6 and acute-phase reactant concentrations, peripheral tissue damage and significant changes in serum lipid levels. Strenuous and/or prolonged physical activity leads to muscle and other tissue damage and thereby induces an inflammatory response characterized by secretion of pro-inflammatory cytokines, chemokines and other mediators of inflammation. In addition, strenuous

and/or prolonged physical activity perturbs intermediary metabolism and produces a wide variety of changes in the plasma concentrations of metabolites, including those of lipids and lipoproteins, which in general appear to be antiatherogenic. In contrast to what is observed with exercise, HDL particles lose their protective enzyme, paraoxonase, and platelet-activating factor, acetylhydrolase, whereas they concomitantly develop a marked increase in their content of serum amyloid A and ceruloplasmin, all changes that result in an overall diminution of their antiatherogenic properties. In our patient, white blood cells, C-reactive protein, fibrinogen, as well as lipid values at the acute phase, were within normal limits.

In the current case, we can assume the casual relation between AT III deficiency, clopidogrel and oral anticoagulation therapy discontinuation and late drug eluting stent thrombosis, as well as the prothrombotic and proinflammatory effects of strenuous physical activity on coronary events, which all lead to acute coronary thrombosis. In the future, further studies are warranted to clarify this issue in terms of etiological and pathophysiological aspects as well as preventive and treatment measures in this specific population.

## Acknowledgements

The authors do not report any conflict of interest regarding this work.

## References

1. Egred M, Viswanathan G, Davis GK. Myocardial infarction in young adults. *Postgrad Med J*, 2005; 81: 741–745.
2. Bosevski M, Kostoska S, Tosev S, Borozanov V. Prognostic importance of haemostatic parameters in polyarterial disease. *Prilozi*, 2005; 26: 81–92.
3. Andrassy K, Ritz E, Bommer J. Hypercoagulability in the nephrotic syndrome. *Klin Wochenschr*, 1980; 58: 1029–1036.
4. Jara LJ, Medina G, Vera-Lastra O, Shoenfeld Y. Atherosclerosis and antiphospholipid syndrome. *Clin Rev Allergy Immunol*, 2003; 25: 79–88.
5. Coller BS, Owen J, Jesty J et al. Deficiency of plasma protein C, protein S or antithrombin III and arterial thrombosis. *Arteriosclerosis*, 1987; 7: 456–462.
6. Khare A, Ghosh K, Shetty S, Kulkarni B, Mohanty D. Combination of thrombophilia markers in acute myocardial infarction of the young. *Ind J Med Scien*, 2004; 58: 381–388.