

## A-dip of the aortic valve by M-mode echocardiography

Ioannis Stathopoulos, Themistoklis Nissirios,  
 Robert Ostfeld, Garet Gordon, Daniel Spevack

Montefiore Medical Center, Albert Einstein School of Medicine Cardiology Bronx, NY, USA

### Abstract

*We present a case with the previously unreported finding of an a-dip in the M-mode tracing of the aortic valve. An a-dip is commonly seen in the M-mode tracing of the pulmonic valve motion, and represents near equalization of pulmonary artery and right ventricular end-diastolic pressures during atrial contraction. M-mode echocardiography has become an ancillary study to the basic two-dimensional examination, but can often convey important features of cardiac hemodynamics quite elegantly, as the present case demonstrates. (Cardiol J 2009; 16, 3: 273–275)*

**Key words:** a-dip, aortic valve, M-mode, echocardiography

### Case presentation

A 31 year-old woman with a history of ventricular septal defect and Eisenmenger syndrome was referred for echocardiographic evaluation. Her only reported symptoms were occasional palpitations with exertion, and a two-block exertional dyspnea and fatigue.

On physical examination, her sitting systolic blood pressure was 85 mm Hg with a non-audible diastolic blood pressure. Cuff blood pressure was 85/38 mm Hg. She exhibited a normal first heart sound (S1), an increased intensity single second heart sound (S2), and a 3/6 holosystolic murmur, without radiation, which was best heard at the left lower sternal border. There was no cardiac heave appreciated. She also displayed clubbing and cyanosis, with an oxygen saturation level of 82%.

### Transthoracic echocardiography

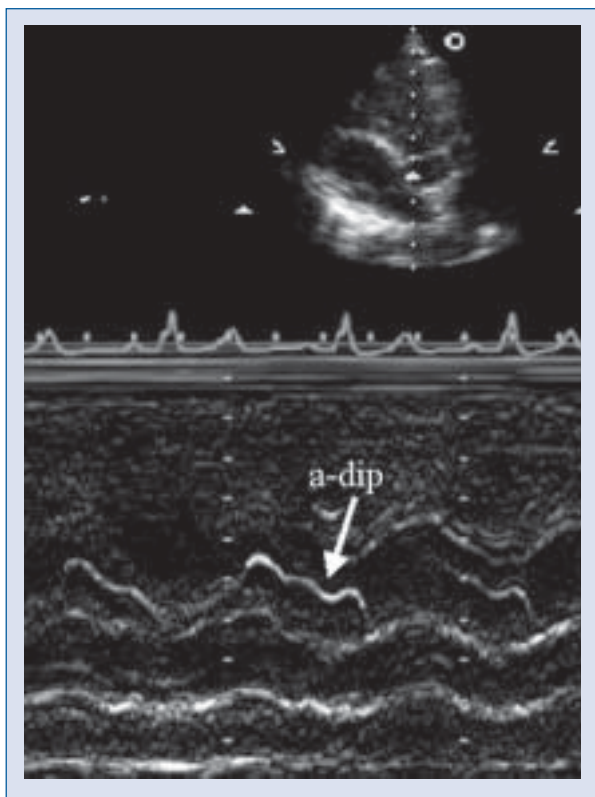
On a transthoracic echocardiogram, the left ventricle exhibited normal systolic function and wall motion. There was a large non-restrictive inlet ven-

tricular septal defect extending from mid-septum to the atrio-ventricular groove. Mild to moderate mitral regurgitation and moderate tricuspid regurgitation were seen. The patient's pulmonary artery systolic pressure was 80 mm Hg (the same as the systemic systolic blood pressure).

On M-mode examination of the aortic valve, the motion of the aortic leaflet mimicked the appearance of a normal pulmonic valve (Fig. 1). Following atrial contraction, there was a downward motion (posterior displacement) of the leaflet, the a-dip. Following the a-dip an upward motion (anterior displacement) of the leaflet was transiently seen, representing atrial relaxation. During ejection, the leaflets opened with maximal downward displacement. At end-systole, the aortic leaflet moved anteriorly until valve closure occurred.

### Discussion

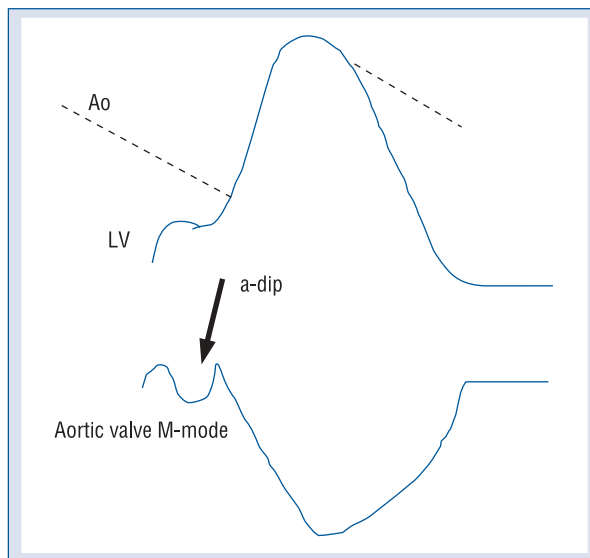
The M-mode appearance of the pulmonic valve motion has been well documented [1]. The finding of an a-dip has classically been attributed to a transient increase of right ventricular end-diastolic



**Figure 1.** M-mode examination of the aortic valve. The motion of the aortic valve leaflet mimicked the appearance of a normal pulmonic valve. Following atrial contraction, there is a downward motion (posterior displacement) of the valve, the a-dip. Following the a-dip an upward motion (anterior displacement) of the valve is transiently seen, representing atrial relaxation. During ejection, the leaflets open with maximal downward displacement. At endsystole, the aortic leaflet moves anteriorly until valve closure occurs.

pressure secondary to atrial contraction. As the right atrium contracts there is an elevation of the right ventricular end-diastolic pressure nearly to the level of the pulmonary arterial pressure. This causes the pulmonic leaflets to move toward the open position and is manifested as an a-dip on M-mode. When pulmonary hypertension is present, there is an elevation of the diastolic pulmonary artery pressure with a subsequent diminished, or even absent, a-dip.

Normally, the aortic valve should not manifest an a-dip due to the elevated diastolic pressure gradient between the left ventricle and the aorta. The demonstration of an aortic a-dip has been previously presented using continuous wave Doppler in a patient with aortic regurgitation and systemic hypotension [2]. As Sethi et al. [2] commented, in that patient the atrial pressure increase during atrial



**Figure 2.** Diagram of the pressure waveforms and the M-mode representation of the a-dip. Reduced left ventricular (LV) — aortic (Ao) gradient coincident with atrial contraction (A-wave) and corresponding a-dip in aortic valve M-mode tracing.

contraction constituted a large proportion of the total diastolic aortic-ventricular pressure gradient. This was due to increased left ventricular end-diastolic pressure and a low diastolic aortic pressure and therefore represented itself with a transient and prominent end-diastolic decrease of the aortic regurgitation flow velocity.

In the current case we show for the first time an M-mode echocardiographic representation of an a-dip of the aortic valve, an event that has been conceived in theory but never presented. Unlike the finding of Sethi et al. [2], an a-dip on M-mode indicates motion toward opening of the valve leaflets, and is not merely a measurement of the reduction in aortic-ventricular gradient with atrial contraction that the Doppler records.

The following reasons enabled the M-mode representation of the aortic valve a-dip. In this patient the spatial arrangement of the aortic valve was in the same plane as the pulmonic valve, rather than the normal orthogonal relationship. This allowed visualization of the aortic valve opening longitudinally from the parasternal window, in the same way that the pulmonic valve is normally demonstrated. In addition, because of low diastolic aortic pressure (cuff blood pressure was 85/38 mm Hg), the left ventricular A-wave generated was nearly high enough to open the aortic valve (Fig. 2).

The patient's only medical therapy was aspirin. Her hematocrit was 63%. The patient is still alive and doing well, three years after the initial echocardiographic study. No therapeutic phlebotomy was performed because the patient did not have any symptoms of hyperviscosity.

The patient's abnormal anatomy and hemodynamics were such that an a-dip appeared in the aortic valve M-mode tracing. The finding of an a-dip of the aortic valve by M-mode echocardiography indicates that the generated left ventricular A-wave was high enough to open the aortic valve and that the end-diastolic pressure in our patient must have been higher than 38 mm Hg, which was the measured diastolic aortic cuff blood pressure. This finding is of clinical value, because it provides information

for the better understanding of the patient's hemodynamic status.

This is the first time that such a finding has been described, indicating the contribution and value of M-mode, an ancillary and underused modality, in the better understanding of the patient's hemodynamics and the subtle changes of the aortic valve motion during the cardiac cycle.

## References

1. Feigenbaum H. Echocardiography. 5<sup>th</sup> Ed. Lippincott Williams & Wilkins, Baltimore 1995: 90–95.
2. Sethi JS, Shah A, Benenstein R, Rozenzweig BP, Tunick PA, Kronzon I. The a-dip of aortic regurgitation. *J Am Soc Echocardiogr*, 2003; 16: 1078–1079.