

Immediate ventricular tachycardia after abnormal microvolt T-wave alternans

Agnieszka Sędkowska, Beata Średniawa, Jacek Kowalczyk,
 Radosław Lenarczyk, Oskar Kowalski, Zbigniew Kalarus

1st Department of Cardiology, Medical University of Silesia,
 Silesian Center for Heart Diseases, Zabrze, Poland

Abstract

Microvolt T-wave alternans (MTWA) is a promising non-invasive method of evaluating repolarization abnormalities. Its presence is strongly related to the occurrence of malignant ventricular tachyarrhythmias and is therefore regarded as a risk marker for sudden cardiac death. Most recent studies have described the usefulness of MTWA in selecting patients who may benefit from a cardioverter-defibrillator.

This study presents two cases of patients suffering from ischemic cardiomyopathy, who underwent an MTWA test. Episodes of ventricular tachycardia occurred immediately after the end of the tests, with abnormal results. (Cardiol J 2009; 16, 4: 365–367)

Key words: T-wave alternans, ventricular tachyarrhythmia

Introduction

Microvolt T-wave alternans (MTWA) is a microvolt change in T-wave amplitude in every other beat. It is strongly correlated with the susceptibility to malignant ventricular tachyarrhythmias [1]. In recent years its relevance in predicting sudden cardiac death (SCD) and life-threatening arrhythmias has been documented in high risk patient groups [2, 3]. These observations are based on long-term follow-up studies. Our paper describes two cases of cardioverter-defibrillator (ICD) recipients who experienced ventricular tachycardias.

MTWA assessment

MTWA tests were performed using equipment manufactured by System Cambridge Heart Inc., Bedford, MA, USA, and were carried out during a treadmill exercise. The test was defined as positive when the sustained alternans voltage was $> 1.9 \mu V$

(with an alternans ratio > 3.0) for at least one minute with an onset heart rate < 110 bpm in two consecutive precordial leads or any orthogonal lead during exercise. The test was defined as negative when the positive criteria were not met at heart rate > 105 bpm and the data was free from any defects. If neither positive nor negative criteria were met, the test was defined as indeterminate [4]. Positive and indeterminate results were grouped together and constituted abnormal MTWA results [4]. Drug treatment involving beta-adrenolytics was not discontinued before the MTWA test.

Case 1

A 54 year-old woman who had experienced anterior myocardial infarction 29 years previously which had been treated conservatively, was hospitalized due to clinical and electrocardiographical symptoms suggesting unstable coronary artery disease with accompanying sustained VT (sVT). The ejection fraction in echocardiography decreased to

Address for correspondence: Agnieszka Sędkowska, MD, 1st Department of Cardiology, Silesian Center for Heart Diseases, Szpitalna 2, 41–800 Zabrze, Poland, tel: +48 32 271 34 14, fax: +48 32 271 76 92, e-mail: agasedko@poczta.onet.pl

Received: 13.11.2008

Accepted: 19.11.2008

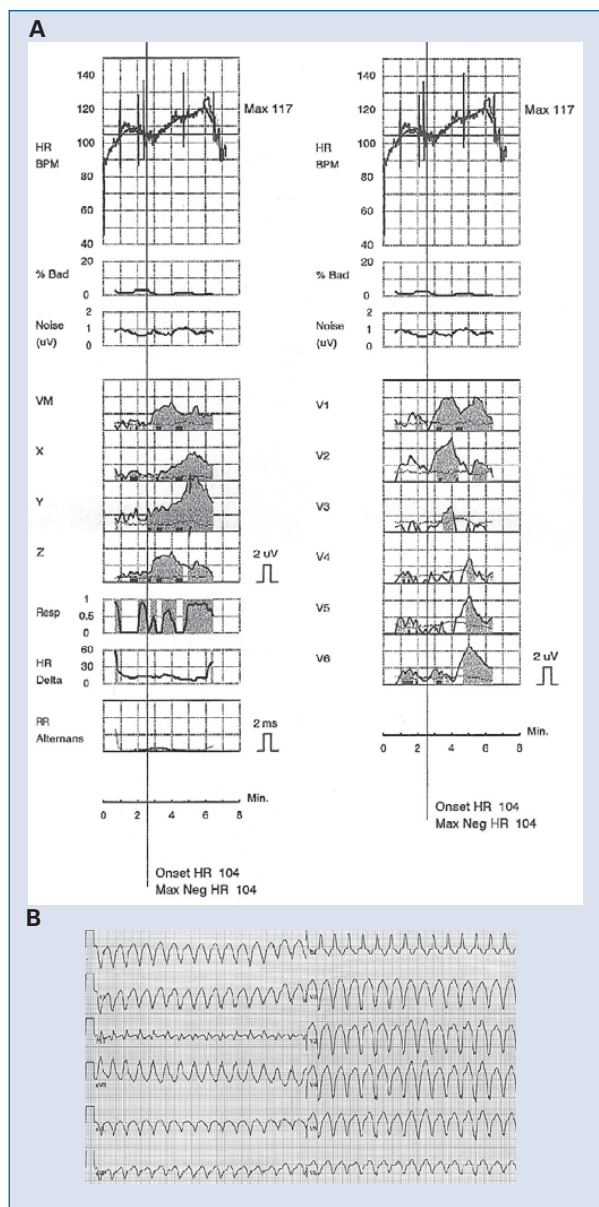


Figure 1. Positive microvolt T-wave alternans in a patient with ischemic cardiomyopathy (A) and ventricular tachycardia recorded during recovery after the test (B).

40%, the apex was akinetic and moderate mitral regurgitation was diagnosed.

Coronarography did not show significant stenosis in coronary arteries. The patient thus qualified for ICD. Before implantation, an MTWA test was performed and the result was positive. Approximately two minutes after the exercise, during the recovery phase, monomorphic sVT occurred with a rate of 180 bpm, which was terminated by intravenous amiodarone. sVT following positive MTWA is presented in Figure 1.

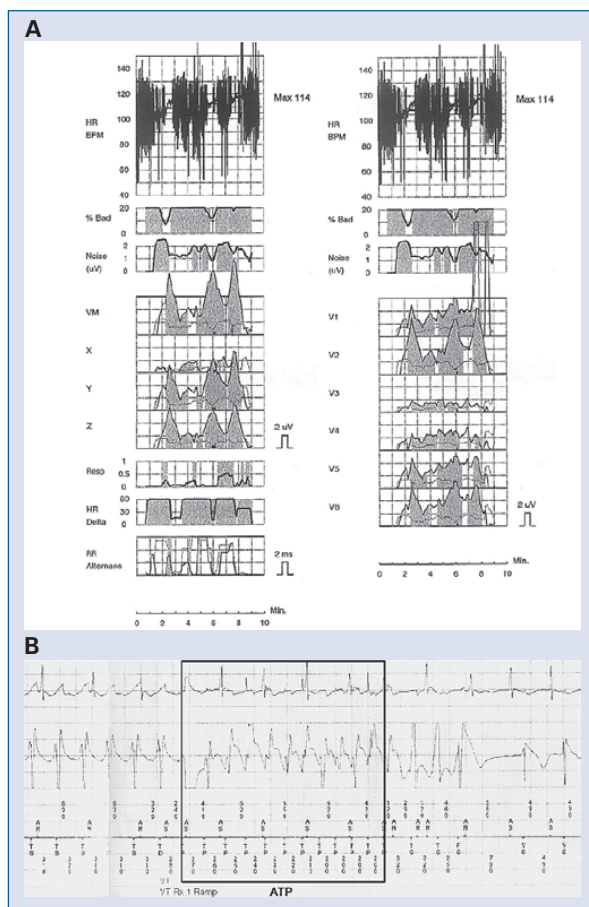


Figure 2. Indeterminate microvolt T-wave alternans in an ischemic implantable cardioverter-defibrillator (ICD) recipient (A) and ventricular tachycardia, documented in electrogram, successfully terminated by antiarrhythmic tachycardia pacing (ATP) delivered by ICD during the recovery phase of the microvolt T-wave alternans test (B).

Case 2

A 62 year-old woman with stable coronary artery disease and prior inferior wall myocardial infarction qualified for ICD implantation due to recurrent sVT. Ischemia had been excluded as the cause of the arrhythmia. Ejection fraction in echocardiography decreased to 40%. Following ICD placement, an MTWA test was performed to assess the risk of future malignant arrhythmias. The test was indeterminate due to numerous ventricular ectopic beats. Ventricular tachycardia occurred during recovery but was successfully terminated by ICD antitachycardia pacing. Indeterminate MTWA and the arrhythmic event in the recovery phase of the test recorded in the ICD memory are shown in Figure 2.

Discussion

These two cases present clear clinical evidence of the dependence between abnormal MTWA and the propensity to arrhythmic events in patients with implanted ICDs in secondary SCD prevention. Over the last decade, several studies have documented the role of MTWA in SCD risk stratification. Meta-analysis of 19 MTWA studies with a mean follow-up period of 21 months performed by Gehi et al. [5] revealed a 97.2% negative predictive value of MTWA, 19.3% positive predictive value and an unadjusted relative risk of 3.77 in the prediction of arrhythmic events. The Alternans Before Cardioverter Defibrillator trial, the first to have used MTWA to guide ICD therapy, showed that non-invasive MTWA-guided risk stratification predicts arrhythmic events as reliably as invasive electrophysiological study [6]. Moreover, the event rate in patients with two negative tests was very low (2%) [6]. The usefulness of MTWA in stratification of patients for ICD implantation was acknowledged in the new SCD ACC/AHA/ESC guidelines, with class IIa level of evidence A [7]. The most recent study, by Chow and involving patients with ischemic cardiomyopathy and ICD implanted for primary SCD prevention, revealed at 27-month follow-up a greater mortality rate in the group with abnormal MTWA [8]. Most studies of risk stratification consider as abnormal MTWA which combines positive and indeterminate results [2, 8]. It is particularly justified when frequent ventricular ectopic beats occur during the test [4, 8]. Such a situation occurred in our Case 2, where the indeterminate MTWA result was due to many ventricular premature complexes.

Our cases, with immediate arrhythmic events following abnormal MTWA, indicate that those who

will benefit from ICD implementation are ICD recipients characterized by abnormal MTWA.

Acknowledgements

All authors state that they do not have any conflict of interest to disclose.

References

1. Narayan SM. T-wave alternans and susceptibility to ventricular arrhythmias. *J Am Coll Cardiol*, 2006; 47: 269–281.
2. Ikeda T, Saito H, Tanno K et al. T-wave alternans as a predictor for sudden cardiac death after myocardial infarction. *Am J Cardiol*, 2002; 89: 79–82.
3. Salerno-Uriarte JA, De Ferrari GM, Klersy C et al. ALPHA Study Group Investigators. Prognostic value of T-wave alternans in patients with heart failure due to nonischemic cardiomyopathy: Results of the ALPHA Study. *J Am Coll Cardiol*, 2007; 50: 1896–1904.
4. Bloomfield DM, Hohnloser SH, Cohn RJ. Interpretation and classification of T-wave alternans tests. *J Cardiovasc Electrophysiol*, 2002; 13: 502–512.
5. Gehi AK, Stein RH, Metz LD, Gomes AJ. Microvolt T-wave alternans for the risk stratification of ventricular tachyarrhythmias events. A meta-analysis. *J Am Coll Cardiol*, 2005; 46: 75–82.
6. Costantini O, Rosenbaum DS, Hohnloser SH et al.; for ABCD Investigators. The Alternans Before Cardioverter Defibrillator (ABCD) Trial: A noninvasive strategy for primary prevention of sudden cardiac death using T-wave alternans. *Circulation*, 2006; 114: 2426.
7. Zipes DP, Camm AJ, Borggrefe M et al. ACC/AHA/ESC 2006 guidelines for management of patients with ventricular arrhythmias and the prevention of sudden cardiac death: A report of the American College of Cardiology/American Heart Association Task Force and the European Society of Cardiology Committee for Practice Guidelines. *Europace*, 2006; 8: 746–837.
8. Chow T, Kereiakes DJ, Bartone C et al. Prognostic utility of microvolt T-wave alternans in risk stratification of patients with ischemic cardiomyopathy. *J Am Coll Cardiol*, 2006; 47: 1820–1827.