

# Huge ascending aortic pseudoaneurysm 13 years after Bental surgery with tube graft

Hossein Ahmadi<sup>1</sup>, Shapour Shirani<sup>2</sup>, Mohammad Saheb Jam<sup>3</sup>,  
 Ali Mohammad Haji Zeinali<sup>3</sup>, Parin Yazdanifard<sup>1</sup>

<sup>1</sup>Cardiovascular Surgery Department, Tehran Heart Center, Tehran University of Medical Sciences, Iran

<sup>2</sup>Radiology Department, Tehran Heart Center, Tehran University of Medical Sciences, Iran

<sup>3</sup>Cardiology Department, Tehran Heart Center, Tehran University of Medical Sciences, Iran

## Abstract

*Pseudoaneurysms of the ascending aorta are rare, disastrous complications of surgical manipulation of the aorta and its surroundings. They frequently require emergency surgical intervention due to a high risk of sudden rupture and hemorrhage. We herein present the case of a pseudoaneurysm (130 mm in diameter) of the ascending aorta with a compressive effect on the left atrium and right coronary artery ostium at the site of a tube graft implanted 13 years previously via the Bental procedure in a 34 year-old man. The susceptibility of these pseudoaneurysms to silently increase in size through the years leads to a delayed diagnosis, with an increased risk of rupture and mortality, necessitating long-term follow-ups with a view to detecting it in the initial stages, when it is easier to perform surgical or endovascular interventions with a lower risk of mortality. (Cardiol J 2011; 18, 2: 185–188)*

**Key words:** ascending aorta, aortic operation, pseudoaneurysm

## Introduction

Post-surgical aortic pseudoaneurysms are rare, albeit disastrous, complications in 0.5% of instances of cardiac surgery and they pose high mortality risks [1, 2]. As set out in previous reports and a large literature review by Dumont et al. [2], post-surgical aortic pseudoaneurysms often occur in the wake of procedures that utilize vascular prostheses or biosthetic grafts such as the Bental procedure [2–4]. The diameter and size of the aortic pseudoaneurysm may increase over the years, which could consequently increase the risk of sudden rupture and hemorrhage [3]. We herein describe the successful treatment of a huge pseudoaneurysm of ascending aorta (about 130 mm in diameter) in a patient with severe dyspnea, 13 years after a Bental procedure. Such a case has been rarely if ever reported.

## Case presentation

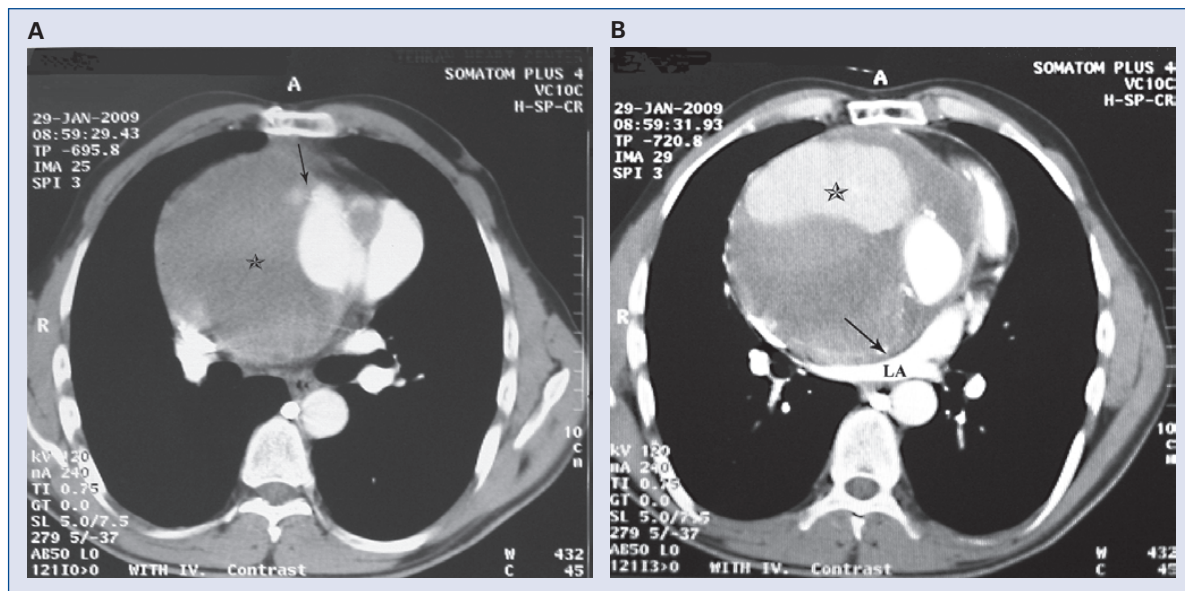
A 34 year-old man complaining of long-term dyspnea and chest pain with progression within the preceding three months was admitted to our hospital. He had undergone the Bental operation 13 years previously, at which time he had aortic valve replacement and replacement of the aneurysmal aortic root with the use of a prosthetic tube graft. Physical examination revealed normal vital signs and cardiac auscultation but systemic cyanosis.

Echocardiography showed an acceptable transprosthetic aortic valve gradient with no paravalvular leakage or regurgitation, severe tricuspid valve regurgitation, mild mitral valve regurgitation, and moderate pulmonary valve insufficiency. Additionally, a huge space around the aortic root and the ascending aorta full of clot formation (about 70 mm) with compressive effects on the left atrium, right

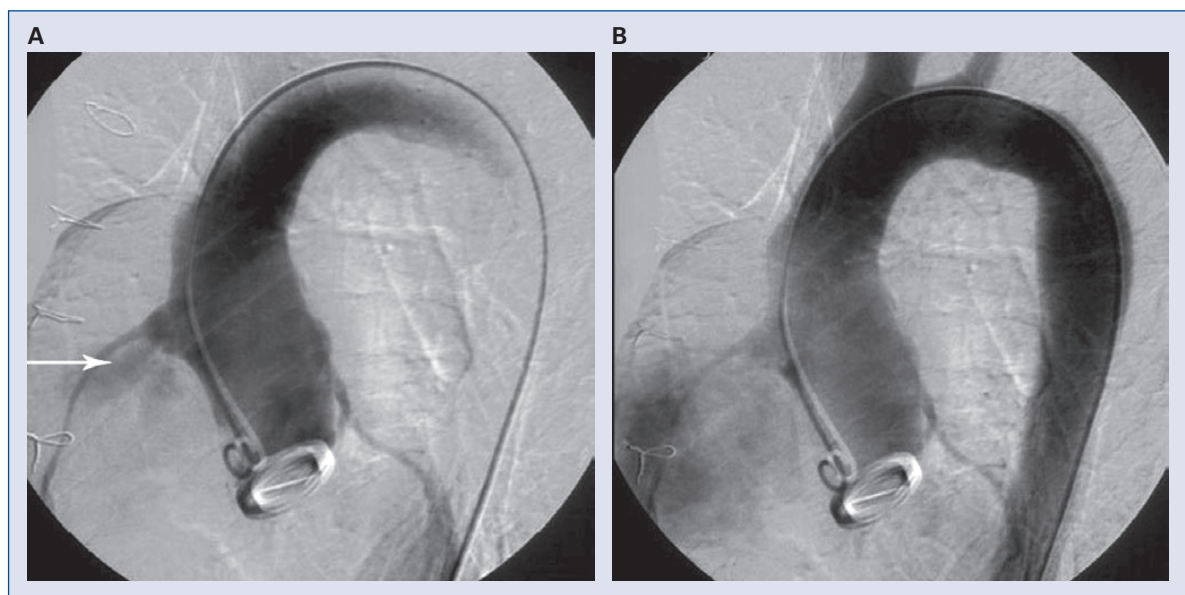
**Address for correspondence:** Parin Yazdanifard, MD, Tehran Heart Center, Tehran University of Medical Sciences, North Kargar Street, Tehran, Iran, 1411713138, tel: +98 2188029256, fax: +98 2188029256, e-mail: parinyazdanifard@yahoo.com

Received: 9.11.2009

Accepted: 11.12.2009



**Figure 1. A.** Computed tomography angiography at the level of left bronchus. Astrix shows a large pseudoaneurysm and the arrow shows leaking site from ascending aorta; **B.** Computed tomography angiography at the level of left atrium. The arrow shows compressed left atrium (LA) by pseudoaneurysm. Astrix shows contrast leak in sac of pseudoaneurysm.

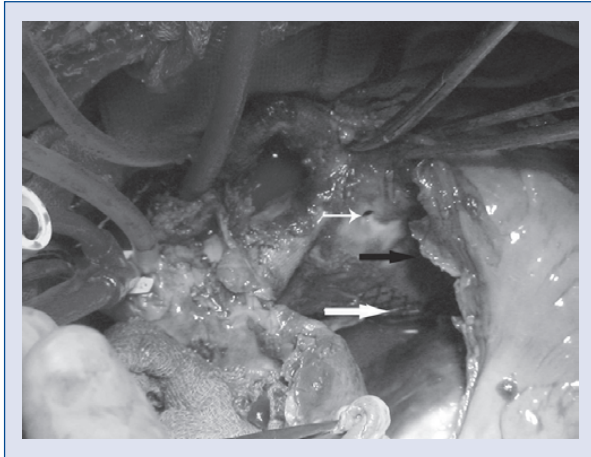


**Figure 2. A.** Coronary angiography: arrow shows the flow within the entrance of pseudoaneurysm; **B.** Coronary angiography: area of a large pseudoaneurysm

atrium, and ascending aorta were found. The right ventricle was moderately dilated with a normal global systolic function, and the global ejection fraction was approximately 50%. Thoracic aorta computed tomography angiography detected a pseudoaneurysm about 130 mm in diameter around the ascending aorta, with pressure effects on the left atrium (Fig. 1). The right-side cardiac chambers were en-

larged. The origin of the leakage was close to the right Valsalva sinus. Coronary angiography also confirmed a large aneurysm of ascending aorta (Fig. 2).

The patient was immediately referred for surgical intervention. Through the mid-sternotomy approach, cardiopulmonary bypass (CPB) was initiated using both femoral artery and vein cannulation. and the patient was cooled to 18 degrees centigrade.

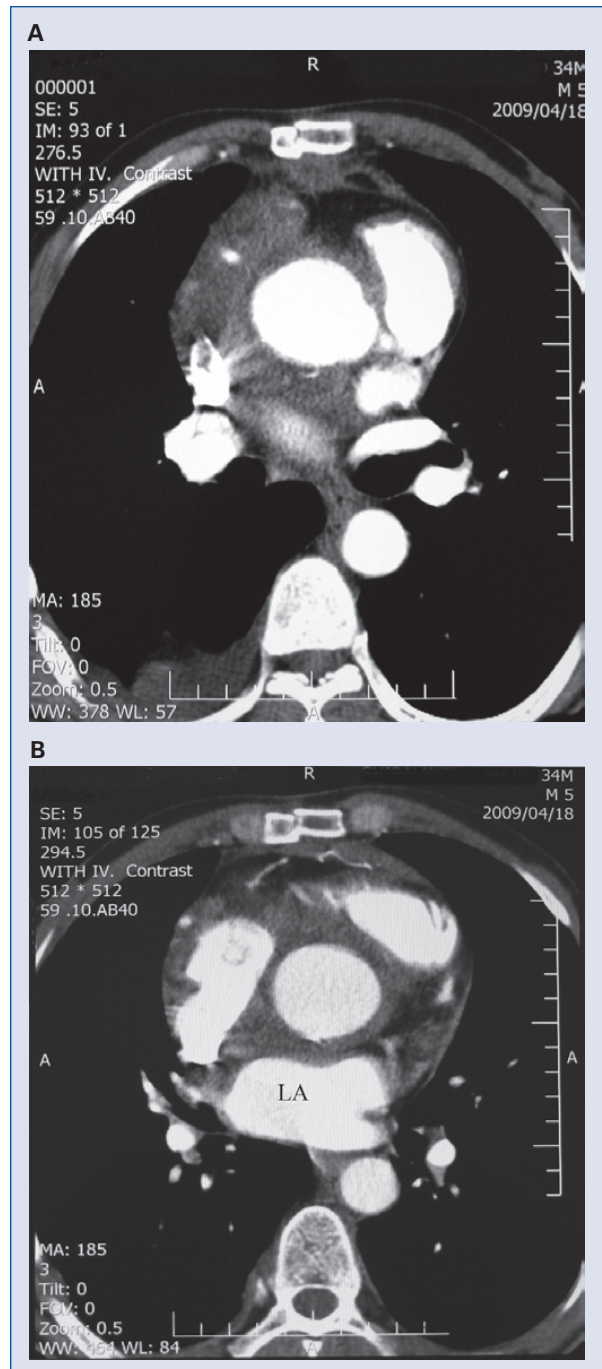


**Figure 3.** Surgical view: the black arrow shows the pseudoaneurysm, the thick white arrow shows tube graft, and the thin white arrow shows the orifice of the pseudoaneurysm.

At the opening of the pericardium, there was a typical ascending aorta aneurysm. The distal part of the ascending aorta was dissected free from the pulmonary artery; and after clamping the aorta and blood cardioplegia injection through the right coronary ostium, the aneurysm was incised. The inside of the aneurysm was full of blood clots, which surrounded the tube graft (Fig. 3). The entry side of the aneurysm was identified on the anterior side of the tube graft anteriorly close to the right coronary artery ostium, and was about 5 mm in diameter. All the clots were thereafter removed. The disruption of the right coronary ostium on the tube graft rendered it unsuitable for repair. It was, therefore, ligated and the defects of the ostium and pseudoaneurysm on the tube graft could be repaired with a pericardial patch.

A saphenous vein graft was distally anastomosed to the trunk of the right coronary artery and proximally to the pericardial patch on the aorta. Additionally, the severely insufficient tricuspid valve was replaced. CPB and aortic cross-clamp times were 85 and 245 min, respectively. After long-run anesthesia and CPB, the patient was weaned from CPB and admitted to the intensive care unit with a transfusion of two units of packed cells and three units of fresh frozen plasma.

Post-operative transesophageal echocardiography revealed acceptable trans-prosthetic aortic and tricuspid valve gradients and no visible leakage around the valves or the anastomotic sites. Three months later, the patient remained in a stable clinical and paraclinical condition and the follow-



**Figure 4A.** Post-treatment computed tomography angiography at the level of left main branch. There is no sign of leak around the aortic root; **B.** Post-treatment computed tomography angiography shows left atrium (LA) has resumed its normal diameter following treatment.

up computed tomography-angiography revealed no sign of contrast leak, with some organized thromboses around the aortic root, some pericardial and right-side pleural effusion (Fig. 4).



## Conclusions

The diameter and size of the aortic pseudoaneurysm may expand and can increase the risk of sudden rupture, hemorrhage, fistula formation and thrombosis, or generate symptoms due to the compression on the adjacent organs such as right-side heart failure signs and symptoms [3, 5]. Aortic pseudoaneurysms are rare, albeit severe, complications. Their tendency to silently increase in size over the years may result in a delayed diagnosis with an increased risk of rupture and mortality such as the case that Bouzas-Mosquera et al. [6] reported. Hence the expediency of long-term follow-ups of patients with any types of aortoplasty, aneurysmorrhaphy, or aneurysmectomy, especially using biosthetic, prosthetic tube grafts or patches. Within long-term follow-ups, aneurysm or pseudoaneurysm formation can be detected in an initial stage of progression, which makes surgical or endovascular treatments easier and reduces the risk of mortality.

## Acknowledgements

The authors do not report any conflict of interest regarding this work.

## References

1. Katsumata T, Moorjani N, Vaccari G, Westaby S. Mediastinal false aneurysm after thoracic surgery. *Ann Thorac Surg*, 2000; 70: 547–552.
2. Dumont E, Carrier M, Cartier R et al. Repair of aortic false aneurysm using deep hypothermia and circulatory arrest. *Ann Thorac Surg*, 2004; 78: 117–120.
3. Mohammadi S, Bonnet N, Leprince P et al. Reoperation for false aneurysm of the ascending aorta after its prosthetic replacement: Surgical strategy. *Ann Thorac Surg*, 2005; 79: 147–152.
4. Bical OM, Heran J, Thebault B, Funck F. Pseudoaneurysm following Dacron replacement of the ascending aorta. *Eur J Cardiothorac Surg*, 2009; 35: 536.
5. Mulder EJ, van Boeckel JH, Maas J, van den Akker PJ, Hermans J. Morbidity and mortality of reconstructive surgery of noninfected false aneurysms detected long after aortic prosthetic reconstruction. *Arch Surg*, 1998; 133: 45–49.
6. Bouzas Mosquera A, Rodríguez Vilela A, Fábregas R, Peteiro J, Alvarez García N, Castro Beiras A. Impending rupture of a giant ascending aortic aneurysm. *Cardiol J*, 2009; 16: 84–85.