

Quality of visualization of coronary venous system in 64-slice computed tomography

Agnieszka Młynarska^{1,2}, Rafał Młynarski^{1,2}, Włodzimierz Kargul², Maciej Sosnowski^{1,3}

¹Unit of Noninvasive Cardiovascular Diagnostics, Upper-Silesian Medical Centre, Katowice, Poland

²Department of Electrophysiology, Upper-Silesian Medical Centre, Katowice, Poland

³3rd Division of Cardiology, Medical University of Silesia, Katowice, Poland

Abstract

Background: Multi-slice computed tomography (MSCT) can be used to visualize the anatomy of the coronary venous system (CVS). A pre-procedural evaluation of target veins is a very important element of cardiac resynchronization. Thus, the quality of visualization of the CVS is of great importance. The aim of this study was to analyze the quality of visualization of CVS in MSCT.

Methods: In 220 subjects (129 male, average age 57.2 ± 11.8 years), a 64-slice CT (Aquilion 64, Toshiba, Japan) was performed. A scan with ECG-gating was performed using a slice thickness of 0.5 mm during a breath-hold. In each case, 3D volume rendering and 2D MPR reconstructions were created (Vitrea 2). The quality of visualization was graded independently by two cardiologists and a radiologist trained in MSCT on a 0–5 points scale for the coronary sinus and main veins [0 = not visible (lack of vein); 5 = visible as a smoothly bordered vascular structure].

Results: The best visualization of the CVS was obtained for coronary sinus (4.10 ± 1.08), the worst for antero-lateral vein (2.11 ± 1.10). The average number of visible veins was 3.2 per case. Statistically, more veins were visible in older subjects — in the group aged 60+ the average number of visible veins was 3.6 ± 1.1 per case, whereas in those aged under 60 it was 2.9 ± 1.2 ($p = 0.0001$). There were no statistical gender differences in the quality of CVS visualization.

Conclusions: The target veins for cardiac resynchronization therapy should be the lateral and postero-lateral, which are usually well visible. Such a strategy could increase the usefulness of MSCT. (Cardiol J 2011; 18, 2: 146–150)

Key words: coronary venous system, quality of visualization, cardiac resynchronization

Editorial p. 117

Introduction

Cardiac resynchronization therapy is a well established treatment for patients with advanced

heart failure [1, 2]. The main aim of this method is to restore proper synchrony between the right and left ventricles of the heart. To reach this goal, left ventricle lead implantation is necessary as an add-on for right ventricle lead implantation [3, 4]. Knowledge of the anatomy of the coronary venous system (CVS) is an important part of successful left

Address for correspondence: Agnieszka Młynarska, MS, RN, Upper-Silesian Cardiology Center, Unit of Noninvasive Cardiovascular Diagnostics, Ziołowa 45/47, 40–635 Katowice, Poland, tel: +48 32 359 88 93, fax: +48 32 252 40 98, e-mail: agnieszkawlodyka@o2.pl

Received: 29.05.2010

Accepted: 22.07.2010

Table 1. Characteristics of the examined group — average values (min, max, SD) of the main cardiac function parameters.

	Average value	Min. value	Max. value	SD
Ejection fraction (%)	62.2	8.0	86.0	10.0
End-diastolic volume [mL]	143.6	69.0	464.0	43.2
End-systolic volume [mL]	56.7	11.0	425.0	36.5
Stroke volume [mL]	87.7	47.0	151.0	19.4
Cardiac output [L/min]	5.4	1.8	13.9	1.6
Myocardial mass [g]	138.4	68.0	371.0	44.1
Myocardial volume [mL]	131.6	64.0	352.0	42.1
Heart rate [bpm]	62.0	45.0	157.0*	10.7

*In one patient, heart rate during scanning increased to 157 bpm

ventricular lead implantation, because in a small proportion of cases there are significant difficulties during the procedure [5, 6]. Various studies have shown the usefulness of both non-invasive and invasive visualization methods. The role of echocardiography is mainly to evaluate asynchrony and to find potential non-responders for cardiac resynchronization [7]. Nowadays, multi-slice computed tomography (MSCT) is also considered as a method of visualization of the anatomy of the CVS [8–11].

The aim of our study was to analyze the quality of visualization of the CVS, including the coronary sinus and all coronary veins, in 64-slice computed tomography.

Methods

A total of 220 subjects (129 male; average age 57.2 ± 11.8 years) were included in the study. In each case, a 64-slice computed tomography was performed because of a suspicion of coronary artery disease.

Subjects were excluded if they presented any of the following: atrial fibrillation (permanent or persistent); frequent cardiac extrasystoles; renal insufficiency (serum creatinine ≥ 1.3 mg/dL); hyperthyreosis; a known allergy to non-ionic contrast agents; or a previously implanted pacemaker with unipolar leads. The characteristics of the included patients are set out in Table 1.

The study protocol was approved by the local Ethics Committee. Informed consent was obtained from each patient.

MSCT protocol

A 64-slice computed tomography of the heart was performed using an Aquilion 64 scanner (Toshiba Medical Systems, Japan). Scanning with retrospec-

tive ECG-gating was performed using a 64-slice with a collimated slice thickness of 0.5 mm during a breath-hold. The helical pitch was 12.8 (best mode) and rotation time was 0.4 s. The average tube voltage was 135 kV at 380 mA, which was strictly dependent on the patient's body mass index (BMI). A pre-selected region of interest was used in this examination. In each case, the start of the scan was exactly the same as that for a routine arterial imaging. All reconstructions were created in the optimal phase for coronary veins — three high quality reconstructions were created [12]. Sixty five beats per minute was used as the cut-off for heart rate. If the heart rate was higher, metoprolol succinate (Betaloc, Astra Zeneca, Sweden) at a dose of 5–10 mg was administered intravenously (if not contraindicated). If the expected heart rate slowing was not achieved, the patient was excluded from the study. On average, 100 mL of non-ionic contrast agent (Ioperamid, Ultravist 370, Schering, Germany or Iomeprolum, Iomeprol 400, Bracco Int., Germany) was administered to each patient during the examination at an average rate of 5.0 mL/s. Contrast was given in three phases: 90 mL of contrast agent (average), then 24 mL of contrast agent and 16 mL of saline flush (60%/40%), and finally 30 mL of saline.

Grading

All measurements including grading were performed using Vitrea 2 workstation (Vital Images, Minnetonka, MN, USA; software version 3.9.0.0). The quality of visualization was graded independently by two experienced MSCT investigators on a 0–5 points scale for the coronary sinus and main veins [0 = not visible (lack of vein); 5 = visible as a smoothly bordered vascular structure]. Precise scores are presented in Table 2 [12].

Table 2. Introduced scale of visualization for arteries and veins [12].

Score	Description
0	No vessel(s) present*
1**	Vessel, length less than 5 mm, weakly contrasted and/or with a number of artifacts
2	Between score 1 and score 3
3	Vessel longer than 1 cm, better contrasted. Sometimes areas not visible or artifacts occurred
4	Between score 3 and score 5
5	Vessel well contrasted, visible clearly along the entire length of the vessel

*When the vein is not visualized in any of the phases, it has a grade 0. However, this does not necessarily mean that the vein is absent — it could be for instance very small and therefore lower than the resolution of the computed tomography scanner; **Grade 1 means that a vessel is present but very poorly visualized.

In a subset of 15 patients, intra- and inter-observer agreement was evaluated. Reproducibility of the phase determination was evaluated using the Bland-Altman method and by calculation of the inter-rater agreement coefficient kappa. Correlations between data were calculated by means of the Spearman rank coefficient (MedCalc Soft, Belgium).

Results

In all cases, visualization of coronary venous system was possible. Examples of 3D visualization are presented in Figure 1. The average quality of the visualization of the CVS is presented in Table 3 as the point-scale value ± standard deviation. The average number of visible veins was 3.2 per case. Statistically, more veins were visible in older subjects — in the group aged 60+ the average number of visible veins was 3.6 ± 1.1 per case, whereas in those aged under 60 it was 2.9 ± 1.2 ($p = 0.0001$). There were no gender differences in the quality of coronary veins visualization.

Inter- and intra-observer error in the evaluation of the quality of the reconstructions was evaluated with the mean difference of -0.04 (95% CI $-1.07-1.00$) and inter-rater agreement kappa 0.61. There were similar results in a repeated evaluation of the score by the same observer (mean difference 0.0, 95% CI $-1.4-1.4$ and kappa 0.66).

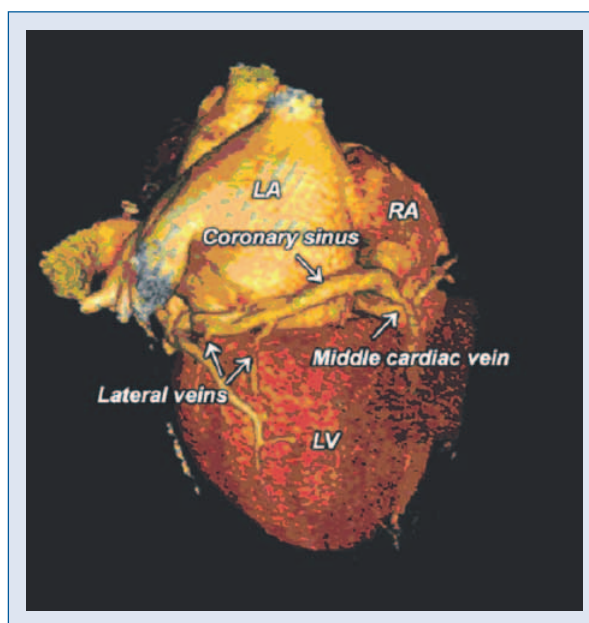


Figure 1. An example of reconstructions of the posterior area of the heart. Visible are: coronary sinus, lateral veins and middle cardiac vein (3D VR, 2D MPR; 64-slice, 2 mm slice thickness); LV — left ventricle; LA — left atrium; RA — right atrium.

Discussion

In the Appropriateness Criteria, MSCT for non-invasive coronary vein mapping prior to the place-

Table 3. Results — quality of visualization of the coronary venous system.

	Quality of coronary sinus	Quality of posterior vein	Quality of postero-lateral vein	Quality of lateral vein	Quality of anterolateral vein	Quality of anterior vein
General population	4.10 ± 1.08	3.18 ± 1.57	3.31 ± 1.52	3.12 ± 1.38	2.11 ± 1.10	2.79 ± 1.33
Women	4.12 ± 1.06	3.16 ± 1.57	3.24 ± 1.51	3.08 ± 1.41	2.37 ± 1.21	2.68 ± 1.16
Men	4.08 ± 1.09	3.19 ± 1.58	3.37 ± 1.54	3.14 ± 1.37	2.00 ± 1.04	2.89 ± 1.45

ment of a biventricular pacemaker is marked as recommended [13]. Optimal image quality of the vessels in MSCT is critically dependent on the ECG gating process and the choice of the optimal phase for reconstruction [12]. This problem was extensively studied in our earlier papers [11, 12].

For coronary arteries, evaluating image quality is usually performed on the basis of vessel length and free of motion artifacts [14]. In some papers, image quality has been assessed using a subjective five-point Likert scale [15]. In the presented paper, we use our own 0 to 5 points scale to evaluate the coronary venous system [12].

Visualization of coronary veins has been addressed in several papers. One of the first analyses was a comparison of 4-slice computed tomography and conventional angiography performed by Muhlenbruch et al. [16]. The authors used a four-point scale for each coronary vein: 0 = vein not visible, 3 = visible as smoothly bordered vascular structure. According to their results, the coronary sinus was usually the best visualized, while the lateral vein was the worst visualized. Another study by Abbara et al. [17] confirmed the possibility of high quality imaging of coronary veins by using 16-row computed tomography. They used a subjective ten-point scale (0 = vein not visible, 10 = excellent visualization) and additionally determined contrast-to-noise ratio. The coronary sinus was found to be the best visualized (9.4 ± 0.9 ; max. 10) while the lateral vein(s) were only moderately visualized (5.2 ± 2.3 ; max. 10). We cannot easily compare those results with the results obtained in our study, due to the use of different quality scales. Our study is one of the first on a 64-slice scanner to evaluate the image quality of the coronary venous system. The higher resolution and shorter time of examination mean that motion artifacts are less common. The inconsistent results of these studies are possibly due to the use of different scanners and lack of optimization for coronary venous system. The two studies found in common that:

1. It is possible to visualize the coronary venous system in MSCT.
2. The best image quality is usually for the coronary sinus.

The dosage of radiation in this type of examination is relatively high because of the need to scan both phases for coronary arteries with the highest quality, as well as coronary veins (retrospective gating). According to the latest thinking as to the potential long-term side effects of radiation exposure, the dosage of radiation should be balanced with image quality [18, 19], which might replicate into

an optimal cardiac resynchronization therapy systems implantation.

Successful coronary sinus cannulation depends to a greater extent on the operator's skills and experience than on the findings in MSCT. However, pre-visualization MSCT would change the procedure and/or the treatment strategies.

Limitations of the study

Most subjects included were examined because of a suspicion of coronary artery disease. They had for example a good ejection fraction, and there were only a few patients with advanced heart failure. Excluding patients with arrhythmias is a major limitation for MSCT per se, especially since frequent extrasystoles and atrial fibrillation are very common among patients with heart failure. The dose of radiation, as well as the amount of contrast agent used during examination, can sometimes be substantial. Many patients may require a beta-blocker to slow their heart rhythm, something which can be poorly tolerated, especially in patients with heart failure. Performing MSCT before cardiac resynchronization, as a standard test in all qualified patients, seems not to be entirely justified. Successful coronary sinus cannulation and selection of target veins is more based on the operator's skills, experience and available equipment than on the findings of MSCT. However, pre-procedural MSCT in selected cases (e.g. unsuccessful first cardiac resynchronization therapy implantation) would change the procedure and/or the treatment strategy.

Conclusions

It is possible to visualize the CVS in MSCT. The target veins for cardiac resynchronization — the lateral and the postero-lateral — are usually highly visible, something that increases the potential of MSCT.

Acknowledgments

The authors are indebted to the radiology technologists for their technical support.

The authors do not report any conflict of interest regarding this work.

References

1. Bristow MR, Feldman AM, Saxon LA. Heart failure management using implantable devices for ventricular resynchronization: Comparison of Medical Therapy, Pacing, and Defibrillation

- in Chronic Heart Failure (COMPANION) trial. COMPANION Steering Committee and COMPANION Clinical Investigators. *J Card Fail*, 2000; 6: 276–285.
2. Cleland JG, Daubert JC, Erdmann E et al. Longer-term effects of cardiac resynchronization therapy on mortality in heart failure [the Cardiac REsynchronization-Heart Failure (CARE-HF) trial extension phase]. *Eur Heart J*, 2006; 27: 1928–1932.
 3. Jeevanantham V, Zareba W, Navaneethan S et al. Metaanalysis on effects of cardiac resynchronization therapy in heart failure patients with narrow QRS complex. *Cardiol J*, 2008; 15: 230–236.
 4. Jeevanantham V, Daubert JP, Zareba W. Cardiac resynchronization therapy in heart failure patients: an update. *Cardiol J*, 2009; 16: 197–209.
 5. Behan MW, Rinaldi CA. Cardiac resynchronisation therapy for heart failure. *Int J Clin Pract*, 2006; 60: 1107–1114.
 6. Vaseghi M, Cesario DA, Ji S, Shannon KM et al. Beyond coronary sinus angiography: The value of coronary arteriography and identification of the pericardiophrenic vein during left ventricular lead placement. *Pacing Clin Electrophysiol*, 2005; 28: 185–190.
 7. Scholten MF, Szili-Torok T, Thornton AS, Roelandt JR, Jordaens LJ. Visualization of a coronary sinus valve using intracardiac echocardiography. *Eur J Echocardiogr*, 2004; 5: 93–96.
 8. Christiaens L, Ardilouze P, Ragot S, Mergy J, Allal J. Prospective evaluation of the anatomy of the coronary venous system using multidetector row computed tomography. *Int J Cardiol*, 2008; 126: 204–208.
 9. Jongbloed MR, Lamb HJ, Bax JJ et al. Noninvasive visualization of the cardiac venous system using multislice computed tomography. *J Am Coll Cardiol*, 2005; 45: 749–753.
 10. Van de Veire NR, Schuijf JD, De Sutter J et al. Non-invasive visualization of the cardiac venous system in coronary artery disease patients using 64-slice computed tomography. *J Am Coll Cardiol*, 2006; 48: 1832–1838.
 11. Mlynarski R, Sosnowski M, Wlodyka A, Kargul W, Tendera M. A user-friendly method of cardiac venous system visualization in 64-slice computed tomography. *Pacing Clin Electrophysiol*, 2009; 32: 323–329.
 12. Mlynarski R, Sosnowski M, Wlodyka A, Chromik K, Kargul W, Tendera M. Optimal image reconstruction intervals for noninvasive visualization of the cardiac venous system with a 64-slice computed tomography. *Int J Cardiovasc Imag*, 2009; 25: 635–641.
 13. Hendel RC, Patel MR, Kramer CM et al.; ACCF/ACR/SCCT/SCMR/ASNC/NASCI/SCAI/SIR 2006 appropriateness criteria for cardiac computed tomography and cardiac magnetic resonance imaging: A report of the American College of Cardiology Foundation Quality Strategic Directions Committee Appropriateness Criteria Working Group, American College of Radiology, Society of Cardiovascular Computed Tomography, Society for Cardiovascular Magnetic Resonance, American Society of Nuclear Cardiology, North American Society for Cardiac Imaging, Society for Cardiovascular Angiography and Interventions, and Society of Interventional Radiology. *J Am Coll Cardiol*, 2006; 48: 1475–1497.
 14. Dewey M, Teige F, Rutsch W, Schink T, Hamm B. CT coronary angiography: Influence of different cardiac reconstruction intervals on image quality and diagnostic accuracy. *Eur J Radiol*, 2008; 67: 92–99.
 15. Taupitz M, Schnorr J, Wagner S et al. Coronary magnetic resonance angiography: experimental evaluation of the new rapid clearance blood pool contrast medium P792. *Magn Reson Med*, 2001; 46: 932–938.
 16. Muhlenbruch G, Koos R, Wildberger JE, Gunther RW, Mahnken AH. Imaging of the cardiac venous system: comparison of MDCT and conventional angiography. *Am J Roentgenol*, 2005; 185: 1252–1257.
 17. Abbara S, Cury RC, Nieman K et al. Noninvasive evaluation of cardiac veins with 16-MDCT angiography. *Am J Roentgenol*, 2005; 185: 1001–1006.
 18. Schoenhagen P. Back to the future: coronary CT angiography using prospective ECG triggering. *Eur Heart J*, 2008; 29: 153–154.
 19. Einstein AJ, Henzlova MJ, Rajagopalan S. Estimating risk of cancer associated with radiation exposure from 64-slice computed tomography coronary angiography. *JAMA*, 2007; 298: 317–323.