

Intracoronary electrocardiogram ST segment shift evaluation during intravenous adenosine infusion: A comparison with fractional flow reserve

Vruyr Balian¹, Claudio Marcassa², Michele Galli³, Gianni Cecchin¹,
 Riccardo Michi¹, Marco Crenna¹, Ettore Petrucci¹, Marco Onofri¹

¹Cardiologia Interventistica Azienda Ospedaliera di Busto Arsizio, Varese, Italy

²Cardiology Division, Salvatore Maugeri Foundation IRCCS, Veruno Novara, Italy

³Mundipharma Pharm srl. Milan, Italy

Abstract

Background: *By measuring the pressure decline caused by coronary narrowing, fractional flow reserve (FFR) is an index of the physiological significance of a vessel stenosis. Intracoronary electrocardiogram (IC-ECG) recording from an angioplasty guidewire is more sensitive than standard ECG in detecting regional myocardial ischemia. The aim of the study was to assess if unipolar IC-ECG ST segment recording from angioplasty guidewire during maximal pharmacologic vasodilation could be used as an indirect estimation of FFR results.*

Methods: *Forty-eight clinically stable patients with intermediate stenosis underwent FFR evaluation and IC-ECG recording during intravenous adenosine infusion.*

Results: *FFR values were ≤ 0.80 in 26 (54%) patients and > 0.80 in 22 (46%). After adenosine, standard ECG was abnormal in only nine (19%) patients, while IC-ECG showed a significant ST segment shift (IST) in 24 (50%) patients: ST elevation in 19 patients and depression in five). IST was documented in 21/26 patients with $FFR \leq 0.80$ (81%) and in 3/22 with $FFR > 0.80$ ($p < 0.001$). Sensitivity of IST for predicting an abnormal FFR value was 81%, specificity 86%, positive and negative predictive accuracies were 88% and 79%, respectively.*

Conclusions: *Intracoronary ST segment shift evaluation during adenosine infusion may be of value in assessing the functional significance of a borderline stenosis. The presence of IST during adenosine infusion could obviate the need for additional FFR evaluation.* (Cardiol J 2011; 18, 6: 662–667)

Key words: angioplasty, electrocardiography, revascularization, adenosine

Introduction

Fractional flow reserve (FFR) is an index of the physiological significance of a coronary stenosis, and is defined as the ratio of maximal blood flow in a stenotic artery to normal maximal blood flow [1]. It can be measured by calculating the ratio of distal

coronary pressure, measured using a coronary pressure guidewire, to the aortic pressure simultaneously measured using the guiding catheter [2].

Unipolar intracoronary electrocardiogram (IC-ECG) recording from angioplasty guidewire represents local epicardial ECG and has been shown to be more sensitive and reliable in detecting re-

Address for correspondence: Vruyr Balian, MD, Cardiologia Interventistica Ospedale Busto Arsizio, P.zza Prof. Solaro N 3, 21052 Busto Arsizio (VA), Italy, tel: +39 0331 699 855, fax: +39 0331 699 856, e-mail: vbalian@aobusto.it

Received: 24.06.2011

Accepted: 09.08.2011

gional myocardial ischemia during balloon inflation than standard ECG [3].

We studied the diagnostic value of intracoronary ST segment recording during maximal pharmacological vasodilation in assessing the functional significance of a borderline coronary stenosis. With this aim, we recorded IC-ECGs in patients undergoing FFR evaluation during intravenous adenosine infusion and correlated the IC-ECG findings with FFR results.

Methods

Population

Forty-eight consecutive patients undergoing elective coronary angiography with single-vessel intermediate stenosis (40–70% diameter narrowing) on quantitative assessment were considered for this study. Men and women at least 18 years old were eligible for the study. Exclusion criteria included: prior ST segment elevation myocardial infarction, prior coronary revascularization, ostial stenosis, presence of left bundle branch block, non-sinus rhythm or paced rhythm in resting ECG and a contraindication to adenosine infusion. Patients who were taking digitalis or had ST/T wave abnormalities that precluded the interpretation of ischemic ECG were also excluded. Xantine derivatives and caffeine-containing products were discontinued 24 hours before procedure. Procedures were conducted using 6 or 7 Fr guide percutaneous coronary intervention (PCI) catheters without side-holes.

The study protocol was approved by the local Ethics Committee for Human Research. Informed consent was obtained from all patients.

Quantitative angiography

Angiography of the affected coronary artery was repeated in at least two orthogonal projections after intracoronary administration of 200 μ g of nitroglycerine, and quantitative assessment of the 'borderline' lesion was performed using an automated edge detection system (Quantification Software Package Philips Integris H5000 C). Lesion length, reference diameter, percentage stenosis and minimal lumen diameter were calculated as the mean of the values obtained from the two projections, using the guiding catheter as a scaling device.

Electrocardiographic recording and coronary pressure measurements

IC-ECG was recorded by connecting the proximal tip of the catheter guidewire (Hi-Torque Balance

MiddleWeight, Abbott Vascular, USA) by means of a sterile double-alligator connector to an unipolar chest lead terminal of a multichannel ECG recorder (MacLab 2000, Marquette Medical Systems) with a paper speed of 25 mm/s and 10 mm/mV signal amplitude. To provide an ECG recording of the area distally to the stenosis, proximal insulation of guidewire was accomplished by means of a microcatheter (Finecross, Terumo). After the guidewire passed the stenosis and was positioned distally in the culprit vessel, both surface 12 lead ECG and IC-ECG were recorded ('baseline ECG'). If the target lesion was located before a major vessel bifurcation, the guidewire tip was positioned in the major distal vessel.

After baseline IC-ECG recording, a 0.014-inch pressure monitoring guidewire (PressureWire Certus, Radi Medical Systems AB, Uppsala, Sweden) was calibrated and introduced into the guiding catheter. The wire was advanced up to the tip of the guiding catheter, where the pressure measured through the guiding catheter was verified to be equal to the pressure measured by the pressure wire. Next, the pressure wire was advanced into the coronary artery and positioned distally to the stenosis. Then, intravenous adenosine was administered at a rate of 140 μ g/kg/min through a central vein for 4 min until steady-state hyperemia was achieved. During maximal hyperemia, FFR was calculated as the ratio of the simultaneously recorded mean hyperemic distal coronary pressure to mean aortic pressure, as previously described [1]. A FFR value ≤ 0.80 was considered abnormal.

After FFR measurement, the pressure wire was removed from the guide catheter (to avoid any recording interference on IC-ECG). As soon as the pressure wire was removed, while adenosine infusion was not yet stopped, both surface 12 lead ECG and IC-ECG were obtained ('adenosine ECG'). Thereafter, adenosine infusion was stopped. Five minutes after it had ceased, both surface and IC-ECG were obtained ('recovery ECG').

Intracoronary and standard ECG analysis

Both standard and IC-ECG were analyzed by two observers unaware of FFR results. IC-ECG ST segment changes were measured 20 ms after the end of the QRS (or QS) complex by a lens-intensified hand-held caliper, approximated to the nearest 0.5 mm. The isoelectric line was considered the T-P segment preceding the QRS (or QS) complex. Three consecutive QRS complexes were analyzed, and mean ST shift values calculated.

Compared to baseline, an IC-ECG ST segment shift (elevation or depression) ≥ 1 mm during adenosine infusion was considered significant (IST). For surface ECG, an ischemic response was defined as either ≥ 1 mm flat or downsloping ST segment depression or ≥ 1.5 mm upsloping ST segment depression in two or more contiguous leads at 80 ms from the J point using the TP segment as the isoelectric reference in accordance with accepted guidelines [4].

Statistical analysis

Statistical analysis was performed using Stat-View, version 5.0 (SAS Institute, Cary, NC, USA). Normality of the data was verified by the Kolmogorov-Smirnov test. Continuous data was reported as mean \pm standard deviation. Student's t test for unpaired data was used to test differences between groups, and differences in rates of occurrence of categorical variables were compared by the χ^2 test with Yates' correction or Fisher's exact, when appropriate. All tests of significance were two-tailed, and a p value < 0.05 was considered significant.

Results

Between November 2009 and November 2010, 48 consecutive patients undergoing elective coronary angiography and with single-vessel intermediate stenosis on QCA assessment, were included in this study.

Demographic and clinical data of the study cohort is reported in Table 1. Abnormal FFR values were found in 26 (54%) and normal values in 22 (46%) patients. QCA and FFR data are reported in Table 2.

Electrocardiographic findings

During adenosine infusion, significant ECG changes (ST segment down-sloping) on standard ECG were documented in nine (19%) patients. On baseline IC-ECG recording, no patient showed ST segment elevation > 1 mm from the isoelectric line. During adenosine infusion, a significant IST was documented in 24 (50%) patients: ST segment elevation in 19 patients, ST depression in five other patients; examples of intracoronary ECG recordings are shown in Figure 1. IST had waned 5 min after the end of adenosine infusion in all patients.

Fractional flow reserve results

FFR values were ≤ 0.80 in 26 (54%) patients and > 0.80 in 24 (46%). IST was documented in 21 out of 26 patients (81%) with abnormal FFR, and

Table 1. Demographic, clinical and angiographic data of the study cohort.

Male sex	25 (52%)
Age	65 \pm 9
Current smoker	7 (15%)
Hypertension	31 (65%)
Dyslipidemia	12 (25%)
Diabetes	9 (19%)
Family history of CAD	16 (33%)
Angina:	
Stable	20 (42%)
Unstable IB*	3 (6%)
Unstable IIB*	25 (52%)
Vessel evaluated:	
Left anterior descending	27 (56%)
Left circumflex	13 (27%)
Right coronary artery	6 (13%)
Diagonal	2 (4%)

CAD — coronary artery disease; *according to the Braunwald classification [18]

Table 2. Angiographic and pressure wire data; values are presented as mean \pm SD.

Quantitative coronary angiographic findings:	
Extent of stenosis (%)	60.3 \pm 8.6
Minimal luminal diameter [mm]	1.11 \pm 0.38
Reference vessel diameter [mm]	2.77 \pm 0.55
Lesion length [mm]	9.9 \pm 5.1
Pressure wire data:	
Baseline Pd/Pa	0.92 \pm 0.06
Adenosine fractional flow reserve	0.77 \pm 0.12

in three out of 22 patients (14%) with normal FFR ($p < 0.001$).

Sensitivity of IST for predicting abnormal FFR was 81%, and specificity was 86%. Positive and negative predictive accuracies were 88% and 79%, respectively; the overall accuracy was 83%. Correlation between FFR values and IC ST segment shift is shown in Figure 2.

Discussion

In this preliminary experience, IC-ECG recording during maximal coronary vasodilation with intravenous adenosine turned out to be a reliable diagnostic tool to assess the functional significance of intermediate coronary stenoses.

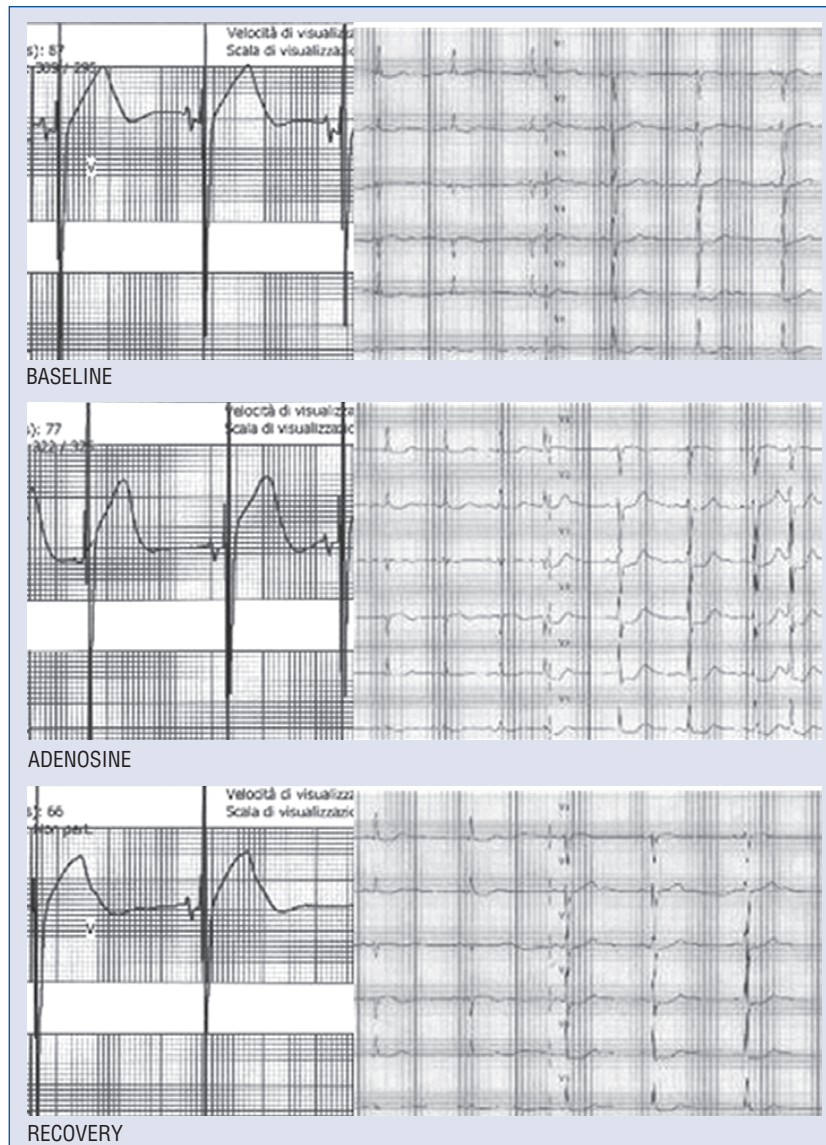


Figure 1. Example of ECG recording before adenosine infusion (baseline), during maximal hyperemia (adenosine), and 5 min after adenosine infusion end (recovery) in a patient with abnormal fractional flow reserve (FFR = 0.69). Intracoronary ECG (on left) and standard ECG (on right) are shown.

Ischemia reduction with coronary revascularization in stable patients may improve functional status and outcome as compared with optimal medical treatment [5].

According to current guidelines, PCI should be performed after having documented inducible ischemia [6]. Nevertheless, PCI of an intermediate stenosis is often performed in stable patients without prior noninvasive evidence of ischemia; the benefit of such intervention is largely unproven. Moreover, a recent retrospective analysis of 23,887 patients with stable coronary artery disease undergoing elective coronary angioplasty revealed that stress testing prior to the procedure (i.e. exercise

treadmill, stress echocardiography, or nuclear imaging) was performed in only 44% of patients [7]. This is clearly at odds with the recommendations provided by the guidelines, which call for the documentation of ischemia to indicate coronary angiography targeted to revascularization.

An angiogram cannot determine the physiological significance of a coronary stenosis, especially for an intermediate lesion (approximately 40 to 70% diameter narrowing). There is increasing evidence that PCI should be guided by physiological considerations and not only by the angiographic appearance of a stenosis. Coronary pressure derived FFR is a widely accepted invasive index to discriminate

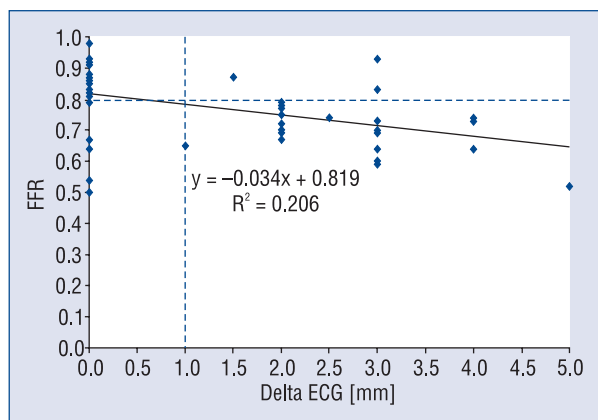


Figure 2. Linear regression between intracoronary ST segment shift and fractional flow reserve (FFR) values.

among intermediate stenoses those responsible for reversible ischemia and provides information complementary to the anatomic characterization of coronary disease at angiography. The appropriateness of stenting a functionally nonsignificant stenosis has been investigated, and excellent five-year outcome after deferral of PCI of an intermediate coronary stenosis based on $FFR \geq 0.75$ was documented by Pijls et al. [8]. Deferring PCI of stenotic lesions judged non-ischemic by FFR is associated with an annual rate of death or myocardial infarction (MI) of approximately 1% in patients with single-vessel coronary artery disease (CAD) [8]. Indeed, the chance of dying or experiencing an acute MI related to a functionally significant stenosis in a follow-up of five years is five times higher than for a stenosis of similar angiographic severity but which is not associated with reversible ischemia and is treated medically [8]. This strategy is valuable, even in the presence of multivessel CAD [9]. The FAME (Fractional Flow Reserve Versus Angiography for Multivessel Evaluation) study showed that routine measurement of FFR in addition to angiography in patients with multivessel CAD undergoing PCI with drug-eluting stents significantly reduces mortality and MI when compared with standard angiography-guided PCI, with favourable outcomes results maintained at two year follow-up [10]. Thus, the benefit of stenting these coincidental intermediate stenoses without a functional evaluation of them is questionable [9].

However, functional evaluation with a pressure wire of a coronary stenosis adds costs to the procedure. Moreover, pressure wire positioning can be cumbersome, particularly in tortuous and distal coronary segments.

Unipolar IC recording from the angioplasty catheter guidewire has been shown to be more sensitive and reliable in detecting regional myocardial ischemia during balloon inflation compared to standard ECG [3]. Intracoronary unipolar ECG reflects local electrical events arising from the myocardium near the guidewire tip and can be used to accurately detect peri PCI myocardial necrosis [11, 12]. At ECG recording during acute myocardial ischemia, the magnitude of the current of injury is influenced by the distance of the recording electrode from the region of ischemia; an electrode placed on the surface of the heart is more accurate than surface ECG leads in detecting ischemic ST segment changes [3, 11–13].

Although animal experiments do not suggest a simple quantitative relationship between epicardial ST segment elevation and regional myocardial blood flow following acute coronary artery occlusion, ST segment changes correlate with the magnitude of myocardial flow deprivation. Fifteen minutes after coronary artery occlusion, epicardial ST segment elevation was 5.7 ± 0.7 mV over the center of the infarct and myocardial blood flow was 10 ± 1 mL/min 100 g⁻¹; over the border zone; myocardial blood flow was 63 ± 4 mL/min 100 g⁻¹ and ST segment elevation was 3.1 ± 0.1 mV [14]. A linear relation was also found by Ruffy et al. [15] between the magnitude of ST segment shift and the endocardial/epicardial flow ratio.

Adenosine induces coronary vasodilatation via its effect on adenosine A2A receptors, creating flow disparities with increased blood flow to normal areas and reduced flow to areas distal to a significant coronary stenosis. As a potent coronary vasodilator, it may, however, promote blood flow diversion away from the territory subtended by a critically stenosed artery (coronary ‘steal’) [16]. In our study, 21 out of 26 patients showing abnormal FFR had IC ST segment shift during adenosine infusion.

There were several patients with discordant FFR and IC-ECG results. In particular, three out of 22 (14%) patients with normal FFR values showed IST during adenosine infusion. Indeed, the concept of FFR assumes that during maximal vasodilatation, myocardial resistance is minimal compared to the resistance related to the epicardial stenosis. This could not be the case in patients with significant impairment of vasodilator capacity. In these patients, microvascular disease, rather than epicardial stenosis, can be responsible for ST-segment depression during stressor infusion. In these patients, FFR may fail to measure the effects of the diffuse disease beyond the tip of the pressure-measuring device [2].

The FFR model assumes that under maximum arterial vasodilation, blood flow to the myocardium is proportional to the driving pressure (myocardial perfusion pressure). A FFR value < 0.75 is associated with inducible ischemia (reported specificity, 100%); on the contrary, a FFR value > 0.80 portends absence of inducible ischemia in the majority of patients (reported sensitivity, 90%) [1]. Five out of 26 (19%) patients had abnormal FFR values in the absence of IST. IST witnesses evolving myocardial ischemia, and this latter is not invariably present in the presence of FFR values < 0.80. It is worth noting that FFR measurements and IC-ECG recording were not performed simultaneously, and the latter was recorded a few seconds after removal of the pressure guidewire. On the other hand, FFR was assessed in the presence of an additional guidewire: this could affect FFR measurement decreasing the minimal luminal diameter, although an overestimation of the trans-lesional pressure gradient seems negligible [17]. Following Pijls et al. [10], we chose a FFR cut-off value of 0.80 as the gold standard for evaluating the accuracy of IC-ECG: the clinical significance of FFR values between 0.75 and 0.80 remains questionable [9].

According to this preliminary experience, the good overall accuracy (83%) of IST for predicting an abnormal FFR value could allow its use as a first step in the functional evaluation of a borderline stenosis in the cath lab. In the presence of IST during adenosine infusion, PCI could be carried out without further FFR evaluation.

Conclusions

Intracoronary ST segment shift evaluation during adenosine infusion may be of value in assessing the functional significance of a borderline stenosis. The presence of IC-ECG ST segment shift during adenosine infusion could obviate the need for additional FFR evaluation.

Acknowledgements

The authors do not report any conflict of interest regarding this work.

References

1. Pijls NH, De Bruyne B, Peels K et al. Measurement of fractional flow reserve to assess the functional severity of coronary-artery stenoses. *N Engl J Med*, 1996; 334: 1703–1708.
2. Pijls NH, Van Gelder B, Van der Voort P et al. Fractional flow reserve: a useful index to evaluate the influence of an epicardial coronary stenosis on myocardial blood flow. *Circulation*, 1995; 92: 3183–3193.
3. Friedman PL, Shook TL, Kirshenbaum JM, Selwyn AP, Ganz P. Value of the intracoronary electrocardiogram to monitor myocardial ischemia during percutaneous transluminal coronary angioplasty. *Circulation*, 1986; 74: 330–339.
4. Libby P, Bonow RO, Mann DL, Zipes DP, Braunwald E. Braunwald's heart disease: a textbook of cardiovascular medicine. 8th Ed. W.B. Saunders, Philadelphia 2008: 199–200.
5. Shaw LJ, Berman DS, Maron DJ et al.; for the COURAGE Investigators. Optimal medical therapy with or without percutaneous coronary intervention to reduce ischemic burden. Results from the Clinical Outcome Utilizing Revascularization and Aggressive Drug Evaluation (COURAGE) Trial Nuclear Substudy. *Circulation*, 2008; 117: 1283–1291.
6. Silber S, Albertsson P, Aviles FF et al. Guidelines for percutaneous coronary interventions. The Task Force for Percutaneous Coronary Interventions of the European Society of Cardiology. *Eur Heart J*, 2005; 26: 804–847.
7. Lin GA, Dudley RA, Lucas FL, Malenka DJ, Vittnghoff E, Redberg RF. Frequency of stress testing to document ischemia prior to elective percutaneous coronary intervention. *JAMA*, 2008; 300: 1765–1773.
8. Pijls NHJ, van Schaardenburgh P, Manoharan G et al. Percutaneous coronary intervention of functionally nonsignificant stenosis. 5-year follow-up of the DEFER Study. *J Am Coll Cardiol*, 2007; 49: 2105–2111.
9. Tonino PA, De Bruyne B, Pijls NHJ et al.; for the FAME Study Investigators. Fractional flow reserve versus angiography for guiding percutaneous coronary intervention. *N Engl J Med*, 2009; 360: 213–223.
10. Pijls NH, Fearon WF, Tonino PA et al.; FAME Study Investigators. Fractional flow reserve versus angiography for guiding percutaneous coronary intervention in patients with multivessel coronary artery disease: 2-year follow-up of the FAME (Fractional Flow Reserve Versus Angiography for Multivessel Evaluation) study. *J Am Coll Cardiol*, 2010; 56: 177–184.
11. Uetani T, Amano T, Kumagai S et al. Intracoronary electrocardiogram recording with a bare-wire system. *J Am Coll Cardiol Intv*, 2009; 2: 127–135.
12. Balian V, Galli M, Marcassa C et al. Intracoronary ST-segment shift soon after elective percutaneous coronary intervention accurately predicts periprocedural myocardial injury. *Circulation*, 2006; 114: 1948–1954.
13. Balian V, Galli M, Repetto S et al. Intracoronary ST segment evolution during primary coronary stenting predicts infarct zone recovery. *Cathet Cardiovasc Interv*, 2005; 64: 53–60.
14. Smith HJ, Singh BN, Norris RM, John MB, Hurley PJ. Changes in myocardial blood flow and S-T segment elevation following coronary artery occlusion in dogs. *Circ Res*, 1975; 36: 697–705.
15. Ruffy R, Lovelace DE, Mueller TM, Knoebel SB, Zipes DP. Relation between changes in bipolar electrograms and regional myocardial blood flow during acute coronary occlusion in the dog. *Circ Res*, 1979; 45: 764–770.
16. Straat E, Henriksson P, Edlund A. Adenosine provokes myocardial ischaemia in patients with ischaemic heart disease without increasing cardiac work. *J Intern Med*, 1991; 240: 319–323.
17. De Bruyne B, Pijls NH, Paulus WJ, Vantrimpont PJ, Sys SU, Heyndrickx GR. Transtenotic coronary pressure gradient measurement in humans: in vitro and in vivo evaluation of a new pressure monitoring angioplasty guide wire. *J Am Coll Cardiol*, 1993; 22: 119–126.
18. Braunwald E. Unstable angina: A classification. *Circulation*, 1989; 80: 410–414.