

Stereotactic irradiation of liver tumors – is it worthwhile?

Michał Kurzyński^{1, 2}, Marta Urbańska-Gąsiorowska², Marcin Hetnał^{1, 2}

¹Department of Oncology, Faculty of Medicine, Andrzej Frycz Modrzewski Krakow University, Krakow, Poland

²Amethyst Radiotherapy Centre, Ludwik Rydygier Memorial Hospital, Krakow, Poland

The standard treatment for metastatic liver lesions as well as primary tumors is surgery. Unfortunately, it is not always possible and other forms of local ablative treatment can be considered: radiofrequency ablation (RFA), microwave ablation (MWA), transarterial chemo embolisation (TACE), cryotherapy or stereotactic body radiation therapy (SBRT). SBRT is a highly focused radiation treatment that gives an intense dose of radiation concentrated on a tumor, while limiting the dose to the surrounding organs. SBRT is a non-invasive, short in duration (a few days of therapy) treatment which is feasible also for elderly and fragile patients. This review article presents the role of SBRT in the treatment of liver metastases and primary liver cancers.

Key words: stereotactic body radiation therapy, liver metastases, primary liver tumors, hepatocellular carcinoma, cholangiocarcinoma

Introduction

The role of radiotherapy in the treatment of liver lesions has increased significantly in recent years. For decades, this method was restricted to palliative treatment only [1]. This was due to the risk of damaging the liver parenchyma. The development of irradiation techniques has made it possible to deliver a high dose to the lesion, while reducing the dose to the healthy part of the organ. One of these methods is stereotactic ablative radiotherapy (SABR), also known as stereotactic body radiation therapy (SBRT). It is a highly focused local treatment that gives an intense dose of radiation concentrated on the tumor, while limiting the dose to the surrounding organs, leading to increased local lesion control rates with acceptable levels of toxicity.

This type of radiotherapy can be applied using a traditional linear accelerator, as well as modern devices such as CyberKnife or tomotherapy. It is commonly used for the treatment of lung lesions, brain tumors, or bone metastases. SBRT can also be delivered with a curative intent to primary liver tumors and liver metastases, which happens more often. For patients

diagnosed with liver metastases, the best treatment is surgery. The most common metastatic tumor in the liver has a colorectal adenocarcinoma origin [2]. It is due to direct drainage through the portal venous system.

The historical results show that surgical liver metastasectomy improves the overall survival (OS) with 1- and 5-year rates of 90–95% and 30–60%, respectively, with a median overall survival of 40–53 months [3]. Many patients are not candidates for such procedures due to tumor burden, multifocality, comorbidities, or poor general status. For these selected cases, other forms of local ablative treatment can be considered: radiofrequency ablation (RFA), microwave ablation (MWA), transarterial chemo embolisation (TACE), cryotherapy or SBRT [4]. In the case of primary malignancies, the most common tumors are hepatocellular carcinoma (HCC, 75–85%) and intrahepatic cholangiocarcinoma (10–15%) [5]. The problem is patients who are not eligible for hepatectomy with eventual liver transplantation [6]. In this case, other forms including radiotherapy are also to be

Jak cytować / How to cite:

Kurzyński M, Urbańska-Gąsiorowska M, Hetnał M. *Stereotactic irradiation of liver tumors – is it worthwhile?* NOWOTWORY J Oncol 2024; 74: 42–48.

considered. In the following publication, we outline the potential use of SBRT in the treatment of liver lesions.

SBRT for liver metastases

The incidence of liver metastases is increasing of which the most common primary tumor is colorectal cancer. According to Engstrand et al., liver metastases are diagnosed in 26.5% of patients within five years of the diagnosis of this malignancy [7]. Stereotactic radiotherapy is more commonly used for radiotherapy of liver metastases. This is related to the theory of metastatic disease, i.e., the existence of an intermediate form of cancer between localized and generalized forms – oligometastatic disease. This subgroup of patients could be described as patients with a limited number of metastases who could be aggressively treated using local modalities (surgery and/or radiation). That subgroup can be divided into two; one – synchronous metastases diagnosed at the same time and metachronic which occurred after a time interval [8]. It assumes the presence of a group of patients with quantifiable metastatic lesions in the lungs, brain, or liver.

According to the guidelines of the American Society of Clinical Oncology (ASCO) and the European Society for Medical Oncology (ESMO), surgery with/without perioperative systemic therapy is the first option of local therapy for metastatic liver tumors. All patients should be discussed with the multidisciplinary team (MDT). In patients with favorable factors: fewer metastases (<3 lesions), unilobar disease, no extrahepatic lesions, and metachronous lesions) upfront surgery (or another method of local therapy) should be performed [9–11].

Not all patients are eligible for surgical treatment, and possible induction chemotherapy to downsize the tumor may significantly worsen liver function [12]. Only 20–30% of liver-only metastases patients are potentially resectable. About 30–60% of patients survive 5 years after resection and varies between studies depending mostly on the radicality of the surgery and adjuvant therapy. Disease-free survival after 5 years reported is within the range of 4% and 47% (median 18%) with median postoperative mortality at 2.8% [13]. Rocca et al. in a systematic review showed that robotic surgery postoperative mortality was 0.4% with 3-year overall survival being 55% [14].

The alternative treatment options are the following: stereotactic body radiotherapy (SBRT), radiofrequency ablation,

microwave ablation, radiolabeled microspheres, transarterial chemo embolization, cryoablation, and alcohol injection [15]. There are no direct randomized trials comparing SBRT with these other forms of local treatment and all of them have advantages and limits. SBRT, because of its non-invasive nature and short treatment time, is a convenient therapy for elderly and fragile patients.

Stereotactic body radiotherapy and RFA were compared by Jackson et al. in a retrospective study showing 2-year FFLP (freedom from local progression) to be 88.2% and 73.9%, respectively ($p = 0.06$). For bigger tumors (≥ 2 cm in diameter), SBRT improved FFLP (HR, 0.28; 95% CI: 0.09–0.93) but not OS. On multivariate analysis, treatment with SBRT and a tumor diameter smaller than 2 cm were associated with improved local control. Grade ≥ 3 treatment-related toxicity was rare, with no difference between SBRT ($n = 4$) and RFA ($n = 3$) [16]. In another systematic review with meta-analyses comparing these two treatment forms, Lee et al. showed improved local control of SBRT compared to RFA (83.6% vs. 60%, $p < 0.001$) with no statistically significant difference in overall survival [17].

Patient selection

Imaging studies before a decision on the local treatment form should be based on a CT of the thorax, abdomen, and pelvis. Additionally, FDG-PET could be useful in defining the extent of metastatic disease. An MRI of the liver is also strongly suggested to assess the local extent or to exclude non-typical lesions in the liver [18]. The treatment method for metastatic liver lesions should be made as part of a multidisciplinary team. Only patients with adequate liver function can be candidates for treatment. Unfortunately, only a few patients qualify for surgery. For SBRT the following issues should be considered:

- number of metastases,
- size,
- distance from organs at risk (OARs), and
- laboratory parameters of the liver.

Indications are shown in table I.

Candidates for SBRT are oligometastatic patients with a good performance status (Eastern Cooperative Oncology Group 0–2), extra-hepatic disease should be controlled (absent

Table I. Patient qualification to SBRT according to Comito et al. [19].

Indicated	Borderline	Contra-indicated
number of hepatic lesions ≤ 3	patients with 4 liver metastases	patients with ≥ 5 hepatic lesions
size lesions ≤ 3 cm	diameter >3 and ≤ 6 cm	diameter >6 cm
OARs distance >8 mm	OARs distance >5 and ≤ 8 mm	OARs distance ≤ 5 mm
good liver function (Child-Pugh A)	moderate liver function (Child-Pugh B)	inadequate liver function (Child-Pugh C)
free liver volume >1000 cm ³	free liver ≥ 700 and <1000 cm ³	free liver volume <700 cm ³

or suitable for local treatment). Histopathology should not be an inclusion nor exclusion factor. The age of the patient is not a selection factor. SBRT is well tolerated by elderly patients who are unsuitable for surgery [19].

SBRT planning

Stereotactic body radiotherapy of metastatic lesions can be performed on conventional linear accelerators and other devices such as CyberKnife or tomotherapy. The treatment involves administering several doses of irradiation precisely to the lesion area while sparing the healthy tissue, which is an excellent alternative for patients who do not qualify for invasive treatment methods.

The recommended doses vary in the available publications. The total dose, the fractional dose, which are planned to be administered depends on the number of lesions, the volume of the healthy liver (total liver volume minus cumulative gross tumor volume [GTV]) and the dose given to the critical organs such as kidneys, stomach, bowel, spinal cord (OARs) [20]. As a result, this technique also has its limitations. This also applies to lesions that are large in size and close to the organs at risk such as the bile ducts or large blood vessels. In the available publications, doses ranged from 14 to 70 Gy given in 1–10 fractions. The respiratory mobility of the liver should be taken into account when planning radiotherapy. It may use a variety of methods such as gating, tumor tracking or abdominal compression. Another important element of treatment planning is the establishment of fiducial markers [21]. Implantation of fiducial markers into the liver metastases or near the lesion helps by patient set-up and online treatment verification (fig. 1).

Results and toxicity

To date, there is a lack of randomized studies comparing SBRT with other forms of local treatment (RFA, MWA) or comparing it with other radiation modalities or fractionation. There are several prospective studies or retrospective case series which have shown promising OS and LC results with mild toxicity. The results of some of them are presented in table II.

One year OS after SBRT in reported studies is higher than 56% in all studies and it reaches a level above 80% in two of them. Among treated patients, local control ranges from 60–95% at 1 year and 45–90% at 2 years. The publications

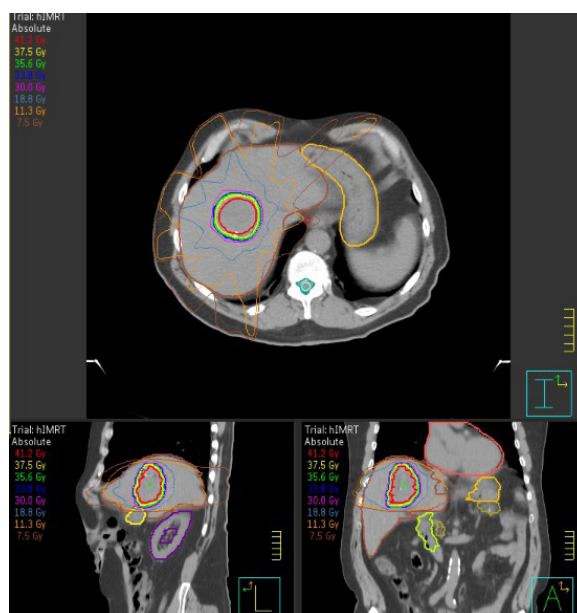


Figure 1. Images from the radiotherapy planning system

Table II. Characteristics of studies

Author, year [ref.]	Type of study	Number of patients	Number of lesions	Dose Gy/fx (fractions)	Follow-up – median (range)	Overall survival	Local control	Toxicity
Scorsetti et al., 2018 [21]	prospective	61	1–3 (<6 cm)	52.5–75 Gy/3 fx	24	1 y – 85.0%; 2 y – 31.1%	1 y – 95%; 2 y – 78%	G3 – 1%
Joo et al., 2017 [22]	retrospective	70	1–2 (lesion size – 2.9 cm)	45–60/3–4 fx	34.2	2 y – 75%	1 y – 93%; 2 y – 68%	G3 – 0
Hoyer et al., 2006 [23]	prospective	64	lesion size – 3.5 cm	45/3 fx	52	1 y – 67%; 2 y – 38%	2 y – 86%	1 patient – liver failure
Chang et al., 2011 [24]	retrospective	65	1–2	22–60/1–6 fx	14	1 y – 72%; 2 y – 38%	1 y – 62%; 2 y – 45%	G3 – 3 patients
Berber et al., 2013 (Cyberknife) [25]	retrospective	53	1–6	43/3 fx	17	1 y – 56%	1 y – 60%	1 patient – death
Lee et al., 2009 [26]	retrospective	40	1–8 (mean 2)	27.7–60/6 fx	10.8	18 months – 47%	1 y – 71%	G3 – 9%, G4 – 1% ^a
Bodreau et al., 2023 (stereotactic MR-guided radiotherapy) [27]	prospective	26	1–2	40–60/5 fx	17	1 y – 83.1%; 2 y – 41.6%	1 y – 90%; 2 y – 90%	G1–2 – 34%; G3 – 0

Gy – gray; Fx – fraction; ^a – thrombocytopenia

listed in the table concerned patients with liver metastases from various cancers, while the majority were from colorectal cancer. Several studies have evaluated potential prognostic factors for local control with SBRT for liver metastases.

Smaller tumors and those receiving a higher dose along with motion management methods have been associated with better local control. Mutations of p53 and KRAS detected among patients suffering from colon cancer are associated with lower local control [28]. Data regarding the impact of histology on LC are ambiguous [29]. Moreover, the German Society of Radiation Oncology database trial showed that liver metastases from breast cancer are more radioresistant than other histologies [30]. Studies have also shown that a higher dose of radiation therapy is associated with better outcomes. A biological equivalent dose (BED) could be an independent prognostic factor of local control [22].

Joo et al. showed that BED₁₀ 80 Gy or less is associated with 2 year LC 52%, BED₁₀ 100–112 Gy with 83% and BED₁₀ 132 Gy or more with 2 years LC 89% [22]. This means that the higher the dose of radiotherapy given, the better the local control achieved.

Overall, SBRT of metastatic liver lesions is well tolerated. It is a non-invasive treatment form and can be offered to elderly patients [19]. The most common complications (mainly G1–2) are:

- fatigue,
- nausea,
- lack of appetite,
- gastritis, or
- transiently increased levels of hepatic transaminase which normalize within 3 months of treatment.

The most serious complications (G3–4) are:

- perforation of a colonic or duodenal ulceration demanding surgery,
- musculoskeletal discomfort, or
- radiotherapy-induced liver failure.

SBRT as a treatment for primary tumors of the liver

Hepatocellular carcinoma (HCC) is the most common primary pathological diagnosis for liver cancer patients, and is the fourth cause of cancer death globally with a dismal prognosis [31]. The treatment of choice is surgery (hepatic resection or transplantation). According to Japanese data, only 38% of patients qualify for surgery [32]. Depending on the stage of the disease, the patient's general status and liver function, either a resection of the lesion or liver transplantation is the standard of care. Other local methods used for treatment include radiofrequency ablation and transarterial chemoembolisation. According to the guidelines of the American Society of Radiation Oncology (ASTRO) radiotherapy is an option for patients with unresectable and inoperable HCC both as EBRT and SBRT [33]. Stereotactic body radiotherapy can be used as a radical treatment and could be helpful for patients awaiting liver transplantation or be used as a palliative treatment. The continuous develop-

ment of radiotherapy techniques and imaging methods for liver lesions has enabled more precise radiotherapy treatment. Most publications on SBRT of HCC are retrospective studies of a relatively small group of patients.

Radical treatment of HCC

The results of SBRT treatment were presented in a meta-analysis by Rim et al. in which 32 publications assessing 1950 patients were included [34]. Pooled 1-, 2-, and 3-year OS rates were 72.6%, 57.8%, and 48.3%, respectively. Good LC was also demonstrated: 1-, 2-, and 3-year LC rates were 85.7%, 83.6%, and 83.9%, respectively. The subgroup analysis showed that tumor size was the most important prognostic factor. This prognostic factor has also been proven in similar studies [35, 36]. Additionally, tumor vascular invasion (TVI) was considered a negative prognostic factor. This condition is also associated with an increased risk of developing portal vein thrombosis. The meta-analysis also showed that radiation dose escalation does not significantly impact OS and LC [34]. Similar results were obtained by Ohri et al. [37].

Reported SBRT dose is 30–50 Gy in 3–5 fractions [39, 40], according to ASTRO the recommended dose starts from 50–60 Gy in 3–5 fractions, with more scheduled in case of higher burden of the disease [32]. When prescribing the dose of radiotherapy, the number of lesions, their size, distance from the OARs, liver function (e.g. Child-Turcotte-Pugh class) should be taken into account [40, 41]. Guidelines also suggest modern techniques such as SBRT, dynamic techniques such as arc therapy, proton therapy with respiratory motion management with daily imaging. Treatment tolerance is very good and hepatic or gastrointestinal complications >3 grade appeared in <5% of the patients in nearly every publication [42–46]. Rajyaguru et al. in a retrospective study that analyzed 3980 nonsurgically managed patients with stage I or II HCC compared SBRT with radiofrequency ablation (RFA). After propensity matching, 5-year overall survival was 29.8% in the RFA group *versus* 19.3% in the SBRT [45]. Another study comparing SBRT with RFA retrospectively was by Nalee et al., showing similar results [46].

On the other hand, Sapir et al. compared SBRT *versus* TACE showing statistically a significant beneficial effect of SBRT on 1 and 2 year LC (97% and 91% vs. 47% and 23%, respectively). The grade 3 toxicity rate was higher with TACE (13%) than SBRT [47].

According to the National Comprehensive Cancer Network (NCCN) guidelines, radiotherapy along with ablation and arterially directed therapies are valid treatment options for non-resectable patients (without recommendation, one treatment over another due to the lack of randomized controlled trials with a comparison between these methods) [48]. Referring to ASTRO guidelines, in patients with liver-only HCC with incomplete response to thermal ablation or catheter-based therapies, EBRT is recommended as a consolidative treatment option [33].

Bridge therapy and downstaging therapy of HCC

Bridge therapy is used in patients qualified for liver transplant. It is used to prevent tumor progression while the patient awaits a liver transplantation. Various methods of local treatment of liver tumors may be used: RFA, MWA, TACE or SBRT [34]. Kulik et al. showed that the forms of local treatment mentioned above do not significantly improve post-transplantation mortality or overall survival, compared to transplants alone [49]. Bridge therapy is mainly used in centers with long waiting times for liver transplantation. Downstaging therapy is used to reduce the size of the tumor so that the patient can fulfil the Milan criteria [50] for surgery with liver transplantation [51].

SBRT for cholangiocarcinoma

The second most common liver tumor is cholangiocarcinoma (CCC). It is highly malignant with an extremely poor diagnosis – 70% of patients have an inoperable tumor [52] and 50% of patients relapse within one year after surgery [53]. Radiotherapy (EBRT) is mainly used as a neoadjuvant, therapy after a successful operation or palliative treatment. The role of SBRT is poorly investigated and is an alternative to surgery or other local treatments. Gkika et al. showed in a retrospective study that SBRT of CCC reached 1 year OS: 56% with a median OS of 14 months from the start of SBRT and 22 months from diagnosis. Median progression-free survival (PFS) was 9 months [54]. Similar results have been achieved in other studies: Sandler et al. – 1 year LC: 78%, median OS – 15.7 months [55]; Tse et al. – 1 year LC: 65%, median OS – 15 months [56]. The toxicity of the SBRT was acceptable, with the main severe complications being bleeding. It should be mentioned that classical fractionation is recommended in an adjuvant setting and in combination with systemic treatment.

Conclusions

Here we have presented the role of SBRT in the treatment of tumors of the liver – either metastases or primary malignancies. Stereotactic body radiotherapy is increasingly popular for the treatment of all malignancies due to its short treatment time and acceptable level of toxicity. In addition, it is used for patients who are often ineligible for surgery. With the development of radiotherapy, new equipment (e.g. CyberKnife, MRI-guided radiotherapy) is making the treatment more and more precise. However, there are still many concerns about the dose of radiotherapy, patient selection and combination with systemic or immune therapies. Importantly, any decision regarding treatment should be determined by a multi-specialist team.

Article information and declarations

Author contributions

Michał Kurzyński – conceptualization, methodology, writing original draft, resources.

Marta Urbańska-Gąsiorowska – visualization, supervision.

Marcin Hetnał – visualization, supervision, resources.

Conflict of interest

None declared

Michał Kurzyński

Ludwik Rydygier Memorial Hospital

Amethyst Radiotherapy Centre

Osiedle Złotej Jesieni 1

31-826 Kraków, Poland

e-mail: m.kurzynski@amethyst-rtcp.pl

Received: 10 Oct 2023

Accepted: 21 Jan 2024

References

1. Hawkins MA, Dawson LA. Radiation therapy for hepatocellular carcinoma: from palliation to cure. *Cancer*. 2006; 106(8): 1653–1663, doi: 10.1002/cncr.21811, indexed in Pubmed: 16541431.
2. Kemeny NE, Ron IG. Liver Metastases. *Curr Treat Options Gastroenterol*. 1999; 2(1): 49–57, doi: 10.1007/s11938-999-0018-1, indexed in Pubmed: 11096572.
3. Comito T, Clerici E, Tozzi A, et al. Liver metastases and SBRT: A new paradigm? *Rep Pract Oncol Radiother*. 2015; 20(6): 464–471, doi: 10.1016/j.rpor.2014.10.002, indexed in Pubmed: 26696787.
4. de Jong KP. Review article: Multimodality treatment of liver metastases increases suitability for surgical treatment. *Aliment Pharmacol Ther*. 2007; 26 Suppl 2: 161–169, doi: 10.1111/j.1365-2036.2007.03484.x, indexed in Pubmed: 18081659.
5. Chen W, Chiang CL, Dawson LA. Efficacy and safety of radiotherapy for primary liver cancer. *Chin Clin Oncol*. 2021; 10(1): 9, doi: 10.21037/cco-20-89, indexed in Pubmed: 32576017.
6. Smoter P, Kotulski M, Smoter K, et al. Liver transplantation in primary liver tumors. *Nowotwory. Journal of Oncology*. 2023; 73(4): 248–254, doi: 10.5603/njo.95859.
7. Hellman S, Weichselbaum RR. Oligometastases. *J Clin Oncol*. 1995; 13(1): 8–10, doi: 10.1200/jco.1995.13.1.8, indexed in Pubmed: 7799047.
8. Martin J, Petrillo A, Smyth EC, et al. Colorectal liver metastases: Current management and future perspectives. *World J Clin Oncol*. 2020; 11(10): 761–808, doi: 10.5306/wjco.v11.i10.761, indexed in Pubmed: 33200074.
9. Cervantes A, Adam R, Roselló S, et al. ESMO Guidelines Committee. Electronic address: clinicalguidelines@esmo.org. Metastatic colorectal cancer: ESMO Clinical Practice Guideline for diagnosis, treatment and follow-up. *Ann Oncol*. 2023; 34(1): 10–32, doi: 10.1016/j.anonc.2022.10.003, indexed in Pubmed: 36307056.
10. Morris VK, Kennedy EB, Baxter NN, et al. Treatment of Metastatic Colorectal Cancer: ASCO Guideline. *J Clin Oncol*. 2023; 41(3): 678–700, doi: 10.1200/JCO.22.01690, indexed in Pubmed: 36252154.
11. Leonard GD, Brenner B, Kemeny NE. Neoadjuvant chemotherapy before liver resection for patients with unresectable liver metastases from colorectal carcinoma. *J Clin Oncol*. 2005; 23(9): 2038–2048, doi: 10.1200/JCO.2005.00.349, indexed in Pubmed: 15774795.
12. Simmonds PC, Primrose JN, Colquitt JL, et al. Surgical resection of hepatic metastases from colorectal cancer: a systematic review of published studies. *Br J Cancer*. 2006; 94(7): 982–999, doi: 10.1038/sj.bjc.6603033, indexed in Pubmed: 16538219.
13. Rocca A, Scacchi A, Cappuccio M, et al. Robotic surgery for colorectal liver metastases resection: A systematic review. *Int J Med Robot*. 2021; 17(6): e2330, doi: 10.1002/rcs.2330, indexed in Pubmed: 34498805.
14. Mahadevan A, Blanck O, Lanciano R, et al. Stereotactic Body Radiotherapy (SBRT) for liver metastasis - clinical outcomes from the international multi-institutional RSSearch® Patient Registry. *Radiat Oncol*. 2018; 13(1): 26, doi: 10.1186/s13014-018-0969-2, indexed in Pubmed: 29439707.
15. Jackson WC, Tao Y, Mendiratta-Lala M, et al. Comparison of Stereotactic Body Radiation Therapy and Radiofrequency Ablation in the Treatment of Intrahepatic Metastases. *Int J Radiat Oncol Biol Phys*. 2018; 100(4): 950–958, doi: 10.1016/j.ijrobp.2017.12.014, indexed in Pubmed: 29485074.
16. Lee J, Shin IS, Yoon WS, et al. Comparisons between radiofrequency ablation and stereotactic body radiotherapy for liver malignancies:

- Meta-analyses and a systematic review. *Radiother Oncol.* 2020; 145: 63–70, doi: 10.1016/j.radonc.2019.12.004, indexed in Pubmed: 31923711.
17. Almuhaideb A, Papathanasiou N, Bomanji J. 18F-FDG PET/CT Imaging In Oncology. *Ann Saudi Med.* 2011; 31(1): 3–13, doi: 10.4103/0256-4947.75771, indexed in Pubmed: 21245592.
 18. Comito T, Clerici E, Tozzi A, et al. Liver metastases and SBRT: A new paradigm? *Rep Pract Oncol Radiother.* 2015; 20(6): 464–471, doi: 10.1016/j.rpor.2014.10.002, indexed in Pubmed: 26696787.
 19. Dawson LA, Winter KA, Katz AW, et al. NRG Oncology/RTOG 0438: A Phase 1 Trial of Highly Conformal Radiation Therapy for Liver Metastases. *Pract Radiat Oncol.* 2019; 9(4): e386–e393, doi: 10.1016/j.prro.2019.02.013, indexed in Pubmed: 30825666.
 20. Stick LB, Vogelius IR, Risum S, et al. Intrafractional fiducial marker position variations in stereotactic liver radiotherapy during voluntary deep inspiration breath-hold. *Br J Radiol.* 2020; 93(1116): 20200859, doi: 10.1259/bjr.20200859, indexed in Pubmed: 32915653.
 21. Scorsetti M, Arcangeli S, Tozzi A, et al. Is stereotactic body radiation therapy an attractive option for unresectable liver metastases? A preliminary report from a phase 2 trial. *Int J Radiat Oncol Biol Phys.* 2013; 86(2): 336–342, doi: 10.1016/j.ijrobp.2012.12.021, indexed in Pubmed: 23433800.
 22. Joo JH, Park JH, Kim JC, et al. Local Control Outcomes Using Stereotactic Body Radiation Therapy for Liver Metastases From Colorectal Cancer. *Int J Radiat Oncol Biol Phys.* 2017; 99(4): 876–883, doi: 10.1016/j.ijrobp.2017.07.030, indexed in Pubmed: 29063852.
 23. Hoyer M, Roed H, Traberg Hansen A, et al. Phase II study on stereotactic body radiotherapy of colorectal metastases. *Acta Oncol.* 2006; 45(7): 823–830, doi: 10.1080/02841860600904854, indexed in Pubmed: 16982546.
 24. Chang DT, Swaminath A, Kozak M, et al. Stereotactic body radiotherapy for colorectal liver metastases: a pooled analysis. *Cancer.* 2011; 117(17): 4060–4069; Erratum in: *Cancer.* 2012; 118(10): 2776, doi: 10.1002/cncr.25997, indexed in Pubmed: 21432842.
 25. Berber B, Ibarra R, Snyder L, et al. Multicentre results of stereotactic body radiotherapy for secondary liver tumours. *HPB (Oxford).* 2013; 15(11): 851–857, doi: 10.1111/hpb.12044, indexed in Pubmed: 23458468.
 26. Lee MT, Kim JJ, Dinniwel R, et al. Phase I study of individualized stereotactic body radiotherapy of liver metastases. *J Clin Oncol.* 2009; 27(10): 1585–1591, doi: 10.1200/JCO.2008.20.0600, indexed in Pubmed: 19255313.
 27. Bordeau K, Michalet M, Keskes A, et al. Stereotactic MR-Guided Radiotherapy for Liver Metastases: First Results of the Montpellier Prospective Registry Study. *J Clin Med.* 2023; 12(3), doi: 10.3390/jcm12031183, indexed in Pubmed: 36769831.
 28. Jethwa KR, Jang S, Mullikin TC, et al. Association of tumor genomic factors and efficacy for metastasis-directed stereotactic body radiotherapy for oligometastatic colorectal cancer. *Radiother Oncol.* 2020; 146: 29–36, doi: 10.1016/j.radonc.2020.02.008, indexed in Pubmed: 32114263.
 29. Ahmed KA, Caudell JJ, El-Haddad G, et al. Radiosensitivity Differences Between Liver Metastases Based on Primary Histology Suggest Implications for Clinical Outcomes After Stereotactic Body Radiation Therapy. *Int J Radiat Oncol Biol Phys.* 2016; 95(5): 1399–1404, doi: 10.1016/j.ijrobp.2016.03.050, indexed in Pubmed: 27319288.
 30. Klement RJ, Guckenberger M, Alheid H, et al. Stereotactic body radiotherapy for oligo-metastatic liver disease - Influence of pre-treatment chemotherapy and histology on local tumor control. *Radiother Oncol.* 2017; 123(2): 227–233, doi: 10.1016/j.radonc.2017.01.013, indexed in Pubmed: 28274491.
 31. Roberts HJ, Wo JY. Stereotactic body radiation therapy for primary liver tumors: An effective liver-directed therapy in the toolbox. *Cancer.* 2022; 128(5): 956–965, doi: 10.1002/cncr.34033, indexed in Pubmed: 34847255.
 32. Kudo M, Izumi N, Kubo S, et al. Report of the 20th Nationwide follow-up survey of primary liver cancer in Japan. *Hepatol Res.* 2020; 50(1): 15–46, doi: 10.1111/hepr.13438, indexed in Pubmed: 31655492.
 33. Apisarnthanarax S, Barry A, Cao M, et al. External Beam Radiation Therapy for Primary Liver Cancers: An ASTRO Clinical Practice Guideline. *Pract Radiat Oncol.* 2022; 12(1): 28–51, doi: 10.1016/j.prro.2021.09.004, indexed in Pubmed: 34688956.
 34. Rim CH, Kim HJu, Seong J. Clinical feasibility and efficacy of stereotactic body radiotherapy for hepatocellular carcinoma: A systematic review and meta-analysis of observational studies. *Radiother Oncol.* 2019; 131: 135–144, doi: 10.1016/j.radonc.2018.12.005, indexed in Pubmed: 30773180.
 35. Belghiti J, Panis Y, Farges O, et al. Intrahepatic recurrence after resection of hepatocellular carcinoma complicating cirrhosis. *Ann Surg.* 1991; 214(2): 114–117, doi: 10.1097/0000658-199108000-00004, indexed in Pubmed: 1714267.
 36. Lai EC, Ng IO, Ng MM, et al. Long-term results of resection for large hepatocellular carcinoma: a multivariate analysis of clinicopathological features. *Hepatology.* 1990; 11(5): 815–818, doi: 10.1002/hep.1840110516, indexed in Pubmed: 2161393.
 37. Ohri N, Tomé WA, Méndez Romero A, et al. Local Control After Stereotactic Body Radiation Therapy for Liver Tumors. *Int J Radiat Oncol Biol Phys.* 2021; 110(1): 188–195, doi: 10.1016/j.ijrobp.2017.12.288, indexed in Pubmed: 29395629.
 38. Hong TS, Wo JY, Yeap BY, et al. Multi-Institutional Phase II Study of High-Dose Hypofractionated Proton Beam Therapy in Patients With Localized, Unresectable Hepatocellular Carcinoma and Intrahepatic Cholangiocarcinoma. *J Clin Oncol.* 2016; 34(5): 460–468, doi: 10.1200/JCO.2015.64.2710, indexed in Pubmed: 26668346.
 39. Seong J, Lee IKJ, Shim SuJ, et al. A multicenter retrospective cohort study of practice patterns and clinical outcome on radiotherapy for hepatocellular carcinoma in Korea. *Liver Int.* 2009; 29(2): 147–152, doi: 10.1111/j.1478-3231.2008.01873.x, indexed in Pubmed: 18795897.
 40. Andolino DL, Johnson CS, Maluccio M, et al. Stereotactic body radiotherapy for primary hepatocellular carcinoma. *Int J Radiat Oncol Biol Phys.* 2011; 81(4): e447–e453, doi: 10.1016/j.ijrobp.2011.04.011, indexed in Pubmed: 21645977.
 41. Bujold A, Massey CA, Kim JJ, et al. Sequential phase I and II trials of stereotactic body radiotherapy for locally advanced hepatocellular carcinoma. *J Clin Oncol.* 2013; 31(13): 1631–1639, doi: 10.1200/JCO.2012.44.1659, indexed in Pubmed: 23547075.
 42. Qiu H, Moravan MJ, Milano MT, et al. SBRT for Hepatocellular Carcinoma: 8-Year Experience from a Regional Transplant Center. *J Gastrointest Cancer.* 2018; 49(4): 463–469, doi: 10.1007/s12029-017-9990-1, indexed in Pubmed: 28710606.
 43. Hijazi H, Campeau MP, Roberge D, et al. Stereotactic Body Radiotherapy for Inoperable Liver Tumors: Results of a Single Institutional Experience. *Cureus.* 2016; 8(12): e935, doi: 10.7759/cureus.935, indexed in Pubmed: 28123916.
 44. Liu HY, Lee Y, McLean K, et al. Efficacy and Toxicity of Stereotactic Body Radiotherapy for Early to Advanced Stage Hepatocellular Carcinoma - Initial Experience From an Australian Liver Cancer Service. *Clin Oncol (R Coll Radiol).* 2020; 32(10): e194–e202, doi: 10.1016/j.clon.2020.04.004, indexed in Pubmed: 32345457.
 45. Rajyaguru DJ, Borgert AJ, Smith AL, et al. Radiofrequency Ablation Versus Stereotactic Body Radiotherapy for Localized Hepatocellular Carcinoma in Nonsurgically Managed Patients: Analysis of the National Cancer Database. *J Clin Oncol.* 2018; 36(6): 600–608, doi: 10.1200/JCO.2017.75.3228, indexed in Pubmed: 29328861.
 46. Kim N, Kim HJu, Won JY, et al. Retrospective analysis of stereotactic body radiation therapy efficacy over radiofrequency ablation for hepatocellular carcinoma. *Radiother Oncol.* 2019; 131: 81–87, doi: 10.1016/j.radonc.2018.12.013, indexed in Pubmed: 30773192.
 47. Sapir E, Tao Y, Schipper MJ, et al. Stereotactic Body Radiation Therapy as an Alternative to Transarterial Chemoembolization for Hepatocellular Carcinoma. *Int J Radiat Oncol Biol Phys.* 2018; 100(1): 122–130, doi: 10.1016/j.ijrobp.2017.09.001, indexed in Pubmed: 29066120.
 48. NCCN guidelines; Hepatobiliary Cancers; access 20.09.2023.
 49. Kulik L, Heimbach JK, Zaiem F, et al. Therapies for patients with hepatocellular carcinoma awaiting liver transplantation: A systematic review and meta-analysis. *Hepatology.* 2018; 67(1): 381–400, doi: 10.1002/hep.29485, indexed in Pubmed: 28859222.
 50. Mazzaferro V, Regalia E, Doci R, et al. Liver transplantation for the treatment of small hepatocellular carcinomas in patients with cirrhosis. *N Engl J Med.* 1996; 334(11): 693–699, doi: 10.1056/NEJM199603143341104, indexed in Pubmed: 8594428.
 51. Toso C, Mentha G, Kneteman NM, et al. The place of downstaging for hepatocellular carcinoma. *J Hepatol.* 2010; 52(6): 930–936, doi: 10.1016/j.jhep.2009.12.032, indexed in Pubmed: 20385428.
 52. Khan SA, Davidson BR, Goldin RD, et al. British Society of Gastroenterology. Guidelines for the diagnosis and treatment of cholangiocarcinoma: an update. *Gut.* 2012; 61(12): 1657–1669, doi: 10.1136/gutjnl-2011-301748, indexed in Pubmed: 22895392.
 53. Simo KA, Halpin LE, McBrier NM, et al. Multimodality treatment of intrahepatic cholangiocarcinoma: A review. *J Surg Oncol.* 2016; 113(1): 62–83, doi: 10.1002/jso.24093, indexed in Pubmed: 26797780.
 54. Gkika E, Hallauer L, Kirste S, et al. Stereotactic body radiotherapy (SBRT) for locally advanced intrahepatic and extrahepatic cholangiocarcinoma. *BMC Cancer.* 2017; 17(1): 781, doi: 10.1186/s12885-017-3788-1, indexed in Pubmed: 29162055.

55. Sandler KA, Veruttipong D, Agopian VG, et al. Stereotactic body radiotherapy (SBRT) for locally advanced extrahepatic and intrahepatic cholangiocarcinoma. *Adv Radiat Oncol.* 2016; 1(4): 237–243, doi: 10.1016/j.adro.2016.10.008, indexed in Pubmed: 28740893.
56. Tse RV, Hawkins M, Lockwood G, et al. Phase I study of individualized stereotactic body radiotherapy for hepatocellular carcinoma and intrahepatic cholangiocarcinoma. *J Clin Oncol.* 2008; 26(4): 657–664; Erratum in *J Clin Oncol.* 2008; 26 (23): 3911–3912, doi: 10.1200/JCO.2007.14.3529, indexed in Pubmed: 18172187.