

## External hemipelvectomy. A last resort operation

Leszek Kołodziejcki<sup>1,2</sup>, Józef Duber<sup>1</sup>, Piotr Pomykacz<sup>1</sup>, Andrzej L. Komorowski<sup>3,4</sup>

<sup>1</sup>Saint Luke's Hospital, Tarnow, Poland

<sup>2</sup>University of Applied Sciences, Tarnow, Poland

<sup>3</sup>University of Rzeszow, Rzeszow, Poland

<sup>4</sup>Department of General Surgery, Edmund Biernacki Specialist Hospital, Mielec, Poland

An external hemipelvectomy (hindquarter amputation) is a major mutilating amputation that includes the lower extremity and half of the pelvic rim. It is rarely performed due to its mutilating character and the technical difficulties involved. The main indications for the operation include sarcomas and extensive trauma. In this paper, the authors discuss the historical aspects and current status of this rare operation, as well as its role in the oncological approach to sarcomas.

**Key words:** sarcoma, hemipelvectomy, hindquarter amputation

### Introduction

An external hemipelvectomy is considered to be one of the most mutilating operations in surgery. The indications for an operation where the lower extremity and half of the pelvis is amputated include bone sarcoma, soft tissue sarcoma, and trauma [1–4]. The highly mutilating character of the operation together with crucial technical difficulties as well as the resulting high morbidity and mortality all account for the infamy of this surgical approach [4–6]. All too common is a situation where the decision to perform an external hemipelvectomy is postponed virtually until the last moment, when all other treatment methods prove futile and the pain of the cancer has become unbearable [7, 8]. This treatment philosophy unfortunately leads to many patients being disqualified from surgery as the metastatic foci become apparent [9]. In this article, the authors present the indications for external hemipelvectomy and the surgical technique involved.

### The history of the surgical approach

The first attempt at amputation of the lower extremity with half of the pelvic rim was performed by Theodore Billroth in 1891 in Vienna. Unfortunately, the patient died a few hours after

surgery was completed. In addition, the second operation, performed by Mathieu Jaboulay in Lyon in 1893, also ended with the death of the patient [8]. Since Jaboulay – contrary to Billroth – published the description of his case, some surgeons suggest that an external hemipelvectomy should be referred to as a “Jaboulay operation” [10]. From the available literature we know that of the first 6 operations of this type, all resulted in the death of the patient in matter of hours or days [10]. The first patient to survive an external hemipelvectomy was operated on in 1895 in Geneva by Charles Girard [11]. The technical approach to the external hemipelvectomy was established in 1916 by James Hogarth Pringle from Glasgow. Pringle's description constitutes the technical basis for the latter modifications of the technique. The various modifications differ from Pringle's approach mainly in the manner in which the large defect is dealt with, while the resection part remains almost unchanged [11].

### Indications

The indication for an external hemipelvectomy have remained mostly intact for the last 120 years. It should be considered in cases of large bone or soft tissue sarcomas located within

---

#### Jak cytować / How to cite:

Kołodziejcki L, Duber J, Pomykacz P, Komorowski AL. *External hemipelvectomy. A last resort operation.* NOWOTWORY J Oncol 2023; 73: 81–84.

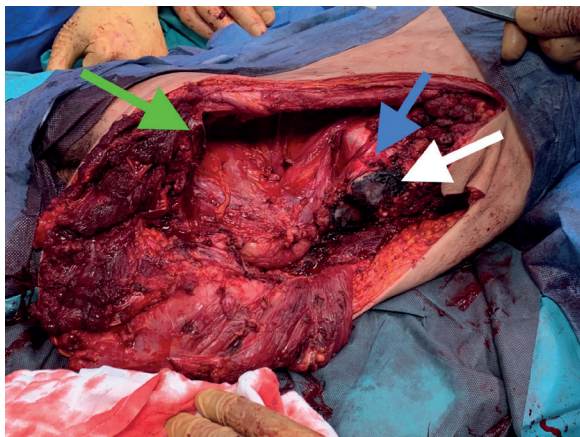
the pelvic rim [4]. It is also considered for crash trauma patients in which the destruction of the pelvis makes it impossible to spare elements of the pelvic rim. [12, 13]. Historically, the large tuberculous involvement of the pelvis was also considered to be an indication for an external hemipelvectomy. Of the first 21 cases described in the literature from 1889 to 1909, 18 were performed for sarcomas and three for tuberculosis [10].

The most common cancers that may require performing an external hemipelvectomy are: chondrosarcoma, Ewing sarcoma, plasmocytoma, and osteosarcoma [8]. All the above cited cancers are rare [14]. Moreover, only a fraction of these cancers develop within the pelvic rim, e.g. 7% of all osteosarcomas [8]. Finally, a big proportion of these patients can be qualified for smaller, limb preserving resections. In a series by Pieńkowski et al., it was possible in 53 consecutive pelvic chondrosarcoma patients [15]. If we add to this data the fact that some of those patients are disqualified from surgery due to the stage of the disease and general performance, it becomes clear why an external hemipelvectomy is one of the rarest surgical operations performed nowadays.

### Technique

Currently there are two approaches to a hemipelvectomy, namely an external and internal hemipelvectomy. The introduction of advanced prosthetic materials and techniques in the last decades of the 20<sup>th</sup> century created the possibility of performing a resection on part of the pelvic rim without the need to undertake a lower extremity amputation. This approach is called an internal hemipelvectomy [8]. While being obviously less mutilating than the classic external hemipelvectomy, its use is limited to patients without involvement of the thigh.

In an external hemipelvectomy, the dissection starts in the anterior wall of the abdomen, and dissection aims at conserving the peritoneum intact while respecting the “no touch: and *en bloc* rules for cancer surgery. The urinary bladder, peritoneum, fascia, kidney, and urethra are exposed (fig. 1).



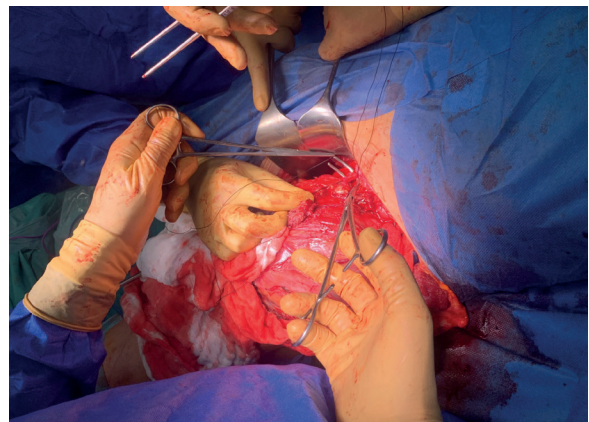**Figure 1.** Full exposition of the operative field after resection: the green arrow points to the cut left pubic bone; the blue arrow points to the promontorium, with the left urethra seen on its surface; the white arrow points to the cut surface of the sacral bone

The pubic bone is resected within or very close to the symphysis pubis. The dissection of the sacro-iliac connections is made with the posterior approach. This element is required for the operation to be classified as an external hemipelvectomy [16]. If required, lateral vertebral processes of the lumbar spine are resected. Common iliac vessels are closed and sutured with transfixing sutures (fig. 2). Depending on how much surrounding tissue was spared during the operation (which in turn is a function of direct involvement of the cancer tissue), the defect is closed in a manner chosen by the operating surgeon. If not infiltrated, the following muscles can be used to form musculo-cutaneous flaps to cover the defect: abdominal muscles (rectus, obliques), thigh flexors, quadriceps, gluteus.

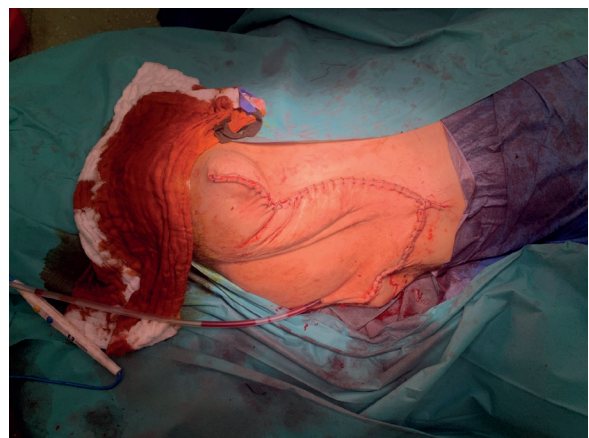
The final surgical specimen includes half of the pelvis and lower extremity. The defect is covered depending on the formerly prepared flaps (fig. 3). Although the extent of mutilation is important, patients are able to proceed with their personal and professional life after the operation and dedicated physiotherapy.

### Discussion

It is quite difficult to standardize such a rare operation as the external hemipelvectomy. In a recent meta-analysis, only 5 studies of 183 patients were found to compare the results



**Figure 2.** Transfixing sutures of the left common artery. The specimen can be seen to the left of the picture



**Figure 3.** The final view of the operative field after flap closure

of internal and external hemipelvectomies over a span of 35 years [17]. The majority of even high volume cancer hospitals do not have significant numbers of these operations. The reasons for this phenomena are three-fold: the rarity of the tumors, the existence of other, less mutilating techniques, and usually a late diagnosis. The patient, whose operation can be seen on the photographs included in this article, was diagnosed with gigantocellular bone tumor only 2 years after the first pain symptoms in his groin area. Indeed, the pain is present in almost all patients with pelvic sarcoma – it was the main symptom of all 40 patients in a Dutch series from 1978–1995 [1]. After resection of the tumor with hip replacement, he started the physiotherapy only to be diagnosed with G3 fibroblastic osteosarcoma of the previously operated area. He was qualified for AP3 cisplatin and doxorubicin systemic therapy, apparently with palliative intent [1]. During chemotherapy, the patient suffered further progression of the tumor which reached dimensions of 141 x 109 x 163 mm without the evidence of distant metastasis. Judged marginally operable, the patient had to desperately look for a center willing to perform the surgery and due to uncontrollable pain, was willing to undergo any mutilation needed, including the placement of fecal and urinary diversion if required. The operation was performed after neoadjuvant volumetric modulated arc therapy (VMAT) radiotherapy 25 Gy in 5 fractions [18]. The postoperative course was uneventful, the histopathology report confirmed the R0 resection, and 3 months after the operation the patient started to work as a professional driver using an automatic gear box.

Radical operation, i.e., R0 resection, is fundamental for the long-term survival of patients undergoing a resection for pelvic sarcoma [1, 3, 5, 19]. In the case presented on the illustration, the main technical difficulty was to obtain free margins from the spinal side. In order to maximize the possibility of R0 resection, preoperative radiotherapy was undertaken [20] with the use of the VMAT technique [18]. During surgery, a resection of the spinal L3 and L4 processes as well as part of the sacral bone was required. This part of the operation resulted in the highest intraoperative blood loss that was evaluated at 2l during an 8 hour surgery.

According to authors from the Mayo Clinic, neoadjuvant chemo and radiotherapy allows better than expected local and distant control of the bone sarcoma of the extremities. [20].

The importance of the technical aspects of the hemipelvectomy was analyzed in possibly the biggest series of hemipelvectomies from the same center. Over a 20-year period (1985–2005), 160 hemipelvectomies were performed in the Mayo Clinic. Almost half of the patients (45%) received radiotherapy and similarly 46% underwent chemotherapy. The mean operation time was 6.4 hours and the mean number of blood units transfused was 13.4. Intraoperative mortality was 5%. Complications with the flap was present in 26% of patients and wound infection in 39%. The main factors influencing local

complications were operation durations exceeding 7.3 hours and the need to close the common iliac vessels [6, 9, 21].

In a personal series by Miller, who performed 100 hemipelvectomies between 1946–1972, all patients had their common iliac vessels cut and closed. It did not, however, influence the healing process of the large posterior flap, similarly to our case [22].

Interestingly, in the patient seen on the images, the malnutrition (BMI 14.2) did not result in perioperative complications. The patient was able to be sent home with primary healed wounds two weeks after surgery, compared to the 26 and 27 days reported by Senchenkov and Bohm [6, 23].

Since the patient suffered significant pain before the operation, once the surgery was completed he was eager to restart physical activity. Also, even with a partial resection of the lumbar plexus, he did not suffer any bowel or urinary control problems. The emotional element must be stressed. A willingness to undergo a very mutilating surgery was definitely an important factor in influencing his quick recovery [3, 24, 25].

It is difficult to evaluate the prospect for long term survival of a patient with advanced bone sarcoma requiring an external hemipelvectomy, even after R0 resection, since long follow-up is relatively low [23, 26]. The vast majority of patients die as a result of massive metastasis to the lungs [1–3].

## Conclusions

The external hemipelvectomy is a rarely performed mutilating operation. In selected cases it is the last resort, and, as such, should be taken into consideration for patients who have been disqualified from other forms of radical treatment.

**Conflict of interest:** none declared

**Andrzej L. Komorowski**

University of Rzeszów  
ul. Kopisto 2a  
35-959 Rzeszów, Poland  
e-mail: z5komoro@cyf-kr.edu.pl

Received: 9 Mar 2023

Accepted: 5 Apr 2023

## References

1. Ham SJ, Kroon HM, Koops HS, et al. Osteosarcoma of the pelvis-oncological results of 40 patients registered by The Netherland Committee of Bone Tumors. *Eur J Surg Oncol.* 2000; 26(1): 53–60, doi: 10.1053/ejso.1999.0741, indexed in Pubmed: 10718181.
2. Prewitt TW, Alexander HR, Sindelar WF. Hemipelvectomy for soft tissue sarcoma: clinical results in fifty-three patients. *Surg Oncol.* 1995; 4(5): 261–269, doi: 10.1016/s0960-7404(10)80005-2, indexed in Pubmed: 8850028.
3. Wirbel RJ, Schulte M, Mutschler WE. Surgical treatment of pelvic sarcomas: oncologic and functional outcome. *Clin Orthop Relat Res.* 2001(390): 190–205, doi: 10.1097/00003086-200109000-00022, indexed in Pubmed: 11550866.
4. Lewis V, Kemp A, Roubaud M, et al. Multidisciplinary Approach to Hemipelvectomy for Pelvic Sarcomas. *JBJS Reviews.* 2022; 10(5), doi: 10.2106/jbjs.rvw.20.00233.

5. Han I, Lee YM, Cho HS, et al. Outcome after surgical treatment of pelvic sarcomas. *Clin Orthop Surg.* 2010; 2(3): 160–166, doi: 10.4055/cios.2010.2.3.160, indexed in Pubmed: 20808587.
6. Senchenkov A, Moran SL, Petty PM, et al. Predictors of Complication and Outcomes of External Hemipelvectomy Wounds: Account of 160 Consecutive Cases. *Ann Surg Oncol.* 2008; 15(1): 355–363, doi: 10.1245/s10434-007-9672-5, indexed in Pubmed: 17955297.
7. Higinbotham NL, Marcove RC, Casson P. Hemipelvectomy: a clinical study of 100 cases with 5-year-followup on 60 patients. *Surgery.* 1996; 59(5): 706–708, indexed in Pubmed: 5219626.
8. Wedemeyer C, Kauther MD. Hemipelvectomy- only a salvage therapy? *Orthop Rev (Pavia).* 2011; 3(1): e4, doi: 10.4081/or.2011.e4, indexed in Pubmed: 21808716.
9. Apffelstaedt JP, Driscoll DL, Spellman JE, et al. Complications and outcome of external hemipelvectomy in the management of pelvic tumors. *Ann Surg Oncol.* 1996; 3(3): 304–309, doi: 10.1007/BF02306287, indexed in Pubmed: 8726187.
10. Pringle JH. Some notes on the interpelvi-abdominal amputation, with a report of three cases. *Lancet.* 1909; 173: 530–533.
11. Mat Saad AZ, Halim AS, Faisham WI, et al. Soft tissue reconstruction following hemipelvectomy: eight-year experience and literature review. *ScientificWorldJournal.* 2012; 2012: 702904, doi: 10.1100/2012/702904, indexed in Pubmed: 22629187.
12. Patch DA, Hess MC, Spittler CA, et al. Diagnosis and Management of Traumatic Hemipelvectomy. *J Am Acad Orthop Surg.* 2022; 30(18): 888–895, doi: 10.5435/JAAOS-D-21-01018, indexed in Pubmed: 36166384.
13. He Yu, Qiu D, Zhou D, et al. Treatment of Partial Traumatic Hemipelvectomy: A Study of 21 Cases. *J Bone Joint Surg Am.* 2019; 101(9): e36, doi: 10.2106/JBJS.18.00877, indexed in Pubmed: 31045672.
14. Fromm J, Klein A, Baur-Melnyk A, et al. Survival and prognostic factors in conventional central chondrosarcoma. *BMC Cancer.* 2018; 18(1): 849, doi: 10.1186/s12885-018-4741-7, indexed in Pubmed: 30143018.
15. Pieńkowski A, Komor A, Goryń T, et al. The outcomes of limb-sparing surgery of patients with chondrosarcoma of the pelvis. *Nowotwory J Oncol.* 2021; 71(6): 336–342, doi: 10.5603/NJO.2021.0071.
16. COLEY BL, HIGINBOTHAM NL, ROMIEU C. Hemipelvectomy for tumors of bone; report of fourteen cases. *Am J Surg.* 1951; 82(1): 27–43, doi: 10.1016/0002-9610(51)90294-2, indexed in Pubmed: 14838216.
17. Banskota N, Yang H, Fang X, et al. Comparative study of pelvic sarcoma patients undergoing internal and external hemipelvectomy: A meta-analysis study. *Front Surg.* 2022; 9: 988331, doi: 10.3389/fsurg.2022.988331, indexed in Pubmed: 36311928.
18. Spalek MJ, Poleszczuk J, Czarnecka AM, et al. Radiotherapy in the Management of Pediatric and Adult Osteosarcomas: A Multi-Institutional Cohort Analysis. *Cells.* 2021; 10(2), doi: 10.3390/cells10020366, indexed in Pubmed: 33578676.
19. Mayerson JL, Wooldridge AN, Scharschmidt TJ. Pelvic resection: current concepts. *J Am Acad Orthop Surg.* 2014; 22(4): 214–222, doi: 10.5435/JAAOS-22-04-214, indexed in Pubmed: 24668351.
20. Machak GN, Tkachev SI, Solovyev YN, et al. Neoadjuvant chemotherapy and local radiotherapy for high-grade osteosarcoma of the extremities. *Mayo Clin Proc.* 2003; 78(2): 147–155, doi: 10.4065/78.2.147, indexed in Pubmed: 12583525.
21. Baliski CR, Schachar NS, McKinnon JG, et al. Hemipelvectomy: a changing perspective for a rare procedure. *Can J Surg.* 2004; 47(2): 99–103, indexed in Pubmed: 15132462.
22. Miller TR. 100 cases of hemipelvectomy: a personal experience. *Surg Clin North Am.* 1974; 54(4): 905–913, doi: 10.1016/s0039-6109(16)40396-8, indexed in Pubmed: 4428322.
23. Bohm P. Hemipelvectomy: report of 12 cases, review of the literature and therapeutic implications. *J Orthop Sci.* 1997; 2: 414–423.
24. Sayeed MdS, Oakman J, Dillon MP, et al. Influential factors for access to and participation in rehabilitation for people with lower limb amputation in East, South, and Southeast Asian developing countries: a scoping review. *Disabil Rehabil.* 2022; 44(25): 8094–8109, doi: 10.1080/09638288.2021.1994025, indexed in Pubmed: 34719308.
25. Gavrankapetanovic I, Gavrankapetanovic F, Becirbegovic S, et al. [Hemipelvectomy, constant surgical dilemma]. *Rozhl Chir.* 2007; 86(12): 661–665, indexed in Pubmed: 18303780.
26. Vander Griend RA. Osteosarcoma of the pelvis. A clinical and histopathological study of 25 patients. *J Bone Joint Surg Am.* 1992; 74: 321–330.