

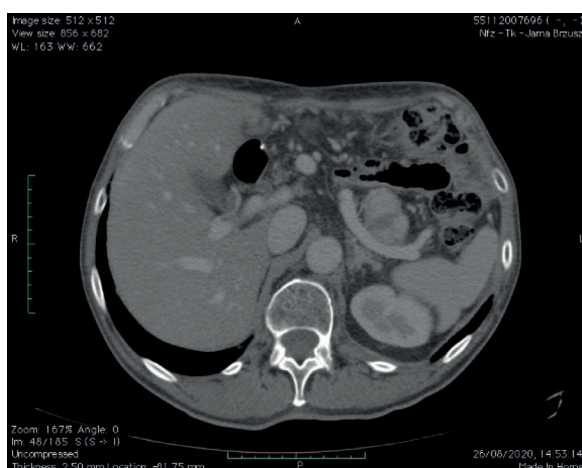
## Peritoneal recurrence of RCC and gastric cancer treated with cytoreductive surgery and HIPEC

Tomasz Jastrzębski<sup>1,2</sup>, Marian Brodecki<sup>2</sup>, Michał Spychalski<sup>2</sup>, Tomasz Sylwestrzak<sup>1</sup>, Adam Dzikowski<sup>2,3</sup>

<sup>1</sup>Surgical Oncology Department, Medical University of Gdansk, Gdansk, Poland

<sup>2</sup>Surgical Oncology Department, District Health Centre Hospital, Brzeziny, Poland

<sup>3</sup>General and Colorectal Surgery Department, Medical University in Lodz, Lodz, Poland



**Figure 1.** A CT scan of a gastric stump tumor

A 65-year-old male patient was admitted to the surgical oncology clinic after an examination in August 2020 revealed 10 mm ulceration in the gastric stump (fig. 1); earlier, on 1<sup>st</sup> Feb 2019, a subtotal gastric resection was performed due to a gastric adenocarcinoma. A histopathological examination revealed cancer cells in 4 out of 10 of the removed lymph nodes, the margins – R0. The patient did not qualified for adjuvant therapy after the surgery, but was qualified for another surgical procedure and HIPEC in a clinical center accredited by the surgical associations after considering the non-radical character of the previous gastric surgery [1]. During the

surgery on 16<sup>th</sup> Sep 2020 on the gastric stump, the intestinal loop, pancreas tail, part of the pancreas body, the spleen and tumor were removed. Cisplatin was administered. PCI was 2 points and the procedure was macroscopically radical – CC-0. The histopathological examination revealed high grade adenocarcinoma in the gastric stump with the obstruction of the lymphatic vessels. Renal clear cell carcinoma presence was confirmed in the spleen and pancreas area. Furthermore, there were renal cancer cells in the splenic vessels and pancreas tail vessels. The radiological examination from March 2021 did not show any signs of cancer recurrence. It may be the first record describing treatment of recurrent renal cancer with HIPEC. This example suggests that in some cases of metastatic RCC in the abdominal cavity, it is worth considering, further research on the subject due to the known fact of HIPEC being an effective solution in different cases of neoplasms [2] and lack of trials in that specific matter.

### References

1. Jastrzębski T, Richter P, Zegarski W, et al. Guidelines from the Polish Surgical Society and Polish Society of Oncological Surgery Concerning Quality Assurance for Centres Performing Cytoreductive Procedures and HIPEC Procedures in the Treatment of Primary and Secondary Peritoneal Tumours. *Nowotwory J Oncol.* 2020; 70(3): 85–91, doi: 10.5603/njo.2020.0019.
2. Verwaal VJ, van Ruth S, de Bree E, et al. Randomized trial of cytoreduction and hyperthermic intraperitoneal chemotherapy versus systemic chemotherapy and palliative surgery in patients with peritoneal carcinomatosis of colorectal cancer. *J Clin Oncol.* 2003; 21(20): 3737–3743, doi: 10.1200/JCO.2003.04.187, indexed in Pubmed: 14551293.

### Jak cytować / How to cite:

Jastrzębski T, Brodecki M, Spychalski M, Sylwestrzak T, Dzikowski A. *Peritoneal recurrence of RCC and gastric cancer treated with cytoreductive surgery and HIPEC.* *NOWOTWORY J Oncol* 2022; 72: 201.