

A change in the approach to pancreatic head cancer resection?

Marek Olakowski

Department of Gastrointestinal Surgery, Medical University of Silesia, Katowice, Poland

In recent years, we have seen an improvement in the outcome of pancreatic cancer treatment. This is due to a change in the approach to both adjuvant and surgical treatment. Recent advances in systemic treatment, such as the use of FOLFIRINOX regimens (5-fluorouracil, leucovorin, irinotecan, oxaliplatin) and gemcitabine plus nab-paclitaxel, as well as the optimization of local treatment, e.g., stereotactic body radiation therapy (SBRT), have led to an increase in the proportion of patients where a resection is possible. This is especially true for the subgroup of patients with borderline resectable tumors [1].

Moreover, modifications have been made to surgical treatment. These are due to the fact that the status of the mesenteric head resection margin (R0-none vs. R1-present tumor cells in the resection margin) is a strong predictor of survival after resection of pancreatic head adenocarcinoma (PHC) [2].

Therefore, a more radical approach has been proposed for the final stage of the pancreatoduodenectomy (PD) performed for PHC. In classical PD, the final stage of the resection part of the procedure (fig. 1) is to ligate and cut the small vessels running between the pancreatic uncinatum process and the superior mesenteric vein (SMV) and the superior mesenteric artery (SMA). Elements of connective tissue, lymph nodes, and nerve plexuses in this area that may be infiltrated by cancer cells are also removed. However, the cutting plane between the pancreas and the mesenteric vessels follows the right edge of the SMV and portal vein [3].

The final stage of PHC resection, performed as described above, is currently controversial for many surgeons. There have been opinions that guiding the cutting plane on the right side of the SMV and portal vein does not allow a complete resection

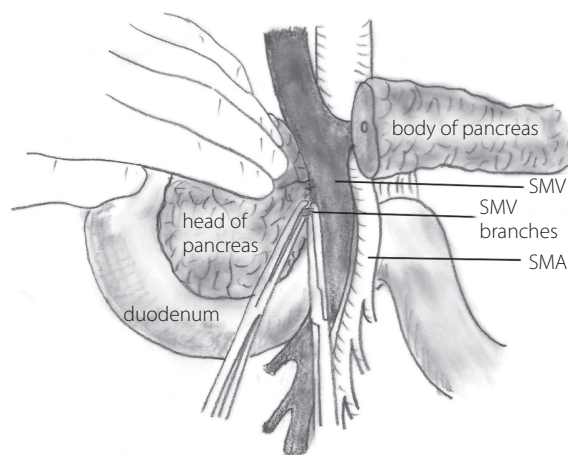


Figure 1. The final step of the dissection requires isolation, division, and ligation of the vascular supply and retroperitoneal attachments at the head of the pancreas. The venous tributaries to the superior mesenteric vein (SMV) are readily identified by retracting the pancreatic head gently to the right and the vein to the left. SMA – superior mesenteric artery [3] (author's modification)

of the tissues located in the space between the left edge of the pancreatic head and the SMA, called the mesopancreas. This space contains fatty tissue, nerve plexuses and ganglia, blood and lymph vessels, and lymph nodes. Moreover, this space has no fibrous capsule or fascia, making it invisible and very difficult to identify during surgery [4].

In 2015, Japanese surgeons proposed that the extent of mesopancreas excision should be divided into 3 levels depending on the type of tumor (fig. 2). In the first, the preparation plane is on the right side of the SMV. The nerve plexuses around the

Jak cytować / How to cite:

Olakowski M. *A change in the approach to pancreatic head cancer resection?* NOWOTWORY J Oncol 2021; 71: 418–419.

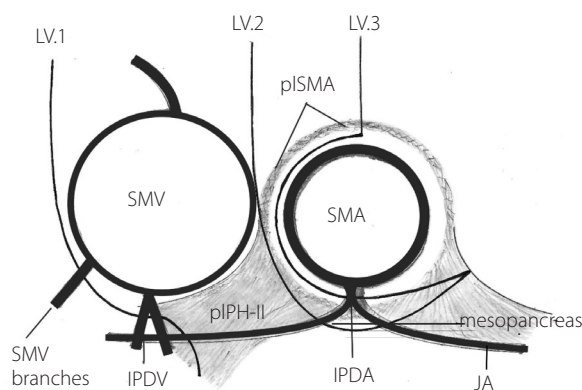


Figure 2. The anatomy and concept of systematic mesopancreas dissection using the supracolic anterior approach [5]. The dissection lines of each dissection level are indicated (own modification). LV.1 – level 1: simple mesopancreas division without lymph node (LN) dissection; LV.2 – level 2: *en bloc* LNs dissection in the mesopancreas by the central vessel ligation technique; LV.3 – level 3: *en bloc* mesopancreas resection with right hemicircumferential pI-SMA dissection for invasive pancreatic head tumor; IPDA – inferior pancreaticoduodenal artery; IPDV – inferior pancreaticoduodenal vein; JA – jejunal artery; pI-SMA – nerve plexus around the SMA; pIPH-II – second nerve plexuses of the pancreas head; SMA – superior mesenteric artery; SMV – superior mesenteric vein

SMA (pI-SMA), the small arterial and venous branches running to the intestine and the entire mesojejunum are preserved. The indication for level 1 resection is that no lymph nodes need to be resected, which is the case for tumors of low malignancy (carcinoma in situ, pancreatic metastases or tumor cysts). At level 2, the mesopancreas is excised in its entirety together with the lymph nodes, plexuses and ganglion (pIPH-I) located on the right side of the visceral trunk (VT), with the inferior pancreaticoduodenal artery ligated at the outlet. The line of preparation is on the right side of the SMA, but its periarterial nerve plexus is left intact (pIPH-II). The indications for resection at level II are tumors of the papilla of Vater, the distal bile duct, and the duodenum. At level 3, the preparation plane of the SMA is moved even further to the left, so that *en bloc* with the entire mesopancreas, the periarterial nerve plexus (pIPH-II) on its right side is additionally removed in an area of approximately 180 degrees of vessel circumference. This plane of resection is dedicated to ductal carcinoma of the pancreas or locally advanced bile duct cancer [5].

Recently, many surgeons have introduced several advanced modifications of the PD technique in order to improve the distant results of PHC treatment by shifting the pancreatic cut-off to the SMA-VT axis, e.g., “artery first”, “processus uncinatus first”, triangle operation, periarterial divestment [6].

Whether shifting the cutting plane from the right side of the superior mesenteric vein to the SMA-VT axis improves the distant results of PHC treatment will be seen in the future after randomized clinical trials have been completed. This does not change the fact that, despite significant advances in multimodal treatment, the search for the optimal technique for PHC resection is still needed.

Conflict of interest: none declared

Marek Olakowski
 Medical University of Silesia
 Department of Gastrointestinal Surgery
 ul. Medyków 14
 40-752 Katowice, Poland
 e-mail: olakom@me.com

Received: 12 Sep 2021

Accepted: 24 Sep 2021

References

1. Piątek M, Nawrocki S. Locally advanced pancreatic cancer — new therapeutic challenges. *Nowotwory. Journal of Oncology*. 2016; 66(4): 312–316, doi: 10.5603/njo.2016.0059.
2. Maeda S, Moore AM, Yohanathan L, et al. Impact of resection margin status on survival in pancreatic cancer patients after neoadjuvant treatment and pancreaticoduodenectomy. *Surgery*. 2020; 167(5): 803–811, doi: 10.1016/j.surg.2019.12.008, indexed in Pubmed: 31992444.
3. Warshaw AL, Thayer SP. Pancreaticoduodenectomy. *J Gastrointest Surg*. 2004; 8(6): 733–741, doi: 10.1016/j.gassur.2004.03.005, indexed in Pubmed: 15358336.
4. Gockel I, Domeyer M, Wolloscheck T, et al. Resection of the mesopancreas (RMP): a new surgical classification of a known anatomical space. *World J Surg Oncol*. 2007; 5: 44, doi: 10.1186/1477-7819-5-44, indexed in Pubmed: 17459163.
5. Inoue Y, Saiura A, Yoshioka R, et al. Pancreatoduodenectomy With Systematic Mesopancreas Dissection Using a Supracolic Anterior Artery-first Approach. *Ann Surg*. 2015; 262(6): 1092–1101, doi: 10.1097/SLA.0000000000001065, indexed in Pubmed: 25587814.
6. Wei K, Hackert T. Surgical Treatment of Pancreatic Ductal Adenocarcinoma. *Cancers (Basel)*. 2021; 13(8), doi: 10.3390/cancers13081971, indexed in Pubmed: 33923884.