

The expression of CDX-2 and p53 immunohistochemical markers — a useful diagnostic tool for glandular dysplasia in Barrett's oesophagus

Tomasz Klimczak¹ , Jerzy Klimczak¹, Marian Danilewicz², Lech Pomorski³, Jacek Śmigieński⁴, Wojciech Ciesielski¹

¹Department of General and Transplant Surgery, Medical University of Łódź, Poland

²Department of Pathology, Medical University of Łódź, Poland

³Department of General and Oncological Surgery, Medical University of Łódź, Poland

⁴Ward of General Surgery, Regional Specialist Hospital in Sieradz, Poland

Introduction. Barrett's esophagus (BE), is a common state, concerning roughly about 15% of GERD patients. The pathomechanism of BE is replacement of typical squamous-cell mucosa by a layer of intestinal-type glandular mucosa (intestinal metaplasia). In a number of cases the glands are prone to dysplasia which may lead to the occurrence of esophageal adenocarcinoma.

The golden standard in diagnosis of BE is endoscopy combined with histopathological examination of biopsy material of the altered Z line. Unfortunately, many guidelines do not recommend endoscopic treatment in most cases of BE in favor of long-term screening, reserving the need for treatment for dysplastic BE.

Material and methods. 53 patients suspected of BE (study group) and 45 patients without any macroscopic signs of BE (control group) underwent upper GI endoscopy during which several biopsies were taken from the elevated Z line. The study group was divided into 2 subgroups: I — without histopathological evidence of BE (n = 11); II — histopathologically confirmed BE (n = 42). In addition to the standard histopathological examination, the material was screened for levels of CDX2 and p53 expression.

Results. In the control group, none of the patients presented elevated CDX2 or p53 expression (0%). In the study group, 24 patients were CDX2 positive (45.28%) and 27 were p53 positive (50.94%). Both markers were positive in 21 cases (39.62%).

Conclusions. Standard histopathological examination combined with immunohistochemical examination can prove to be a useful tool in confirming the diagnosis of BE, diagnosing early glandular dysplasia and, in some cases, eliminating false negative results.

Keywords: Barrett's oesophagus, oesophageal adenocarcinoma, p53, CDX-2

Jak cytować / How to cite:

Klimczak T, Klimczak J, Danilewicz M, Pomorski L, Śmigieński J, Ciesielski W. *The expression of CDX-2 and p53 immunohistochemical markers — a useful diagnostic tool for glandular dysplasia in Barrett's oesophagus.* NOWOTWORY J Oncol 2024; 74: 300–305.

Introduction

Barrett's oesophagus (BE) is an acquired pathological condition. Histologically, it means a change in the structure of the distal oesophageal epithelium, just above the cardia. Typically, this means that the normal multi-layer squamous epithelial lining of the oesophagus is replaced with a single-layer columnar epithelium, typical for intestinal mucosa [1, 2]. The disease was named after British surgeon Norman Barrett, who in 1957 described an oesophagus with a "columnar epithelium" [3]. However, the first case of BE is believed to have been reported by another British doctor, Philip Allison, in 1948 [4]. It was found that BE is more frequent in male patients of 50+ years of age, obese patients, smokers and patients with gastroesophageal reflux disease (GERD) often also with a hiatal hernia (HHO) [5, 6].

It is estimated that approximately 1.3–1.9% of the European population might have BE. Interestingly, there is constant significant growth in the incidence of BE; in the 1990s, it was estimated to be around 0.3%. The risk of BE is drastically higher in patients with chronic GERD — approximately 15% [1, 6]. Moreover, in 76.9–96% of cases, patients with BE are also diagnosed with a hiatal hernia (HHO) [6].

The most frequent symptoms of Barrett's oesophagus are: heartburn, eructation, nausea and vomiting, upper abdominal and epigastric pain, dysphagia and halitosis. Less frequent symptoms may include: odynophagia, salivation, coughing, chronic pharyngitis and sinusitis (known also as laryngopharyngeal reflux). Sometimes the abovementioned symptoms are not present at all [7, 8].

According to the European Society of Gastrointestinal Endoscopy (ESGE), in BE a typical endoscopic view is a Z-line elevation of at least 10 mm together with the presence of tongues (dendritic shape, sometimes continent-shaped) that are easily visible in narrow-band imaging (NBI, i-scan). Sometimes, there is just one tongue and the Z line is not elevated. This is what is called a short segment Barrett's oesophagus [9, 10, 11].

In gastroscopy, in the event of suspected BE, the Z-line morphology is described according to the Prague Classification (CM). The two parameters: circumferential (C) and maximal (M) allow the indication of the elevation of the entire circumference of the Z line (C) and the elevation of its highest tongue (M). Distances should be indicated in centimetres, e.g. C2M4 [12].

If there are pathological alterations of the mucosa, a histological verification is necessary; therefore, biopsy samples are collected according to the Seattle protocol [13] — one sample from each Z-line quadrant every 1–2 cm: e.g. if the Z-line elevation is 5 cm, 3–5 samples should be collected from each quadrant.

In order to diagnose BE, it is critical that there be intestinal metaplasia, goblet cells or ectopic gastric glandular tissue. Most commonly, though, the decisive factor in diagnosing BE is the presence of typical intestinal metaplasia [14–17].

Material and methods

This study was approved by the Bioethical Committee of the Medical University in Łódź, No. RNN/51/20/KE.

The study included patients in which, during the screening gastroscopy, macroscopic features of BE were found (study group) as well as patients who did not present with these features but had a gastroscopy and a distal oesophageal biopsy performed for other reasons, e.g. because of an oesophageal erosion in the course of GERD (control group). In all patients, biopsy samples were collected from the same area of the oesophagus, adjacent to the stomach cardia, as indicated in the Seattle protocol [11].

A total of 98 patients were included in the study: 55 men (56.12%) and 43 women (43.88%). The mean age was 56.6 years (from 33 to 89 years, median 51 years).

The patients were divided into the following groups:

- 1) control group: 45 patients, 23 men (51.11%) and 22 women (48.89%), with no morphological changes in the cardia area (visible in endoscopy) and who had never reported gastroesophageal reflux. These patients were asymptomatic, undergoing a routine gastroscopy prior to a scheduled cholecystectomy;
- 2) study group: 53 patients, 32 men (58.18%), 21 women (41.82%); mean age 52.75 years (from 33 to 89 years, median 51 years) — patients who had macroscopically visible characteristics of BE during endoscopy. In the whole study group, immunohistochemical tests were performed retrospectively (based on preserved paraffin blocks).

Based on the outcome of the routine histological exam, the study group was divided into two subgroups:

- 1) group I (n = 11): 5 men (45.45%), 6 women (54.55%); mean age 54.36 years (from 37 to 89 years, median 48 years) — standard histopathological tests did not confirm BE (no intestinal metaplasia and/or goblet cells and no glandular dysplasia);
- 2) group II (n = 42): 25 men (59.52%), 16 women (40.48%); mean age 52.33 years (from 33 to 81 years, median 51 years) — patients with histological evidence and confirmation of BE, including those with confirmed glandular dysplasia.

Additionally, HHO features visible during endoscopy (for clinical reasons, only sliding and mixed type hernias) were taken into account.

Endoscopy

Endoscopy was performed with the PENTAX Medical EG29-i10 gastroscop. The patients received i.v. premedication with midazolam — 5 mg, phentanyl — 100 µg and hyoscine buthylbromide — 20 mg. During endoscopy, patients' heart rate and blood oxygenation were monitored (with a pulse oximeter). Additionally, before introducing the endoscope into the oesophagus, the patient's larynx was sprayed with 1% solution of lidocaine, a local anaesthetic. The endoscopic exam included the oesophagus, stomach and the proximal

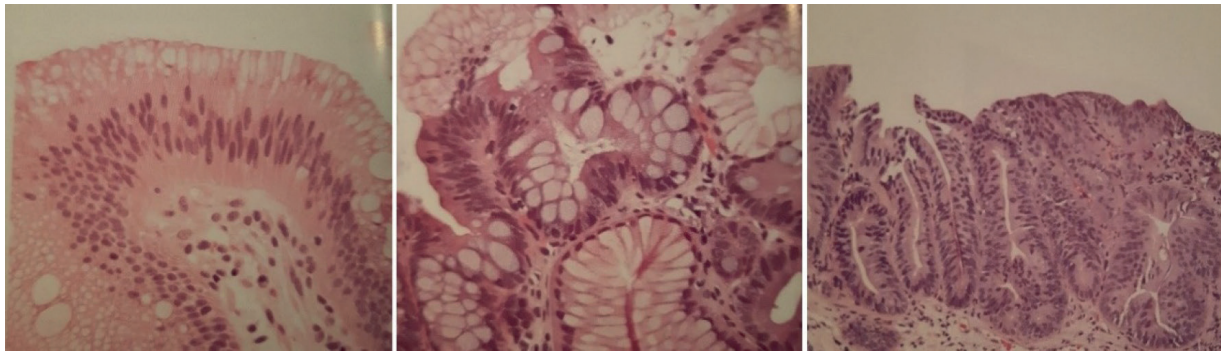


Figure 1. Histopathologic findings in Barrett's oesophagus (BE): intestinal metaplasia (left), low grade dysplasia (centre), high grade dysplasia (right)

part of the duodenum (duodenal papilla, the part behind it and the descending duodenum). If during endoscopy the Z-line morphology typical for BE was encountered, samples were collected according to the Seattle protocol, using Endo-Flex NEO230-G biopsy forceps. In case of the control group, 4 biopsies were taken from the borders of the normal Z-line; similar to the Seattle protocol. Additionally, typical HHO features, such as a hernia ring or a bell-shaped, dilated gastroesophageal junction (GEJ) were recorded. The mean procedure time was 5 min 23 s (from 4 to 11 min). Oesophageal morphology was assessed using the Savary-Miller scale (S-M), and the Z-line was described according to the Prague Classification (CM) [10].

Histological and immunohistochemical tests

Tissue biopsy samples collected during the endoscopy underwent standard histopathological staining with hematoxyline and eosine, followed by the paS-alcian blue staining. This method is aimed at identifying foci of intestinal metaplasia of the glandular gastric mucosa (in order to confirm the diagnosis of BE. European Society of Gastrointestinal Endoscopy criteria have been applied to the full diagnostics of BE (Fig.1).

Following the standard histopathological analysis, the material underwent immunohistochemical staining to assess the expression of CDX2 and p53 proteins using specific antibodies (tests performed in Autostainer by Dako) to indicate possible foci of glandular metaplasia. Because of the fact that the indicated proteins are only present in cellular nuclei, their expression was not routinely assessed in the patients' blood serum.

Biomarkers

The CDX2 protein, encoded by the CDX2 gene (chr13:27, 962, 137-27, 971, 139), is a transcription factor for intestinal cells (so-called goblet cells) actively involved in the correct organogenesis of the intestine. It is typically expressed in the nuclei of intestinal cells. CDX2 is a specific marker for colorectal cancer, but may be an indicator of lung, stomach, pancreatic or bile duct cancer as well [18, 19] (Fig. 2).

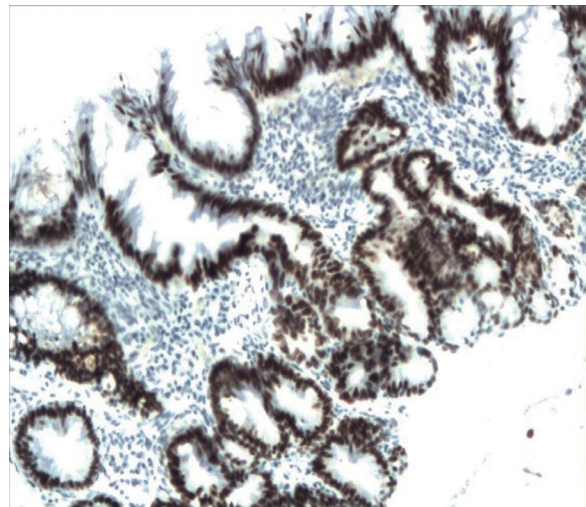


Figure 2. CDX2 positive stain: black nuclei visible represent the cells in which the transition between esophageal to intestinal type is in progress

The p53 protein, encoded by the TP53 gene (*chr17:7, 668, 401-7, 687, 549*), is a transcription factor known also as the "guardian of the genome" and a tumour suppressor. In homeostasis, p53 is inactive. It is only activated when there is a need to repair damaged cell DNA (it creates tetramers enabling the expression of genes such as hdm2, Fas, IGFBP-3, Bax, Cip1 or gadd45) or to induce cell apoptosis by means of cytochrome-C stimulated caspase activation. The expression of the p53 protein in the LH test is a useful marker in the diagnosis of colorectal, breast and lung cancer [20–22] (Fig. 3).

Results

Initially, each of the groups was analysed separately:

- control group: 0 cases (0%) CDX2 staining positive, 0 cases (0%) p53 staining positive, 0 cases (0%) both CDX2 and p53 staining positive;
- study group (overall): 24 cases (45.28%) CDX2 staining positive, 27 cases (50.94%) p53 staining positive, 21 cases (39.62%) both CDX2 and p53 staining positive;
- Group I: 1 case (9.09%) CDX2 staining positive, 5 cases (45.45%) p53 staining positive, 1 case (9.09%) both CDX2 and p53 staining positive;

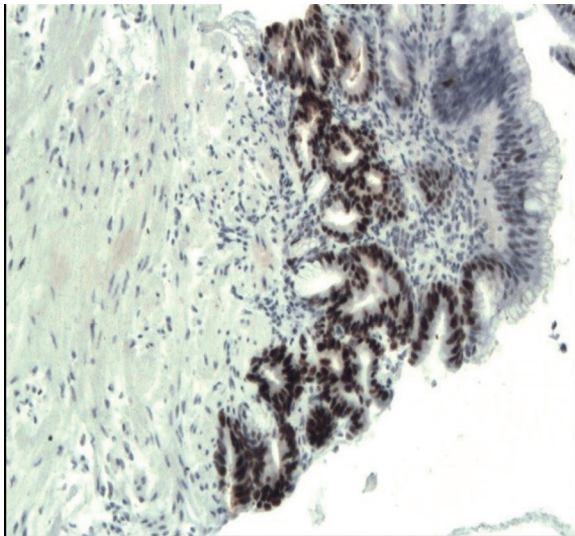


Figure 3. p53 positive stain: the black cells' nuclei indicate that in these the p53 factor is active

— Group II: 23 cases (54.76%) CDX2 staining positive, 22 cases (52.38%) p53 staining positive, 20 cases (47.62%) both CDX2 and p53 staining positive (Fig. 4).

In the samples from all cases of diagnosed glandular dysplasia (11.9% of all cases; n = 6) both markers stained positive.

Discussion

Firstly, concerning the results of our study, we wanted to comment on the specific findings and their clinical significance. In the control group there was no expression of the analysed

markers. In group I (no histopathological confirmation of BE), the fact that in 1 case (9.09%) there was expression of CDX2 might be a result of an "omission" of an intestinal metaplasia (IM) focus in the preparation during the standard histopathological exam. This case should be considered a confirmed case of BE. All other cases where the result was CDX2-negative with p53 expression (45.45%) should be considered an invalid reaction, also referred to as a "wild reaction" — the expression of the p53 marker might be a consequence of another kind of chronic inflammation in the stomach cardia area (e.g. NERD/GERD).

In group II (histopathologically confirmed BE), the expression of CDX2 alone confirms the diagnosis of BE (54.76%). The expression of both CDX2 and p53 (47.62%) might suggest neoplasia at the cellular level, which might yet be invisible or "omitted" in the standard microscopic analysis.

In 19 patients (45.24%) from group II, intestinal metaplasia was not confirmed (CDX2-negative), and, as a consequence, it might be stated that the diagnosis of BE was incorrect.

Upon analysing the international guidelines for BE treatment, one might get the impression that this disease is not a significant threat to the population. Nevertheless, there are numerous international papers that indicate an increasing incidence of oesophageal adenocarcinoma. Between 1980 and 2005 the overall incidence of oesophageal adenocarcinoma increased from 1.2 cases per 100,000 people per year to 6 cases per 100,000 people per year — a fivefold increase [23, 24].

Some factors that increase the risk of oesophageal adenocarcinoma, apart from BE, are: male sex, Caucasian race, obesity and a lack of the *Helicobacter pylori* (HP) bacteria infection. According to the abovementioned authors, the presence

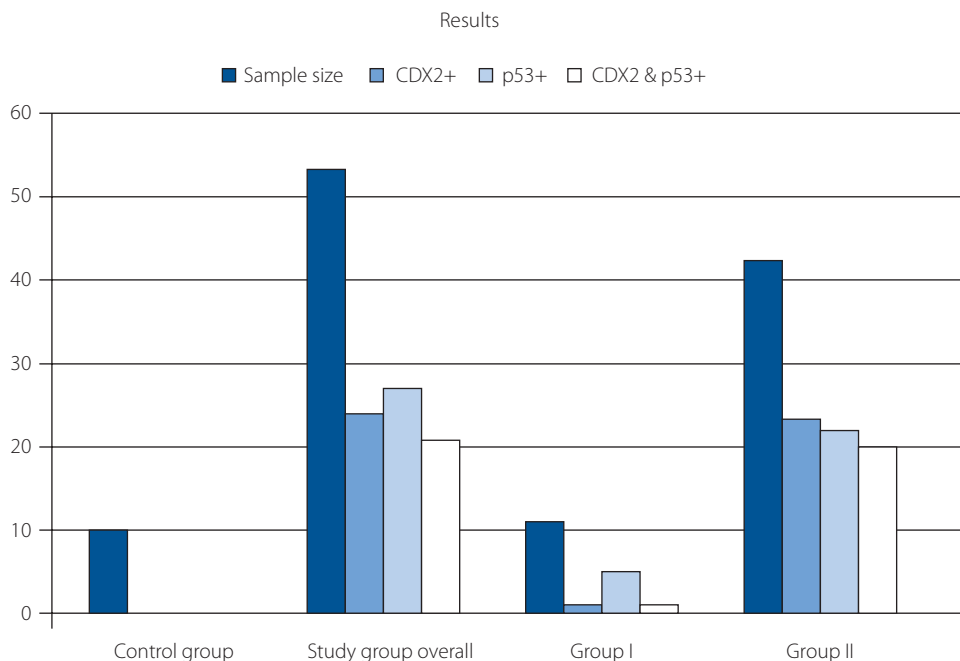


Figure 4. Visual representation of the results

of HP reduces the risk of oesophageal adenocarcinoma by 50% [24, 25].

This increase in incidence over 25 years is particularly surprising because it was an era of intense endoscopic surveillance of BE patients with a strong focus on conservative treatment. The results of one Polish paper confirm the above-mentioned doubts relative to the efficacy of endoscopic surveillance in BE [26]. The authors reported that during 10 years of upper gastrointestinal (GI) tract endoscopic exams, they diagnosed 63 cases of BE. Of those 63, 51 qualified for endoscopic surveillance. Three (5.9%) patients developed oesophageal adenocarcinoma requiring extensive surgical treatment, even though their prior condition could have been treated in a simple and less invasive way. Similar conclusions can be drawn from the analysis of foreign studies. Researchers from Denmark [27] and Sweden [28] via screening diagnosed 167 (out of 11,028 cases of BE) and 82 (out of 7,932 cases of BE) cases of oesophageal cancer. In both countries it was also noticed that cases of adenocarcinoma were diagnosed at the very beginning (before month 3) of surveillance. The authors stated that the majority of cancer cases were a result of inaccurate diagnostics of BE. There is more data on discovering adenocarcinoma cases during the period of BE surveillance [29–31], even though in the phase of neoplasia (state directly prior to cancerogenesis), patients should undergo treatment.

So far, the clinical and theoretical usefulness of immunohistochemical markers expression in the diagnosis of BE has been proven, but none of the numerous papers published are mentioned in the international guidelines for BE. What is more, there are not enough publications on the usefulness of simultaneous testing for the expression of CDX-2 and p53 in the clinical practice of BE diagnostics. The only available study that simultaneously analyses the expression of both CDX-2 and p53 is a paper by Fabio Terabe et al. [29] on an animal model — mice C57B1/6J. In 135 mice, gastroesophageal reflux was surgically induced (by performing oesophagogastrorjejunostomy, oesophagojejunostomy without gastrectomy or oesophagojejunostomy with gastrectomy) and then after 40 weeks the mice were euthanised. Samples collected from their stomach cardia area were analysed in histopathological and immunohistochemical tests. Intestinal metaplasia had developed in 21 out of the 110 mice (19%), of which most cases (45.5%) were in mice who had had undergone oesophagogastrorjejunostomy. In all cases of intestinal metaplasia, expression of the CDX-2 was present. In 8 out of 110 (7.2%) glandular dysplasia developed; most of the cases were reported (7 of 33; 21%) in the group that had had undergone oesophagogastrorjejunostomy. In all dysplasia cases, expression of the p53 protein was present. Additionally, in 62% cases of intestinal dysplasia, expression of the p53 protein was present. In 50% of glandular dysplasia cases there was no expression of the CDX-2 protein. The results presented by Terabe et al. coincide perfectly with the results of my work.

Conclusions

Routine histopathological testing can sometimes give both a false positive and a false negative result in the diagnosis of BE. Testing the expression of the CDX2 and p53 markers with immunohistochemical methods in cases of BE may help detect intestinal metaplasia and potential glandular dysplasia overlooked under standard histopathological procedures.

All procedures performed in studies involving human participants were in accordance with the ethical standards of the institutional and/or national research committee and with the 1964 Helsinki declaration and its later amendments or comparable ethical standards.

Informed consent was obtained from all individual participants included in the study.

Article information and declarations

Data availability statement

All data generated or analyzed during this study are included in this article. Further enquiries can be directed to the corresponding author.

Ethics statement

This study protocol was reviewed and approved by the Committee of Research Ethics of the Medical University of Łódź.

Authors contributions

Tomasz Klimczak — conceptualization, data curation, formal analysis, project administration, writing — original draft preparation.

Jerzy Klimczak — conceptualization, data curation, formal analysis, investigation, methodology, supervision, validation, writing — review & editing.

Marian Danilewicz — conceptualization, data curation, formal analysis, methodology, project administration, supervision, validation, writing — review & editing.

Lech Pomorski — conceptualization, formal analysis, investigation, methodology, project administration, supervision, writing — original draft preparation, writing — review & editing.

Jacek Śmigielski — data curation, methodology, resources, writing — review & editing.

Wojciech Ciesielski — data curation, formal analysis, methodology, writing — original draft preparation.

Funding

None.

Acknowledgments

None.

Conflicts of interest

The authors declare no conflict of interest.

Supplementary material

None.

Tomasz Klimczak

Department of General and Transplant Surgery

Medical University of Łódź

ul. Kopcińskiego 22

90–153 Łódź, Poland

e-mail: tjkklimczak@gmail.com

Received: 7 Mar 2024

Accepted: 31 Jul 2024

Early publication: 18 Oct 2024

References

- Whiteman DC, Kendall BJ. Barrett's oesophagus: epidemiology, diagnosis and clinical management. *Med J Aust.* 2016; 205(7): 317–324, doi: 10.5694/mja16.00796, indexed in Pubmed: 27681974.
- Spechler SJ, Souza RF. Barrett's esophagus. *N Engl J Med.* 2002; 346(11).
- BARRETT NR. The lower esophagus lined by columnar epithelium. *Surgery.* 1957; 41(6): 881–894, indexed in Pubmed: 13442856.
- ALLISON PR. Peptic ulcer of the oesophagus. *Thorax.* 1948; 3(1): 20–42, doi: 10.1136/thx.3.1.20, indexed in Pubmed: 18904843.
- Gajewski P, Szczeklik A. Interna Szczeklika. *Medycyna Praktyczna, Gdańsk* 2017: 949–957.
- Ronkainen J, Aro P, Storskrubb T, et al. Prevalence of Barrett's esophagus in the general population: an endoscopic study. *Gastroenterology.* 2005; 129(6): 1825–1831, doi: 10.1053/j.gastro.2005.08.053, indexed in Pubmed: 16344051.
- Zajac P, Holbrook A, Super M, et al. An overview: Current clinical guidelines for the evaluation, diagnosis, treatment, and management of dyspepsia. *Osteopathic Family Physician.* 2013; 5(2): 79–85, doi: 10.1016/j.osfp.2012.10.005.
- Kahrilas P. Gastroesophageal Reflux Disease. *N Engl J Med.* 2008; 359(16): 1700–1707, doi: 10.1056/nejmcp0804684, indexed in Pubmed: 18923172.
- Weusten B, Bisschops R, Coron E, et al. Endoscopic management of Barrett's esophagus: European Society of Gastrointestinal Endoscopy (ESGE) Position Statement. *Endoscopy.* 2017; 49(2): 191–198, doi: 10.1055/s-0042-122140, indexed in Pubmed: 28122386.
- Odze RD. Diagnosis and grading of dysplasia in Barrett's oesophagus. *J Clin Pathol.* 2006; 59(10): 1029–1038, doi: 10.1136/jcp.2005.035337, indexed in Pubmed: 17021130.
- Schlemper RJ. The Vienna classification of gastrointestinal epithelial neoplasia. *Gut.* 2000; 47(2): 251–255, doi: 10.1136/gut.47.2.251.
- Anand O, Wani S, Sharma P. When and how to grade Barrett's columnar metaplasia: the Prague system. *Best Pract Res Clin Gastroenterol.* 2008; 22(4): 661–669, doi: 10.1016/j.bpg.2008.02.001, indexed in Pubmed: 18656823.
- Lee SW, Lien HC, Chang CS, et al. Benefits of the Seattle biopsy protocol in the diagnosis of Barrett's esophagus in a Chinese population. *World J Clin Cases.* 2018; 6(14): 753–758, doi: 10.12998/wjcc.v6.i14.753, indexed in Pubmed: 30510939.
- Fitzgerald RC, di Pietro M, Ragunath K, et al. British Society of Gastroenterology. British Society of Gastroenterology guidelines on the diagnosis and management of Barrett's oesophagus. *Gut.* 2014; 63(1): 7–42, doi: 10.1136/gutjnl-2013-305372, indexed in Pubmed: 24165758.
- Fleischer DE, Overholt BF, Sharma VK, et al. Endoscopic radiofrequency ablation for Barrett's esophagus: 5-year outcomes from a prospective multicenter trial. *Endoscopy.* 2010; 42(10): 781–789, doi: 10.1055/s-0030-1255779, indexed in Pubmed: 20857372.
- Sharma P, Katzka DA, Gupta N, et al. Radiofrequency ablation in Barrett's esophagus with dysplasia. *N Engl J Med.* 2009; 360(22): 2277–2288, doi: 10.1056/NEJMoa0808145, indexed in Pubmed: 19474425.
- Werling RW, Yaziji H, Bacchi CE, et al. CDX2, a highly sensitive and specific marker of adenocarcinomas of intestinal origin: an immunohistochemical survey of 476 primary and metastatic carcinomas. *Am J Surg Pathol.* 2003; 27(3): 303–310, doi: 10.1097/00000478-200303000-00003, indexed in Pubmed: 12604886.
- Krasinskas A, Goldsmith J. Immunohistology of the Gastrointestinal Tract. *Diagnostic Immunohistochemistry.* 2011: 500–540, doi: 10.1016/b978-1-4160-5766-6.00018-2.
- Correa P, Piazuelo MB, Wilson KT. Pathology of gastric intestinal metaplasia: clinical implications. *Am J Gastroenterol.* 2010; 105(3): 493–498, doi: 10.1038/ajg.2009.728, indexed in Pubmed: 20203636.
- Drewa G, Ferenc T. *Genetyka medyczna. Podręcznik dla studentów.* Elsevier Urban & Partner, Wrocław 2011: 148, 152.
- Boyd MT, Vlatkovic N. p53: a molecular marker for the detection of cancer. *Expert Opin Med Diagn.* 2008; 2(9): 1013–1024, doi: 10.1517/17530059.2.9.1013, indexed in Pubmed: 23495923.
- Tysarowski A, Szumera-Cieckiewicz A, Marszałek A, et al. Molecular diagnostics of cancers – practical approach. *Nowotwory. Journal of Oncology.* 2023; 73(3): 174–186, doi: 10.5603/njo.2023.0028.
- Lam AK. Introduction: Esophageal Adenocarcinoma: Updates of Current Status. *Methods Mol Biol.* 2018; 1756: 1–6, doi: 10.1007/978-1-4939-7734-5_1, indexed in Pubmed: 29600355.
- Lagergren J, Lagergren P. Recent developments in esophageal adenocarcinoma. *CA Cancer J Clin.* 2013; 63(4): 232–248, doi: 10.3322/caac.21185, indexed in Pubmed: 23818335.
- Doorakkers E, Brusselsaers N. Why oesophageal adenocarcinoma is occurring more frequently. *Ned Tijdschr Geneesk.* 2015; 159: A8915, indexed in Pubmed: 26173664.
- Kula Z, Nowicki A, Swierszczyńska A. Barrett's esophagus and gland cancer - the experience of one center. *Polish Journal of Surgery.* 2018; 90(3): 19–24, doi: 10.5604/01.3001.0011.8166.
- Hvid-Jensen F, Pedersen L, Drewes AM, et al. Incidence of adenocarcinoma among patients with Barrett's esophagus. *N Engl J Med.* 2011; 365(15): 1375–1383, doi: 10.1056/NEJMoa1103042, indexed in Pubmed: 21995385.
- Holmberg D, Ness-Jensen E, Mattsson F, et al. Risk of oesophageal adenocarcinoma in individuals with Barrett's oesophagus. *Eur J Cancer.* 2017; 75: 41–46, doi: 10.1016/j.ejca.2016.12.037, indexed in Pubmed: 28214656.
- Solaymani-Dodaran M, Logan RFA, West J, et al. Risk of oesophageal cancer in Barrett's oesophagus and gastro-oesophageal reflux. *Gut.* 2004; 53(8): 1070–1074, doi: 10.1136/gut.2003.028076, indexed in Pubmed: 15247170.
- Corley D, Levin T, Habel L, et al. Surveillance and survival in Barrett's adenocarcinomas: A population-based study. *Gastroenterology.* 2002; 122(3): 633–640, doi: 10.1053/gast.2002.31879.
- Katzka DA, Fitzgerald RC. Time to Challenge Current Strategies for Detection of Barrett's Esophagus and Esophageal Adenocarcinoma. *Dig Dis Sci.* 2020; 65(1): 18–21, doi: 10.1007/s10620-019-05965-0, indexed in Pubmed: 31754994.
- Didkowska J, Barańska K, Miklewska M, et al. Cancer incidence and mortality in Poland in 2023. *Nowotwory. Journal of Oncology.* 2024; 74(2): 75–93, doi: 10.5603/njo.99065.