

Maria Porzezińska¹, Alicja Janowicz¹, Piotr Janowiak¹, Bogumiła Cynowska¹, Adam Sternau², Rafał Pęksa³, Jan Marek Słomiński¹, Ewa Jassem⁴

¹Department of Pneumology, Medical University of Gdańsk, Poland

²Department of Thoracic Surgery, Medical University of Gdańsk, Poland

³Department of Pathology, Medical University of Gdańsk, Poland

⁴Department of Allergology, Medical University of Gdańsk, Poland

Tracheobronchopathia osteochondroplastica — case report and literature review

Tracheobronchopatia osteochondroplastyczna — opis przypadku i przegląd piśmiennictwa

The authors declare no financial disclosure

Abstract

Tracheobronchopathia osteochondroplastica (TBO) is a rare disease of unknown etiology characterised by a formation of multiple, cartilaginous and osteocartilaginous submucosal nodules in the trachea and major bronchi. The course of the disease is usually benign but the narrowing of the respiratory tract can lead to chronic non-specific clinical symptoms.

We present a case of a 50-year old man with chronic exertional dyspnoea and stenosis of the trachea visible in imaging tests, in whom the symptoms were caused by TBO.

Key words: tracheobronchopathia osteochondroplastica, tracheal stenosis, airway diseases

Pneumonol Alergol Pol 2015; 83: 135–139

Streszczenie

Tracheobronchopatia osteochondroplastyczna (TBO) jest rzadką chorobą o niejasnej etiologii, charakteryzującą się powstawaniem mnogich, chrzęstnych i chrzęstno-kostnych guzków w błonie podśluzowej tchawicy i dużych oskrzeli. Przebieg kliniczny choroby jest zwykle łagodny, ale zwężenie dróg oddechowych może powodować przewlekłe, niespecyficzne objawy kliniczne.

Przedstawiono przypadek 50-letniego mężczyzny z przewlekłą dusznością wysiłkową i widocznym w badaniach obrazowych zwężeniem tchawicy. Przyczyną objawów była TBO.

Słowa kluczowe: tracheobronchopatia osteochondroplastyczna, zwężenie tchawicy, choroby dróg oddechowych

Pneumonol Alergol Pol 2015; 83: 135–139

Introduction

Tracheobronchopathia osteochondroplastica (TBO) is a rare disease of unknown etiology characterised by the formation of cartilaginous and

osteocartilaginous submucosal nodules in the airways [1–3]. Lesions, usually multiple, are located in the distal part of the trachea and major bronchi. They project into the lumen of the airways causing their narrowing and clinical symptoms [3, 4].

Address for correspondence: dr hab. n. med. Maria Porzezińska, Klinika Pneumonologii GUMed, ul. Dębinki 7, 80–211 Gdańsk, Tel: +48 58 349 16 25, Fax: +48 58 341 87 68,

e-mail: porzen@gumed.edu.pl

DOI: 10.5603/PIAP.2015.0021

Received: 6.07.2014

Copyright © 2015 PTChP

ISSN 0867–7077

We present a case of a patient with a few years' history of exertional dyspnoea, in whom chest imaging tests revealed tracheal stenosis.

Case report

A fifty-year old male was admitted to the Department of Pneumonology in June 2013 due to tracheal stenosis, which was first visible on chest x-ray and confirmed by computed tomography (CT). He had a few years' history of exertional dyspnoea and infections of the respiratory system recurring several times a year with intensification of dyspnoea and a long-lasting productive cough. Furthermore, he suffered from frequent epistaxis. In addition, he had arterial hypertension, hepatic cirrhosis of mixed etiology (toxic/HBV infection) and secondary thrombocytopenia. Over 20 years ago he was treated with cartilage autograft due to ozaena. He never smoked cigarettes.

On admission to the Department, the patient was in good general condition, without symptoms of respiratory failure. During physical examination, the following deviations from the norm were found: obesity (BMI = 34), a scar in the right hypogastrium due to appendectomy, scars after collecting cartilage for nasal septum graft from the right costal arch. Chest percussion was normal, and auscultation revealed vesicular breath sound. Laboratory tests showed thrombocytopenia and elevated glucose and transaminases levels in blood serum.

Lung function tests did not reveal ventilation disorders such as obstruction or restriction, impairment of diffusion capacity of the lungs for carbon monoxide (DL_{CO}) was not found, exercise tolerance in 6-minute walking test (6MWT) was correct (Table 1). The patient was examined by a laryngologist, who apart from epistaxis in Kieselbach plexus on the left side, found nodules in the proximal part of the trachea. Bronchofibroscope revealed a narrow, bilaterally flattened, non-compliant trachea, with multiple hard polypoidal formations covered with a smooth mucous membrane that caused narrowing of the lumen. The membranous wall of the trachea had no pathological lesions. Lesions of similar morphology were visible in the major bronchi, right superior lobar and intermediate bronchi; they led to the narrowing of their distal parts, which made impossible to insert the apparatus beyond the narrowing (Fig. 1). Fragments of the mucous membrane of the bronchi, which were covered with ciliated epithelium, occasionally with squamous metaplasia, were found in samples col-

lected from the lesions; whereas in submucosa a small fragment of bone was found. No amyloid concretions were present. In order to definitely exclude amyloidosis, next tests were carried out. No abnormal proteins or Bence-Jones protein in the urine were found, daily urinary protein excretion and levels of kappa and lambda light chains in the urine were correct. The abdominal skin and subcutaneous fat-pad biopsy did not show any pathology, no amyloid deposits were identified by histochemical staining (Congo red). A radiologist was consulted regarding chest CT. It showed multisegmental deformities of tracheal cartilage that projected into its lumen causing stenosis of the trachea. In the narrowest place, about 70 mm above the tracheal bifurcation, lumen of the trachea was only 4–5 mm wide. Many cartilages, particularly those situated in the proximal part of the trachea were calcified (Fig. 2).

Basing on the above examinations, the patient was diagnosed with tracheobronchopathia osteochondroplastica. Due to correct lung function tests

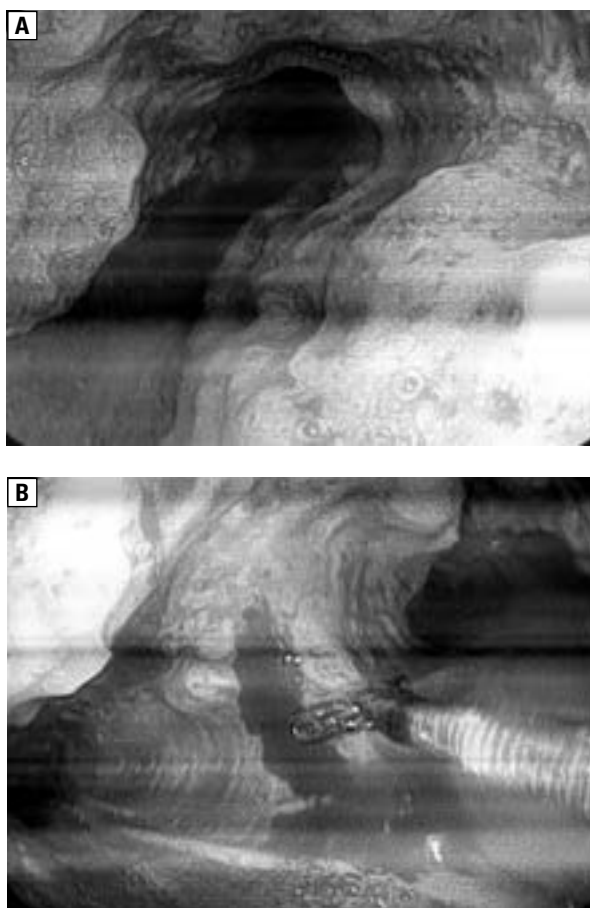


Figure 1. Bronchoscopy appears multiple firm nodules located in the anterolateral tracheal wall (A) and main bronchi (B). The posterior membranous wall of trachea is spared

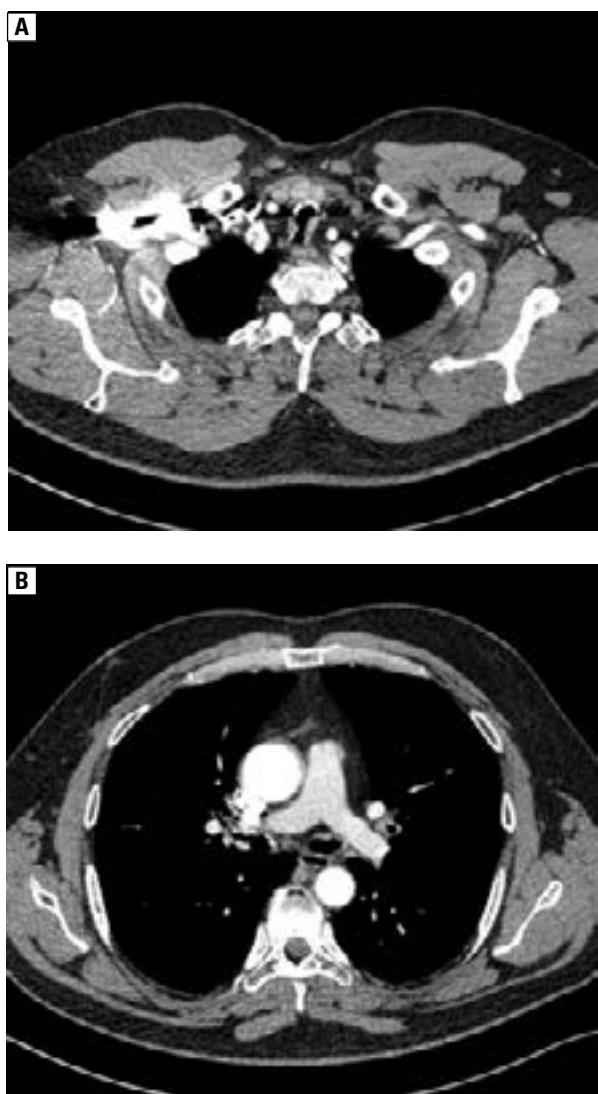


Figure 2. A CT images reveal narrowing of trachea (A) and main bronchi (B) with multiple protruding nodules and calcifications in their walls

results, we resigned from thoracic surgery and mechanical removal of lesions from the airways, instead, we decided to observe the patient.

He was admitted to the Department six months later. Spirometric and bodyplethysmographic parameters were comparable to those collected previously, the distance covered during six minute walking test — 6MWT was extended (Table 1).

Lesions visible on chest CT scan, in comparison with the examination conducted 11 months ago, did not alter. The patient consulted a thoracic surgeon again. Decision was made to continue conservative treatment and follow-up.

Discussion

Typical TBO lesions were described for the first time in the first half of the 19th century by

three independent authors: Rokitansky, Luschka and Wilks [1, 3, 5]. In the past, multiple sub-mucosal cartilaginous and osteocartilaginous nodules in the trachea and major bronchi were diagnosed during autopsy. Currently, in many cases TBO is also found no earlier than during postmortem examination [5–7]. However, because bronchofiberscopy is becoming more and more common in clinical practice, the disease is more frequently diagnosed intravitaly [3]. It is difficult to estimate its prevalence. At autopsy, in various populations, its prevalence varies from 1:400 to 3:1000 cases. During a bronchoscopy, typical lesions are revealed in 0.017% to 0.7% of procedures [2–4, 8, 9]. TBO occurs usually in individuals over 50 years of age, frequently in the sixth or seventh decade of life, however, it may also affect younger people [1–3, 9, 10]. There are reports of the disease occurring even in 9- and 11-year old girls [6, 11]. No dependence was found between the disease incidence and sex [1, 6, 9, 10, 12]. There is no relationship for cigarette smoking and TBO [9], some authors have postulated its more frequent incidence in persons with ozaena, similarly as in the case of the patient described in the present work [2, 6].

Apart from the fact that the clinical symptoms of TBO are not pathognomonic, many subjects do not present any symptoms at all. The disease is detected then by accident e.g. during a bronchofiberscopy performed for other reasons, random chest imaging studies or a difficult intubation [6, 13–15]. If clinical signs occur, they depend on the size of the lesions and their place of occurrence [1, 2]. The most frequent are exertional dyspnoea, chronic cough, expectoration, which is often abundant, and occasionally haemoptysis. In some patients, recurring infections of the lower airways are what predominates [2, 5, 3, 9, 16–18]. Many of them are first diagnosed with asthma or chronic bronchitis [2, 3, 10, 19]. Whereas others seek medical attention due to voice alteration or chronic hoarseness [5, 6, 20]. Physical examination usually does not show any changes [8, 17]. Sometimes the following signs are found above the lung fields: wheezing, stridor, crepitations [9, 10].

Chest x-ray is generally correct [1, 3, 12]. In the advanced phase of the disease (as in the case of our patient), narrowing or displacement of the trachea is visible, with marked irregular outline of its walls [10, 4, 12]. Chest CT provides definitely more information, which shows as follows: thickening of the cartilage of the trachea and bronchi, the presence of segmental calcifications along

Table 1. Pulmonary function tests results

	June 2013	January 2014
FEV ₁	99.2%	96.1%
VC	101.2%	103.9%
TLC	103.3%	103.0%
RV	104.2%	104.3%
DLCO SB	81.9%	–
DLCO VA	90.4%	–
6 MWT		
distance	480 m	620
desaturation	No	No
dyspnoe before test	0 Borg scale	0 Borg scale
dyspnoe after test	3 Borg scale	5 Borg scale

Pulmonary function tests results are showed as a percentage of a predictive value; FEV₁ — forced expiratory volume in one second; VC — vital capacity; TLC — total lung capacity; RV — residual volume; DLCO SB — single-breath diffusing capacity of the lung for carbon monoxide; DLCO/VA — single-breath diffusing capacity of the lung for carbon monoxide corrected for alveolar volume; 6 MWT — 6 minute walking test

their internal surface, multiple calcified nodules not enhanced after contrast, which project into their lumen. Lesions may be visible within the lower airways, from the larynx down to the peripheral bronchi, but most frequently they occur in 2/3 of the distal trachea and proximal bronchi. The posterior wall of the trachea remains free from the lesions [2–4, 20–22]. The CT technique which allows to visualise the airways well is a virtual bronchoscopy [2].

Lung function tests usually do not show airflow limitation [1, 8, 10, 18]. Only a small fraction of patients presents ventilation abnormalities, most commonly bronchial obstruction [1, 10, 12]. If they appear, the changes in lung function tests are the most sensitive way of evaluation of the disease progression [1].

Blood tests, including morphological and biochemical, do not prove useful for diagnosis. Calcium and phosphorus metabolism remains unchanged [3, 8].

Bronchofiberoscopy is the most important examination that allows to diagnose the disease [1]. According to some authors, currently, it allows to diagnose 90% of TBO cases [12]. In the lower airways, there are multiple whitish hard nodules located on the anterior and lateral wall of the trachea, often linked with the cartilages. They are usually warty, sometimes they merge together or take a form of plates. If they occur in large numbers, they look like paving stones [1, 7, 12, 17]. Lesions usually affect distal part of the trachea, however, they may occur on its

all length, also in the major, lobar or segmental bronchi [1, 5, 7, 10, 23]. It is a rare phenomenon that isolated peripheral lesion causes narrowing of the bronchi to the extent that atelectasis occurs [13, 24]. There was a report of a patient, in whom a single tracheal mass in the lumen of the trachea was found [25].

The posterior wall of the trachea is usually free from pathological lesions and this is a symptom which differs TBO from other disorders affecting the airways such as amyloidosis [1, 3, 4, 9, 26]. However, there are few reports of lesions located also in this part of the trachea [8, 7].

It is believed that the airways appearance in bronchofiberoscopy is so typical that it alone is diagnostic of the disease. Histopathological examination is not required [1–3]. Furthermore, because the nodular lesions are very hard, it is difficult to collect material for microscopic examination, although it allows to exclude other diseases such as amyloidosis, neoplasms or papillomas [2, 3]. Histopathological images usually reveal submucosal cartilaginous nodules, sometimes with calcification and ossification foci. Fatty marrow islets may also occur within the nodules, on occasion even with haematopoiesis [5, 7, 22, 24, 27]. The nodules are usually linked to the cartilaginous tracheal and bronchial rings, but they may also be separated from them [5, 7, 8, 22]. Lesions are generally covered with a proper mucous membrane, however, they occasionally show signs of thinning with squamous metaplasia or the features of chronic inflammation [3, 7, 20, 27].

Prognosis in TBO is mostly good. Although cases of rapid, lasting a few months [27] or even weeks [28] progression of the disease have been reported, in most cases, it is benign. The signs may be of similar intensity for years, and even periodically alleviate or disappear completely for the period of several months or years [6, 12]. There is a report of a patient who had no clinical signs for 25 years of follow-up [8].

There is no specific therapy for the disorder as it is impossible to eliminate all lesions or prevent development of new ones. Due to generally mild course of the disease, treatment is applied only in the case of intensive signs. Then it consists of humidification of the airways, avoidance of exposure to irritating agents and prompt treatment of infections of the respiratory system [1, 3]. In some patients, improvement has been achieved after administration of a bronchodilator [3]. Solely in the case of intensive narrowing of the airways, the attempts of mechanical removal of lesions are made using

forceps during laryngoscopy or bronchoscopy, or guillotining using a rigid bronchoscope. Other methods include stent implantation at the place of narrowing, laser ablation and cryotherapy [2, 3, 9, 10, 29]. In some patients, improvement was achieved thanks to radiotherapy [1, 3]. These methods usually lead to alleviation of the symptoms and improvement of the lung function tests, however, sometimes complications occur in the form of secondary narrowing of the airways [9]. There are also cases reporting the course of the disease, during which a significant stenosis occurred, which required thoracic surgery. Surgical treatment include: larynx resection, segmental resection of the trachea, tracheoplasty [3, 27, 30]. In the case of lesions in the lung parenchyma or long-lasting bronchial obstruction, removal of changed fragments of the lung may be necessary [13, 24].

Conclusions

Tracheobronchopathia osteochondroplastica is a rare disorder of the lower airways, usually with a mild clinical course. However, it should be borne in mind as in some patients it may contribute to the occurrence of significant clinical signs and have a vital impact on patients' quality of life.

Conflict of interest

The authors declare no conflict of interest.

References:

- Chroneou A, Zias N, Gonzalez AV, Beamis JF Jr. Tracheobronchopathia osteochondroplastica. An underrecognized entity? *Monaldi Arch Chest Dis* 2008; 69: 65–69.
- Jindal S, Nath A, Neyaz Z, Jaiswal S. Tracheobronchopathia osteochondroplastica—a rare or an overlooked entity? *J Radiol Case Rep* 2013; 7: 16–25.
- Prakash UB. Tracheobronchopathia osteochondroplastica. *Semin Respir Crit Care Med* 2002; 23: 167–175.
- Prince JS, Duhamel DR, Levin DL, Harrell JH, Friedman PJ. Non-neoplastic lesions of the tracheobronchial wall: radiologic findings with bronchoscopic correlation. *Radiographics* 2002; 22: S215–30.
- Martin CJ. Tracheobronchopathia osteochondroplastica. *Arch Otolaryngol* 1974; 100: 290–293.
- Härmä RA, Suurkari S. Tracheopathia chondro-osteoplastica. A clinical study of thirty cases. *Acta Otolaryngol* 1977; 84: 118–123.
- Way SP. Tracheopathia osteoplastica. *J Clin Pathol* 1967; 20: 814–820.
- van Nierop MA, Wagenaar SS, van den Bosch J, Westermann CJ. Tracheobronchopathia osteochondroplastica. Report of four cases. *Eur J Respir Dis* 1983; 64: 129–133.
- Jabbardarjani HR, Radpey B, Kharaian S, Masjedi MR. Tracheobronchopathia osteochondroplastica: presentation of ten cases and review of the literature. *Lung* 2008; 186: 293–297.
- Nienhuis D, Prakash U, Edell E. Tracheobronchopathia osteochondroplastica. *Ann Otol Rhinol Laryngol* 1990; 99: 689–694.
- Simsek PO, Ozelik U, Demirkazik F et al. Tracheobronchopathia osteochondroplastica in a 9-year-old girl. *Pediatr. Pulmonol.* 2006; 41: 95–97.
- Lundgren R, Stjernberg NL. Tracheobronchopathia osteochondroplastica. A clinical bronchoscopic and spirometric study. *Chest* 1981; 80: 706–709.
- Doshi H, Thankachen R, Philip M.A, Kurien S, Shukla V, Korula RJ. Tracheobronchopathia osteochondroplastica presenting as an isolated nodule in the right upper lobe bronchus with upper lobe collapse. *J Thorac Cardiovasc Surg* 2005; 130: 901–902.
- Coëtmeur D, Bovyn G, Leroux P, Niel-Duriez M. Tracheobronchopathia osteochondroplastica presenting at the time of a difficult intubation. *Respir Med* 1997; 91: 496–498.
- Thomas D, Stonell C, Hasan K. Tracheobronchopathia osteoplastica: incidental finding at tracheal intubation. *Br J Anaesth* 2001; 87: 515–517.
- Savelli S, Grata M.L, Ricci A, Gamberini S, Manfredini R. An unusual cause of recurrent hemoptysis: tracheopathia osteoplastica. *Intern Emerg Med* 2010; 5: 437–438.
- Hodges MK, Israel E. Tracheobronchopathia osteochondroplastica presenting as right middle lobe collapse. Diagnosis by bronchoscopy and computerized tomography. *Chest* 1988; 94: 842–844.
- Krenke R, Hildebrand K, Przybyłowski T, Balcerzak J, Chrzan R. Tracheobronchopathia osteochondroplastica. *Pneumonol Alergol Pol* 2002; 70: 601–607.
- Park SS, Shin DH, Lee DH, Jeon SC, Lee JH, Lee JD. Tracheopathia osteoplastica simulating asthmatic symptoms. Diagnosis by bronchoscopy and computerized tomography. *Respiration* 1995; 62: 43–45.
- Onitsuka H, Hirose N, Watanabe K. et al. Computed tomography of tracheopathia osteoplastica. *AJR Am J Roentgenol* 1983; 140: 268–270.
- Hantous-Zannad S, Sebai L, Zidi A. et al. Tracheobronchopathia osteochondroplastica presenting as a respiratory insufficiency: diagnosis by bronchoscopy and MRI. *Eur J Radiol* 2003; 45: 113–116.
- Young RH, Sandstrom RE, Mark GJ. Tracheopathia osteoplastica: clinical, radiologic, and pathological correlations. *J Thorac Cardiovasc Surg* 1980; 79: 537–541.
- Marchiori E, Pozes AS, Souza Junior AS. et al. Diffuse abnormalities of the trachea: computed tomography findings. *J Bras Pneumol* 2008; 34: 47–54.
- Shigematsu Y, Sugio K, Yasuda M. et al. Tracheobronchopathia osteochondroplastica occurring in a subsegmental bronchus and causing obstructive pneumonia. *Ann Thorac Surg* 2005; 80: 1936–1938.
- Raess PW, Cowan SW, Haas AR. et al. Tracheobronchopathia osteochondroplastica presenting as a single dominant tracheal mass. *Ann Diagn Pathol* 2011; 15: 431–435.
- Meyer CA, White CS. Cartilaginous disorders of the chest. *Radiographics* 1998; 18: 1109–1123.
- Khan AM, Shim C, Simmons N. et al. Tracheobronchopathia osteochondroplastica: a rare cause of tracheal stenosis — “TPO stenosis”. *J Thorac Cardiovasc Surg* 2006; 132: 714–716.
- Molloy AR, McMahon JN. Rapid progression of tracheal stenosis associated with tracheopathia osteo-chondroplastica. *Intensive Care Med* 1988; 15: 60–62.
- Nieves-Nieves J, Viridiana-Gonzalez S, Fernandez-Gonzalez R, Fernandez-Medero R. Tracheobronchopathia osteochondroplastica: an underdiagnosed central airway disease. *Int J Med Med Sci* 2012; 4: 211–213.
- Kutlu CA, Yeginsu A, Ozalp T, Baran R. Modified slide tracheoplasty for the management of tracheobronchopathia osteochondroplastica. *Eur J Cardiothor Surg* 2002; 21: 140–142.