

Anna Pyszora¹, Agnieszka Wójcik², Małgorzata Krajnik¹

¹Chair and Department of Palliative Care, Nicolaus Copernicus University, *Collegium Medicum*, Bydgoszcz, Poland

²Faculty of Rehabilitation, Józef Piłsudski University of Physical Education in Warsaw, Poland

Are soft tissue therapies and Kinesio Taping useful for symptom management in palliative care? Three case reports.

Abstract

Physiotherapy may improve the quality of life of patients provided with palliative care. In this article the authors present three cases of advanced cancer patients whose symptoms were successfully treated with various methods of physiotherapy, such as soft tissue therapy and Kinesio Taping. The authors show that a physiotherapist, as part of a multidisciplinary team, plays an important role in the care of patients with progressive diseases. Physiotherapy can minimize the complications and effects of a disease and optimize patients' condition.

Key words: soft tissue therapy, Kinesio Taping, physiotherapy, palliative care

Adv. Pall. Med. 2010; 9, 3: 87–92

Introduction and scope

Palliative care focuses on the physical, psychological and spiritual care of patients with progressive diseases, aiming to provide the best quality of life for the patients and their carers. Physiotherapy is an important part of palliative care. According to Fulton and Else, physiotherapy aims to optimize a patient's level of physical function and takes into consideration the interplay between the physical, psychological, social, and vocational domains of functions [1]. Physiotherapy is a rapidly-expanding field. The number of techniques and therapeutic methods which give therapists an opportunity to work with patients more effectively has been con-

stantly increasing. They include, among others, soft tissue therapy (STT) and Kinesio Taping.

Soft tissue therapy (STT) is the assessment and treatment of soft tissue injuries, pain and dysfunctions of the neuromusculoskeletal system. Soft tissue therapy includes a number of techniques (see Table 1), which can be used to treat various conditions. These techniques influence the muscles, fascia, skin and nervous system. An understanding of the body's multilayer structure and the possibility to work with soft tissue selectively are fundamental to the treatment. Thus, STT focuses on the relaxation and lengthening of the tissue as well as the release of tension. Treatment approaches can be categorized as being direct and indirect, active and passive,

Address for correspondence: Anna Pyszora

Chair and Department of Palliative Care, Nicolaus Copernicus University, *Collegium Medicum*

ul. Skłodowskiej-Curie 9, 85–094 Bydgoszcz, Poland

e-mail: aniap30@wp.pl

Advances in Palliative Medicine 2010, 9, 87–92


 Copyright © 2010 Via Medica, ISSN 1898–3863

Table 1. Soft tissue techniques

Myofascial release (MFR)
Trigger point therapy
Muscle energy techniques (MET)
Positional release techniques (PRT)
Traditional massage
Deep tissue massage (DTM)

gentle or mechanically invasive and all have value in their appropriate settings [2]. Gentle approaches are more common in palliative care and therapists are often limited to passive techniques due to the poor general condition of patients in the advanced stages of disease. In this article the authors present three advanced cancer patients, whose unbearable symptoms were successfully treated with some of the STT techniques. The patients were also treated using Kinesio Taping, which consists of using special tapes modelled on the skin's characteristics. The positive results of Kinesio Taping can be explained by the improvement in blood and lymphatic circulation, activation of the endogenous analgesic system and the support or correction of joint functions [3].

The cases presented below focus on the techniques used in each physiotherapy intervention and how they benefited the patients.

Case report no. 1

An 80-year-old man was admitted for palliative home care in April 2009. In 2008 the patient was diagnosed with advanced lung cancer and did not qualify for curative treatment. He underwent palliative radiotherapy and was transferred for palliative home care in a good functional condition. At the time of admittance, the patient suffered from visceral pain caused by pleural infiltration. The pain was successfully treated with transdermal fentanyl (100 µg/h). After 2–3 weeks the patient started suffering from pain in the cervical and shoulder area, which increased during arm movement. The doctor identified the symptoms as musculoskeletal pain which required the implementation of physiotherapy. The physiotherapist's primary task was to find the cause of the pain. The most intensive pain was located in the high cervical region of the paraspinal muscles, the suprascapular and acromion area on the right side of the body. The patient described the pain as an annoying, deep ache and soreness. The physiotherapist did not observe any restriction of the neck motion. The location and

characteristics of the symptoms indicated a problem with the trapezius muscle. Travell and Simons have found that the trapezius is probably the muscle most often beset by myofascial trigger points (TrPs) [4]. The physiotherapist found TrPs in the lower trapezius fibres near the lower border of the muscle and medial to the vertebral border of the scapula on the right side of the body. Therapy started with the inactivation of TrPs. The physiotherapist used the integrated neuromuscular inhibition technique (INIT), which has been described by Chaitow and De Lany as an effective method for the deactivation of TrPs [5]. INIT starts with the ischaemic compression of a TrP (5–6 seconds) followed by the release of this pressure (2–3 seconds); this pattern is repeated for up to two minutes. The therapist should then find the position of maximal release, which Chaitow and De Lany call the "position of ease". This position is held for not less than 20 seconds to enable neurological resetting, reduction in nociceptor activity and enhanced local circulatory interchange. After the appropriate length of time, during which the tissues are held at ease, the patient is asked to introduce an isometric contraction into the affected tissue for 7–10 seconds, which produces a post-isometric relaxation of the muscle fibres. This way, a new "position of ease" is found. It is then useful to add a re-educational activation of antagonists to the muscle housing the TrP [5, 6].

INIT was followed by Kinesio Taping on the TrP to keep the therapeutic effect (see Figure 1). The tape was left on the patient's skin until the next visit by the physiotherapist. After the first session of INIT and Kinesio Taping, the musculoskeletal pain disappeared. The physiotherapy sessions had to be repeated every 4–5 days, otherwise the pain would have returned.

Pain reduction allowed the patient to improve his daily activities. Furthermore, the psychological distress was decreased, which improved family relations. The patient was highly satisfied with the effects of the physiotherapy. The treatment was continued until the patient's death four months after his admission for palliative home care.

Case report no. 2

A 62-year-old woman was admitted for palliative home care in July 2008. In 2007 the patient was diagnosed with multiple myeloma and is currently undergoing active oncological treatment. The patient suffered from bone pain due to pathological compressive fractures of the lumbar spine (Th

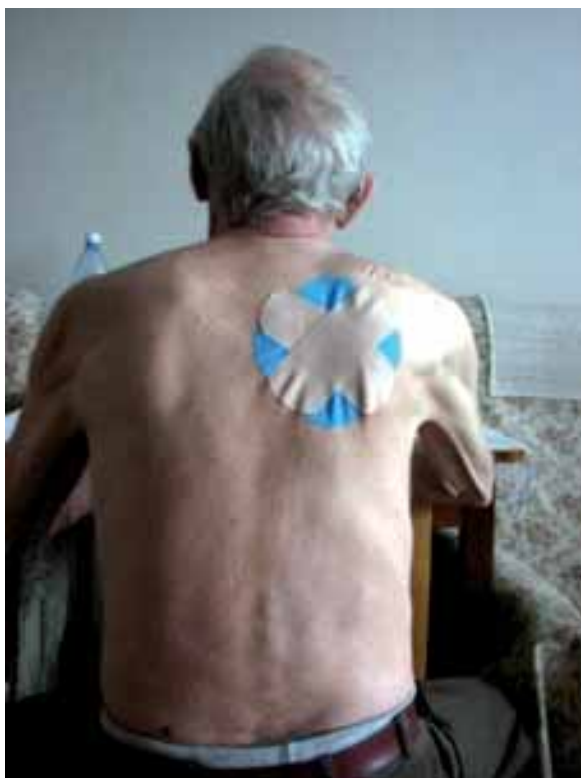

Figure 1. Kinesio taping — trigger point application, lower trapezius fibres (Case report no. 1)

4–5), which was successfully treated with tramadol (150 mg a day) and spinal column stabilization, using lumbo-sacral orthosis. Unfortunately, the patient also suffered from constipation. As a source of abdominal pain, this significantly decreased her quality of life. Unfortunately, laxatives proved to be ineffective. Lengthy immobilization was thought to be one of the constipation risk factors and, therefore, physiotherapy was recommended. The main aims of the physiotherapy were to increase physical activity, decrease the tenseness of the abdominal integuments and stimulate peristaltic movement. The physiotherapy started with myofascial release (MFR), which included the release of the rectus abdominis, pyramidalis, abdominal obliques and transversus abdominis. To perform MFR, special grips are used to stretch the fascia and release bonds between the fascia, integuments and muscles. MFR is a set of very convenient and effective stretching techniques. What is important for patients with constipation is that the MFR techniques are very gentle and do not increase abdominal pain. The release of tightness and restriction can affect other body organs through a reflex relaxation of tension transmitted by the greater fascial system [7]. This can benefit pain re-

duction and body posture improvement. The next step was instructing the patient's family in how to carry out simple abdominal massage. The procedure included abdominal effleurage, petrissage, kneading, vibration and tapotement. These techniques were used to reduce muscle tension, improve local circulation, soothe indigestion, stimulate the secretion of stomach acid, increase the appetite and stimulate peristaltic movement [8]. The family was not only asked to perform abdominal massage, but also to assist in an exercise programme, including active exercises and gait training. This part of the therapy was aimed at increasing mobility and training muscles, as abdominal muscles and pelvic floor muscles can actively help to initiate defecation. The last part of the therapy was Kinesio Taping, with the use of the spiral application for both the large and small intestines to reduce constipation and the tight feeling in the abdomen [9] (Figure 2).

After the first session of the physiotherapy programme, the tenseness in the abdominal integuments significantly decreased and the pain in the abdomen considerably reduced. The patient was highly satisfied with the effects of the physiotherapy intervention. During the following days, abdominal massage was performed by the family twice daily. The frequency of defecation was greater and less painful. The physiotherapy treatment has been carried out with positive effects up to now. In the meantime, the patient's general condition has significantly improved, thanks to good pain control and the enhancement of her functional status. The patient's therapy has not only consisted of constipation treatment, but has also included active exercises and gait re-education using PNF (proprioceptive neuromuscular facilitation). It is very important to take constipation risk factors into consideration.

Case report no. 3

A 77-year-old woman was admitted for palliative home care in June 2010. In 1988 the patient was diagnosed with breast cancer and underwent a mastectomy. Twelve years later she was diagnosed with advanced cervical carcinoma with lumbar spine and left tibial bone metastases. A hysterectomy and radiotherapy were performed as part of the treatment. In June 2010 the patient sustained a pathological fracture of the left tibial bone. The consulting orthopaedist recommended surgical treatment. The patient, however, did not consent to surgery and on that account a non-invasive treatment was used and a plaster splint applied. After six weeks of immobiliza-

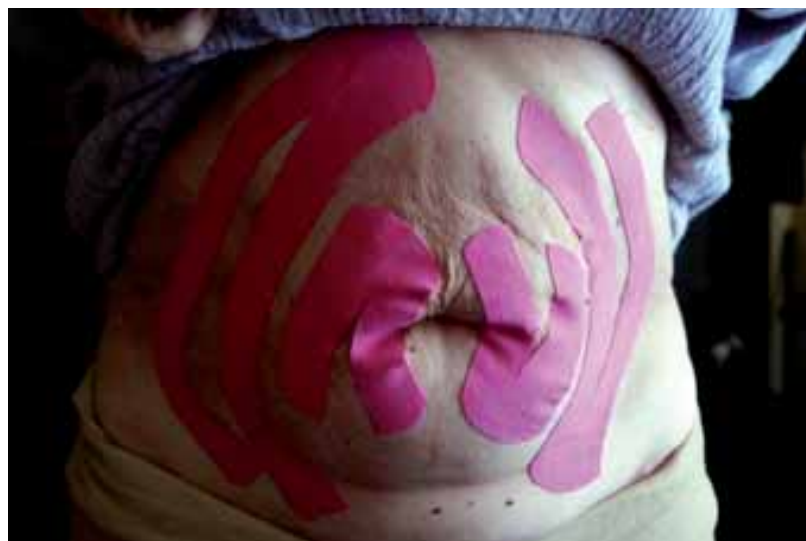

Figure 2. Kinesio taping — spiral application for intestines (Case report no. 2)

tion, the limb was X-rayed, but there was no union of the fractured bone. The patient then agreed to surgery and in June 2010 she underwent intramedullary osteosynthesis. A week later the patient was released home.

Physiotherapy was necessary to enable improvement in the patient's functional status. In the beginning, this included chest physical therapy (chest PT), active exercise of the upper extremities, and exercises involving self-repositioning in bed (using PNF patterns). Moreover, gentle MFR techniques were used to decrease skin and muscle tension. The patient complained of intensive pain in the ankle and knee. A greater limitation of skin movement was also observed in that area. These symptoms were probably connected with the long immobilization in plaster (6 weeks) and surgical interference. To ease this, fascial applications of Kinesio Taping were used (Figure 3). The procedure proved to be effective in skin and muscle tension reduction as well as in decreasing pain. Thus, during the next physiotherapeutic session the patient was able to make gentle movements of the affected limb by herself. Moreover, the range of left knee flexion was significantly greater, which allowed her to reach the sitting position with her legs down. To enlarge the range of movement in the ankle, the physiotherapist applied isometric contraction using post-isometric relaxation. During the following week the pain in the lower limb kept decreasing. The patient spent more and more time in the sitting position and could reach the standing position with the help of a walker. However, the standing position intensified the oedema in the left

knee and shank. To stimulate circulation, lymphatic drainage techniques and the lymphatic application of Kinesio Taping were used (Figure 4) [9, 10]. These proved to have a visible anti-oedematous effect. The next step of the treatment was gait re-education, which has been continuing up to now. Now, the patient is able to move around her apartment with a walker. In addition, the patient was asked to perform an exercise programme, including active exercises and chest physiotherapy. The aim of the active exercises is to augment muscle forces and improve neuromuscular coordination. The chest physiotherapy is used to prevent the accumulation of secretions, improve the mobilization and drainage of secretions, promote relaxation to improve breathing patterns, strengthen respiratory muscles, and increase chest expansion [11, 12].

The patient is highly satisfied with the effects of the physiotherapy. She is very happy to be able to do some housework (such as cleaning or cutting-up food) and walking. Thanks to complex physiotherapy treatment, she has achieved a high level of independence, which has significantly enhanced her quality of life.

Discussion

Disability in patients with progressive disease often results from bed rest, deconditioning and musculoskeletal complications. Palliative care patients have a high prevalence of weakness, pain, fatigue, constipation and other unpleasant symptoms. The initial physiotherapy assessment estab-

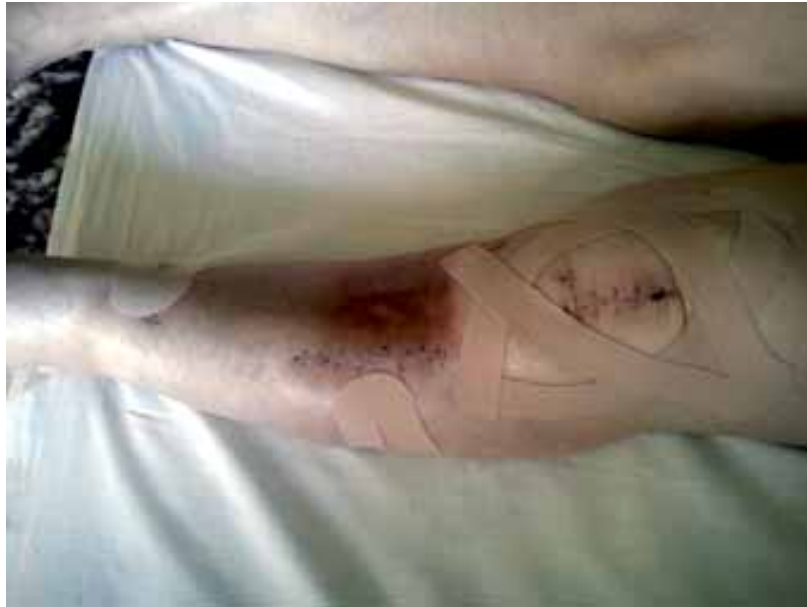

Figure 3. Kinesio taping — fascial applications (Case report no. 3)

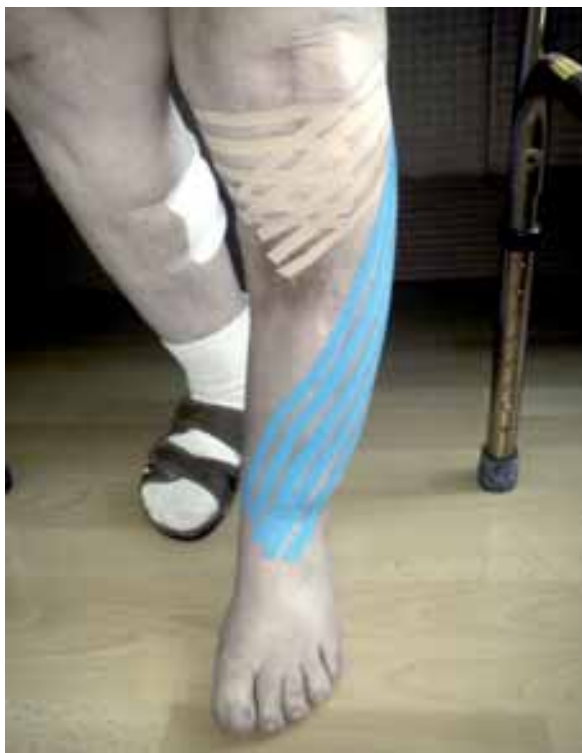

Figure 4. Kinesio Taping — lymphatic applications (Case report no. 3)

lishes an individual's needs by demonstrating their current impairments as well as any restrictions in daily activities. It also highlights all the treatable symptoms and aspects of a disease. In this article the

authors presented three advanced cancer patients, whose symptoms were successfully treated with soft tissue therapy and Kinesio Taping, amongst other techniques. The positive effect of the physiotherapy treatment described in this article is unquestioned. What is more, the authors have proved that palliative care and rehabilitation have a lot in common. They are both essentially inter-disciplinary clinical disciplines which focus on improving the quality of human experience in dying or disability. Both primarily involve complex 'intervention' from a multidisciplinary team of professionals. Nevertheless, it ought to be emphasized that palliative care physiotherapy differs from conventional rehabilitation by virtue of the knowledge that all patients will decline during the period of care. The time and course of the decline can vary considerably; some patients grow progressively weaker, some remain on a plateau for weeks or months and then decline suddenly, some remain active until death. In palliative care, patients' goals of physiotherapy should be realistic and achievable in a relatively short time. Physical function and independence should be maintained as long as possible to improve patients' quality of life and reduce the burden of care for the caregivers [13].

References

1. Fulton C.L., Else R. Rehabilitation in palliative care. In: Textbook of Palliative Medicine, Second Edition. Doyle D., Hanks G., MacDonald N. Oxford University Press, Oxford 1998: 816–828.

2. Chaitow L, De Lany J. Clinical Application of Neuromuscular Techniques. Vol. 1 — The Upper Body. Churchill Livingstone, London 2000: 129–154.
3. Kase K. Illustrated Kinesiotaping. 4th ed. Ken Ikai, Tokyo 2003: 6–12.
4. Travell J., Simons D. Myofascial Pain and Dysfunction. The Trigger Point Manual, Volume 1. Upper Half of Body. Second Edition. Lippincott Williams & Wilkins, Philadelphia 1999: 278–306.
5. Chaitow L, De Lany J. Clinical Application of Neuromuscular Techniques. Vol. 1 — The Upper Body. 2nd ed. Churchill Livingstone, London 2008: 97.
6. Marcus A., Kuchera M. Foundations for Integrative Musculoskeletal Medicine: An East-West Approach. North Atlantic Books, Berkeley 2004: 489.
7. Manheim C. The Myofascial Release Manual. 4th ed. Slack 2008: 2–12.
8. Sinclair M. The forgotten core — revisiting abdominal massage. *Massage & Bodywork* 2009 (July/August): 72–79.
9. Kase K., Stockheimer K.R. KinesioTaping® for lymphoedema and chronic swelling. *Kinesio Taping association*. Tokyo 2006: 89–90.
10. Leduc A, Leduc O. Manual lymphatic drainage. In: Twycross R., Jenns K., Todd J. (eds.). *Lymphoedema*. Radcliffe Medical Press, Oxford 2000: 338–358.
11. Barnes T.A. Core textbook of Respiratory Care Practice. Mosby, St. Louis 1994; 199–222.
12. Porter S. Tidy's Physiotherapy. Fourteenth Edition. Churchill Livingstone, London 2008: 416.
13. Santiago-Palma J., Payne R. Palliative care and rehabilitation. *Cancer* 2001; 4: 1049–1052.