

Secondary refractory lymphoblastic leukemia in patient with Li-Fraumeni syndrome

Katarzyna Smalisz¹, Julia Białowąs², Katarzyna Pawelec^{3*} , Jolanta Goździk¹

¹Department of Medical Education, Jagiellonian University Medical College, Krakow, Poland

²Student Scientific Society „Sferocyt”, Medical University of Warsaw, Poland

³Department of Pediatric Hematology and Oncology, Clinical Transplantology and Pediatrics, Medical University of Warsaw, Poland

In Li-Fraumeni syndrome, there are germline changes in the *TP53* gene predisposing to malignancies such as brain tumors, sarcomas, and leukemias. The risk of malignancy at developmental age is 30–40% [1, 2]. Radiotherapy should be avoided, and the therapy of choice is non-genotoxic chemotherapy and especially surgical treatment [2, 3].

A 4-month-old male infant was admitted for further diagnostics due to increased muscle tone, flexion of the body, and a weakened reaction to external stimuli. On physical examination, bilateral exophthalmos and anterior fontanel with increased tension were observed. Computed tomography (CT) of the head showed a tumor measuring 46 × 54 × 68 mm emerging from the choroid of the posterior corner of the right lateral ventricle. The tumor was completely removed, and in histopathological examination choroid plexus carcinoma (CPC) was recognised [grade III (GIII) acc. to World Health Organization (WHO)].

Chemotherapy was started according to the CPT-SIOP (etoposide, carboplatin, vincristine) protocol. Nineteen courses of chemotherapy were applied. In a control MRI of the CNS one year after the diagnosis, the disease was in remission (CR). Due to the diagnosis of CPC, a genetic test was performed using next generation sequencing (NGS). Based on the presence of a c.469G>T (p.Val157Phe) substitution in the heterozygous form in exon 5 of the *TP53* gene, the final diagnosis was established: genetically determined cancer predisposition syndrome (Li-Fraumeni syndrome). After carrier tests had been carried out on the parents, the syndrome was confirmed in the father.

After the boy had completed chemotherapy for the central nervous system (CNS) tumor, he achieved complete remission. He was monitored regularly with head magnetic resonance imaging (MRI) and blood count.

At the age of five years, he was hospitalized again due to fever and enlarged cervical lymph nodes. On admission, in physical examination he presented features of thrombocytopenic diathesis, lymphadenopathy, and hepatosplenomegaly. Laboratory tests showed pancytopenia. Imaging studies described extensive nodal masses in the mediastinum. The child's condition deteriorated, and features of superior vena cava syndrome were found. An urgent biopsy of the nodal mass and bone marrow was performed. The myelogram showed 28% T-cell lymphoblasts, and histopathology showed T-cell lymphoma with Tdt, CD3 and Bcl-2. There were no CNS infiltrations. A diagnosis of T-cell acute lymphoblastic leukemia (T-ALL) was established.

Treatment was started according to the *Associazione Italiana di Ematologia ed Oncologia Pediatrica* Berlin–Frankfurt–Münster (AIEOP BFM) 2017 protocol for the high-risk (HR) group. The treatment was complicated by acute pancreatitis, neutropenia and hepatitis. These conditions caused delays to the chemotherapy [4]. In a pre-HR2 minimal residual disease (MRD) study, molecular relapse was identified. It was decided to modify the chemotherapy line according to the IntReALL 2010 protocol, deploying at first block of HIB with bortezomib. Venetoclax was started, followed by a block of cyclophosphamide + etoposide + nelarabine. Because there was no remission, it was decided to change chemotherapy to a TVTC

*Address for correspondence: Katarzyna Pawelec, Department of Pediatric Hematology and Oncology, Clinical Transplantology and Pediatrics, Medical University of Warsaw, Żwirki i Wigury 63A, 02-091 Warszawa, Poland, e-mail: katarzyna.pawelec@diskuckwum.pl

Received: 30.08.2023 Accepted: 04.12.2023 Early publication: 25.12.2024

This article is available in open access under Creative Commons Attribution-Non-Commercial-No Derivatives 4.0 International (CC BY-NC-ND 4.0) license, allowing to download articles and share them with others as long as they credit the authors and the publisher, but without permission to change them in any way or use them commercially.

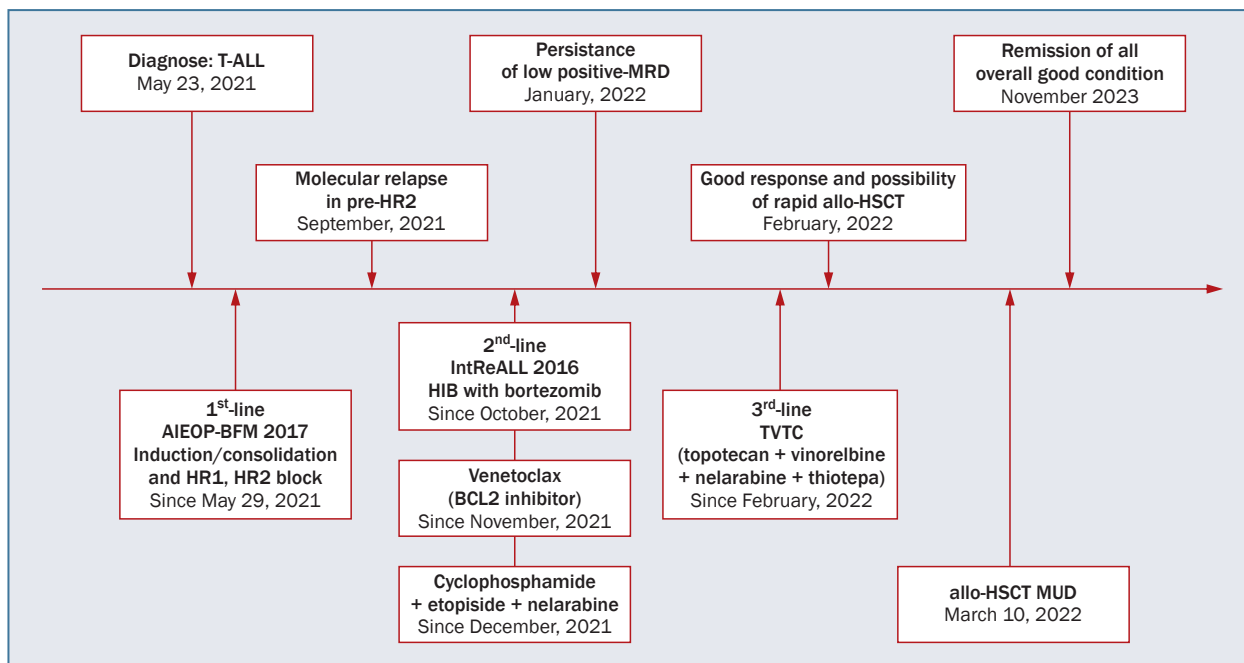


Figure 1. Types of T-cell acute lymphoblastic leukemia (T-ALL) therapy in patient with Li-Fraumeni syndrome; AIEOP-BFM – *Associazione Italiana di Ematologia ed Oncologia Pediatrica* Berlin–Frankfurt–Münster; allo-HSCT – allogeneic hematopoietic stem cell transplantation; BCL2 – B-cell CLL/lymphoma 2; MRD – minimal residual disease; MUD – matched unrelated donor

block (topotecan + vinorelbine + nelarabine + thiotepa). Then he was qualified for allogeneic hematopoietic stem cell transplantation (allo-HSCT) from a matched unrelated donor (MUD). Busulfan, etoposide and cyclophosphamide were used for conditioning. The transplantation was complicated by cutaneous and intestinal graft-versus-host disease (GvHD) (WHO GIII). A bone marrow myelogram performed on day +25 met the criteria for hematological remission. Chimerism was estimated at 98.5%, but a molecular assay showed leukemic cells of 9×10^{-4} . To enhance the immunotherapeutic effect of graft-versus-leukemia, cyclosporine was discontinued, and methylprednisolone was reduced to half of the usual dose and completely discontinued within two months. On day +60, molecular MRD was for the first time negative. The patient remained in remission for ALL. He has remained under constant follow-up, with the most recent visit being in November 2023.

Li-Fraumeni syndrome is associated with a predisposition to neof ormation. In 50–80% of children, choroid plexus cancer is caused by germline variants in the *TP53* gene, regardless of pedigree data [3, 5]. In the described boy, resistance to ALL treatment could be expected. During treatment with CPC, the patient underwent CPT-SIOP chemotherapy, which consists of carboplatin (an alkylating drug) and etoposide (a topoisomerase II inhibitor), which specifically contribute to the development of acute myeloid leukemia (AML) [6]. However, this child developed ALL,

which indicates that his acute leukemia was not directly related to the treatment of the previous cancer, but rather to Li-Fraumeni syndrome.

According to the protocol, the patient should have undergone radiotherapy due to the presence of a mediastinal tumor, but it was felt advisable to refrain from using this method [7]. Due to the molecular relapse before the HR2 block, modification of chemotherapy was needed, and the IntreALL-HR 2010 protocol was started [8]. Allo-HSCT was the only chance to cure acute lymphoblastic leukemia [9].

Ultimately, a good response to TVTC chemotherapy allowed the boy to be qualified for allo-HSCT. In this patient, additionally the graft-versus-leukemia effect was beneficial, because it gave a chance to defeat the cancer, leading to a complete reduction of the residual disease [10].

Article information and declarations

Acknowledgments

Not applicable.

Author contributions

All authors have made a substantial, direct and intellectual contribution to the work and approved it for publication.

Conflict of interests

The authors declare no conflict of interests.

Ethics statement

The work described in this article has been carried out in accordance with The Code of Ethics of the World Medical Association (Declaration of Helsinki) for experiments involving humans; EU Directive 2010/63/EU for animal experiments and uniform requirements for manuscripts submitted to biomedical journals.

Funding

None.

Supplementary material

None.

References

- Romiszewska M, Malinowska I. Zaburzenia genetyczne u dzieci z ostrą białaczką limfoblastyczną, ich znaczenie kliniczne i terapeutyczne. *Acta Haematol Pol.* 2017; 48(4): 300–307, doi: [10.1016/j.achaem.2017.06.003](https://doi.org/10.1016/j.achaem.2017.06.003).
- Frebourg T, Bajalica Lagercrantz S, Oliveira C, et al. European Reference Network GENTURIS. Guidelines for the Li-Fraumeni and heritable TP53-related cancer syndromes. *Eur J Hum Genet.* 2020; 28(10): 1379–1386, doi: [10.1038/s41431-020-0638-4](https://doi.org/10.1038/s41431-020-0638-4), indexed in Pubmed: [32457520](https://pubmed.ncbi.nlm.nih.gov/32457520/).
- Gargallo P, Yáñez Y, Segura V, et al. Li-Fraumeni syndrome heterogeneity. *Clin Transl Oncol.* 2020; 22(7): 978–988, doi: [10.1007/s12094-019-02236-2](https://doi.org/10.1007/s12094-019-02236-2), indexed in Pubmed: [31691207](https://pubmed.ncbi.nlm.nih.gov/31691207/).
- Puła A, Zdunek M, Michalczyk K, et al. Chemotherapy delays in children with acute lymphoblastic leukemia might influence the outcome of treatment. *Acta Haematol Pol.* 2022; 53(2): 141–148, doi: [10.5603/ahp.a2022.0007](https://doi.org/10.5603/ahp.a2022.0007).
- Gozali AE, Britt B, Shane L, et al. Choroid plexus tumors; management, outcome, and association with the Li-Fraumeni syndrome: the Children's Hospital Los Angeles (CHLA) experience, 1991-2010. *Pediatr Blood Cancer.* 2012; 58(6): 905–909, doi: [10.1002/pbc.23349](https://doi.org/10.1002/pbc.23349), indexed in Pubmed: [21990040](https://pubmed.ncbi.nlm.nih.gov/21990040/).
- Spałek A, Woźniczka K, Armatys A, et al. Allogeneic stem cell transplantation remains an effective therapeutic approach for patients with therapy-related acute myeloid leukemia. *Acta Haematol Pol.* 2021; 52(2): 103–109, doi: [10.5603/ahp.2021.0016](https://doi.org/10.5603/ahp.2021.0016).
- Zhang W, Gou P, Dupret JM, et al. Etoposide, an anticancer drug involved in therapy-related secondary leukemia: enzymes at play. *Transl Oncol.* 2021; 14(10): 101169, doi: [10.1016/j.tranon.2021.101169](https://doi.org/10.1016/j.tranon.2021.101169), indexed in Pubmed: [34243013](https://pubmed.ncbi.nlm.nih.gov/34243013/).
- Pullarkat VA, Lacayo NJ, Jabbour E, et al. Venetoclax and navitoclax in combination with chemotherapy in patients with relapsed or refractory acute lymphoblastic leukemia and lymphoblastic lymphoma. *Cancer Discov.* 2021; 11(6): 1440–1453, doi: [10.1158/2159-8290.CD-20-1465](https://doi.org/10.1158/2159-8290.CD-20-1465), indexed in Pubmed: [33593877](https://pubmed.ncbi.nlm.nih.gov/33593877/).
- Lato MW, Przysucha A, Grosman S, et al. The new therapeutic strategies in pediatric T-cell acute lymphoblastic leukemia. *Int J Mol Sci.* 2021; 22(9), doi: [10.3390/ijms22094502](https://doi.org/10.3390/ijms22094502), indexed in Pubmed: [33925883](https://pubmed.ncbi.nlm.nih.gov/33925883/).
- Yeshurun M, Weisdorf D, Rowe JM, et al. The impact of the graft-versus-leukemia effect on survival in acute lymphoblastic leukemia. *Blood Adv.* 2019; 3(4): 670–680, doi: [10.1182/bloodadvances.2018027003](https://doi.org/10.1182/bloodadvances.2018027003), indexed in Pubmed: [30808685](https://pubmed.ncbi.nlm.nih.gov/30808685/).