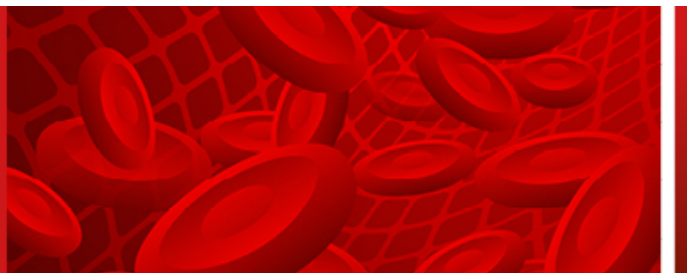


This is a provisional PDF only. Copyedited and fully formatted version will be made available soon.

**Acta Haematologica  
Polonica**



## **Acute intermittent porphyria: a diagnostic challenge.**

**Authors:** Karol Bigosiński, Maciej Dubaj, Aneta Szudy-Szczyrek, Marek Hus

**DOI:** 10.5603/ahp.101063

**Article type:** Clinical vignette

**Submitted:** 2024-06-08

**Accepted:** 2024-08-03

**Published online:** 2024-08-29

This article has been peer reviewed and published immediately upon acceptance.  
It is an open access article, which means that it can be downloaded, printed, and distributed freely,  
provided the work is properly cited.

# Acute intermittent porphyria: a diagnostic challenge

Karol Bigosiński\* , Maciej Dubaj , Aneta Szudy-Szczyrek , Marek Hus 

Department of Hematooncology and Bone Marrow Transplantation, Independent Public Teaching Hospital No 1 in Lublin, Lublin, Poland

## Introduction

Acute intermittent porphyria (AIP) is a metabolic disorder with an autosomal dominant mode of inheritance, and is characterized by a defect in heme biosynthesis. The clinical picture is caused by a deficiency of hydroxymethylbutyrate synthase (HMBS), resulting in an excessive accumulation of heme precursors, namely porphobilinogen (PBG) and  $\delta$ -aminolevulinic acid (ALA). This translates into fairly non-specific symptoms which include abdominal pain, nausea, vomiting and neurological disorders. In Poland, it is diagnosed with a frequency of 1.5/100,000 people, and affects women twice as often as men. Symptoms are paroxysmal, triggered by porphyrinogenic agents, while in a porphyria attack intravenous glucose and hemin should be immediately implemented and the causative agent eliminated. In the absence of an adequate response, severe damage to health and, in extreme cases even death, can result, so a smooth diagnosis remains crucial [1, 2].

## Case report

A 29-year-old female, previously without significant health problems and eight weeks postpartum, was admitted to the surgical ward of a regional hospital in June 2017 because of severe abdominal pain and vomiting of several days' duration. Treatment included diastolic, non-opioid medications and opioid analgesics (metamizole, pyrazolone, phenylbutazone). In view of the lack of effect of conservative treatment and the appearance of acute abdominal symptoms, a laparoscopic appendectomy was performed. In the postoperative period, an exacerbation of previous symptoms was observed in addition to skin hypersensitivity and disturbance of consciousness. A number of laboratory tests were performed, as well as a neurological consultation with

a CT scan of the head without contrast, to which EEG, ENG, and EMG were ordered. The cause of the disorder was not captured. The patient's condition deteriorated rapidly; electrolyte disturbances increased (sodium: 128 mmol/L; reference range: 136–146 mmol/L, serum chloride: 93 mmol/L; reference range: 101–109 mmol/L), laboratory exponents of liver damage were observed (ALT: 239 U/L; reference range: 0.00–35.00 U/L, AST: 215 U/L; reference range: 0.00–35.00 U/L, GGTP: 125 U/L; reference range: 0.00–38.00 U/L).

The diagnostic 'turning point' was the observation of a darkening reaction in a urine sample after exposure to sunlight, which was associated with suspected AIP. Follow-up studies confirmed increased (~10-fold) urinary excretion of PBG and ALA. A diagnosis of the overt form of AIP was established. Intravenous glucose infusions were implemented and a spectacular clinical improvement was achieved. Another attack of AIP occurred six months later, and treatment included hemin and intravenous glucose infusions. Currently, the patient remains in outpatient hematology care. She is permanently off medication, and uses permanent prophylaxis against AIP exacerbations, i.e. adherence to the recommended diet and lifestyle, elimination of porphyrinogenic drugs from use, and control of her menstrual cycle with hormonal pills.

## Discussion

AIP is the most serious disorder of the porphyrin group. The symptoms of the disease are so uncharacteristic that establishing a diagnosis is sometimes very difficult. The so-called porphyrinogenic agents include: chemicals (paints, varnishes, solvents), drugs (carbamazepine, barbiturates, metamizole, erythromycin, ketoconazole, methyl dopa, phenytoin), hormonal changes (changes in progesterone during the course of the monthly cycle and pregnancy,

\*Address for correspondence: Karol Bigosiński, Department of Hematooncology and Bone Marrow Transplantation, Independent Public Teaching Hospital No 1 in Lublin, ul. Staszica 11, 20-081 Lublin, Poland; e-mail: karolbig145a@wp.pl

Received: 06.06.2024 Accepted: 03.08.2024 Early publication: 29.08.2024

This article is available in open access under Creative Commons Attribution-Non-Commercial-No Derivatives 4.0 International (CC BY-NC-ND 4.0) license, allowing to download articles and share them with others as long as they credit the authors and the publisher, but without permission to change them in any way or use them commercially.



Copyright © 2024

The Polish Society of Haematologists and Transfusiology, Institute of Haematology and Transfusion Medicine.

taking oral contraceptives), acute or chronic infections, smoking, alcohol consumption, drug use, intense physical exertion, severe stress, and starvation. Neurological and gastrointestinal signs and symptoms should prompt doctors to consider AIP in the differential diagnosis after ruling out more common causes.

However, it must be borne in mind that an acute attack of porphyria is an immediately life-threatening condition, and in the absence of proper treatment symptoms can lead to quadriplegia, respiratory failure, coma, convulsions, cardiac arrhythmias and eventually death. On the other hand, patients can lead a normal life while following all the recommendations that will protect them from a repeat attack [3, 4]. Currently, patients have the option of prophylaxis in the form of the drug givosyran. This is a synthetic double-stranded small interfering RNA (siRNA) directed against 5-aminolevulinic acid synthase, which causes a reduction in serum ALA and PBG levels. It can be taken from the age of 12 onwards, but it should be noted that this drug has further limited indications due to its proven hepatotoxicity, so regular monitoring of liver function parameters is necessary [5].

## Article information and declarations

### Acknowledgments

Not applicable.

### Authors' contributions

ASS, MH – concept of study, critical review; ASS, KB, MD – data collection; KB, MD – literature review, writing. All authors – final acceptance.

### Conflicts of interest

The authors declare no conflict of interest.

### Ethics statement

Authors declare that informed consent for publication was not obtained, as published data does not allow for patient identification.

### Financial support

None.

### Supplementary material

None.

### References

1. Spiritos Z, Salvador S, Mosquera D, et al. Acute Intermittent Porphyria: Current Perspectives And Case Presentation. *Ther Clin Risk Manag.* 2019; 15: 1443–1451, doi: [10.2147/TCRM.S180161](https://doi.org/10.2147/TCRM.S180161), indexed in Pubmed: [31908464](https://pubmed.ncbi.nlm.nih.gov/31908464/).
2. Bustos J, Vargas L, Quintero R. Acute intermittent porphyria: A case report. *Biomedica.* 2020; 40(1): 14–19, doi: [10.7705/biomedica.4767](https://doi.org/10.7705/biomedica.4767), indexed in Pubmed: [32220159](https://pubmed.ncbi.nlm.nih.gov/32220159/).
3. Valbuena Valecillos A, Yatham P, Alderman M, et al. Acute intermittent porphyria: a review and rehabilitation perspective. *Cureus.* 2023; 15(8): e44260, doi: [10.7759/cureus.44260](https://doi.org/10.7759/cureus.44260), indexed in Pubmed: [37772218](https://pubmed.ncbi.nlm.nih.gov/37772218/).
4. Zhao L, Wang X, Zhang X, et al. Therapeutic strategies for acute intermittent porphyria. *Intractable Rare Dis Res.* 2020; 9(4): 205–216, doi: [10.5582/irdr.2020.03089](https://doi.org/10.5582/irdr.2020.03089), indexed in Pubmed: [33139979](https://pubmed.ncbi.nlm.nih.gov/33139979/).
5. LiverTox: Clinical and Research Information on Drug-Induced Liver Injury [Internet]. Bethesda (MD): National Institute of Diabetes and Digestive and Kidney Diseases; 2012–. Givosiran. 2020 Feb 27. PMID: [32200604](https://pubmed.ncbi.nlm.nih.gov/32200604/).