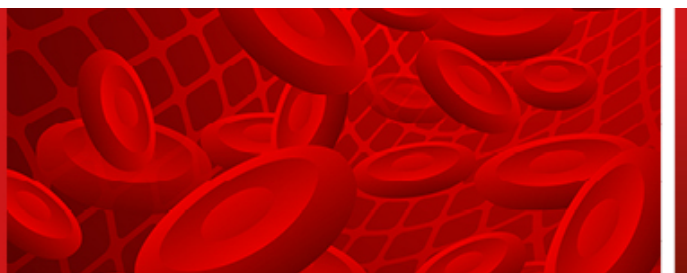


This is a provisional PDF only. Copyedited and fully formatted version will be made available soon.

**Acta Haematologica
Polonica**



Toxic epidermal necrolysis after allogeneic hematopoietic stem cell transplantation for refractory Hodgkin's lymphoma.

Authors: Karolina Chromik, Aleksandra Spyra, Paulina Repa, Grzegorz Helbig

DOI: 10.5603/ahp.100540

Article type: Clinical vignette

Submitted: 2024-05-03

Accepted: 2024-07-14

Published online: 2024-08-29

This article has been peer reviewed and published immediately upon acceptance. It is an open access article, which means that it can be downloaded, printed, and distributed freely, provided the work is properly cited.

Toxic epidermal necrolysis after allogeneic hematopoietic stem cell transplantation for refractory Hodgkin's lymphoma

Karolina Chromik^{1*} , Aleksandra Spyra², Paulina Repa², Grzegorz Helbig¹

¹Department of Hematology and Bone Marrow Transplantation, Medical University of Silesia, Katowice, Poland

²Students' Research Group, Department of Hematology and Bone Marrow Transplantation, Medical University of Silesia, Katowice, Poland

Introduction

Hodgkin's lymphoma (HL) has a favorable prognosis, with a cure rate of c.85% after first-line treatment. For relapsed/refractory (r/r) HL, the standard approach includes high-dose chemotherapy followed by autologous hematopoietic stem cell transplantation (auto-HSCT) [1]. Brentuximab vedotin (BV) and checkpoint inhibitors (CPIs) are used as a bridge to allogeneic HSCT (allo-HSCT) in those patients who relapse after auto-HSCT [1]. Skin lesions are frequently observed in allotransplanted patients, and maculopapular rash as a manifestation of cutaneous acute graft-versus-host disease (aGVHD) is the most common finding [2]. In some patients, toxic epidermal necrolysis (TEN) can occur after allo-HSCT and this poses a diagnostic challenge due to its similarity to aGVHD [3]. Herein, we present the case of a 34-year-old patient with r/r HL who developed life-threatening TEN after allo-HSCT.

Case report

A 24-year-old man was diagnosed with stage IIB nodular sclerosis HL in 2013 based on a histological examination of an excised supraclavicular lymph node. He achieved his first complete remission (CR1) after six cycles of an ABVD regimen (doxorubicin, bleomycin, vinblastine, dacarbazine). Five years later, relapse was detected, and he received two cycles of DHAP (cisplatin, cytarabine, dexamethasone), achieving CR2 consolidated with auto-HSCT. Due to a subsequent relapse, he was treated with 15 cycles of BV, but eventually

progressed. CPI-nivolumab was then initiated with CR3 on a PET scan after the 15th cycle. Three months after the last dose of nivolumab, he underwent allo-HSCT from a 10/10 HLA-matched unrelated donor. Fludarabine (total dose 150 mg/m² IV) and busulfan (total dose 8 mg/kg IV) were used for conditioning, and he received tacrolimus and mycophenolate mofetil for GVHD prophylaxis. The early post-transplant period was complicated by a maculopapular rash covering <50% of the body. He was diagnosed with aGVHD grade 1 according to the Mount Sinai Acute GVHD International Consortium (MAGIC) [4]. Topical treatment with clobetasol and intravenous methylprednisolone pulses were administered, achieving rapid and significant improvement. Two weeks later, he was admitted to the Regional Hematology Unit for recurrent dysuria. At the same time his skin lesions had worsened and progressed to erythroderma and epidermolysis. Methylprednisolone at 500 mg daily was initiated, and the tacrolimus dose was adjusted to the blood trough level.

Unfortunately, extensive erythematous lesions with severe epidermal peeling covered his whole body. Moreover, flaccid vesicles with serous content were visible on the feet (Figure 1A, B). Nikolsky's sign was positive. The complete blood count was normal. Biochemistry revealed elevated lactate dehydrogenase (LDH). Despite the treatment, no improvement was demonstrated, and the patient was admitted to our University Center. Immunosuppressants were slowly tapered. After scrutinized analysis including dermatological consultation, the patient was diagnosed with TEN limited to the skin only. During his stay in our department, CMV and other viral infections were routinely monitored and

*Address for correspondence: Karolina Chromik, Department of Hematology and Bone Marrow Transplantation, Medical University of Silesia, ul. Dąbrowskiego 25, 40–032 Katowice, Poland; e-mail: kchromik@sum.edu.pl

Received: 03.05.2024 Accepted: 14.07.2024 Early publication: 29.08.2024

This article is available in open access under Creative Commons Attribution-Non-Commercial-No Derivatives 4.0 International (CC BY-NC-ND 4.0) license, allowing to download articles and share them with others as long as they credit the authors and the publisher, but without permission to change them in any way or use them commercially.

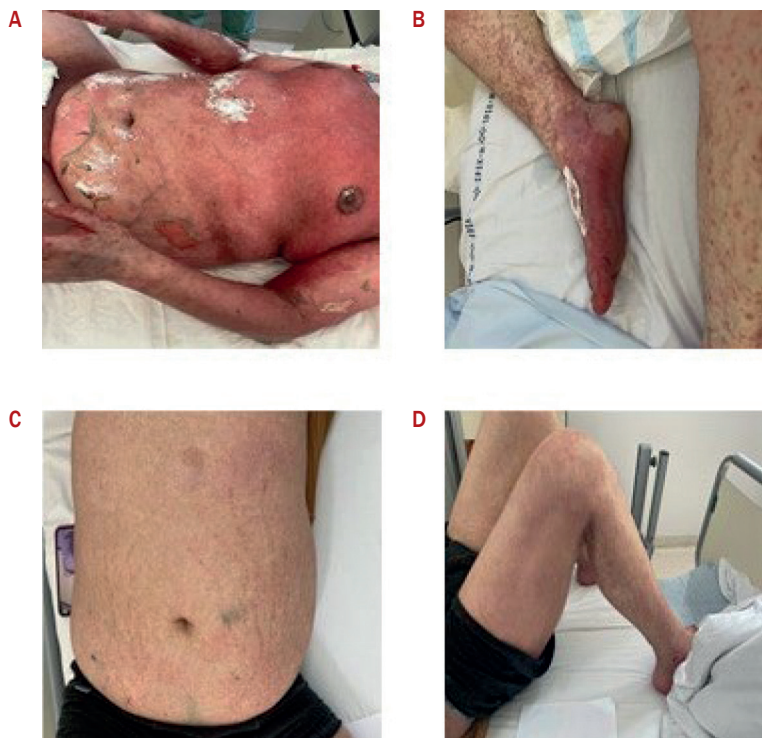

Figure 1. Skin changes in course of TEN before (A, B) and after (C, D) treatment

remained negative. All drugs that are responsible for TEN development and protraction were discontinued. The patient was then transferred to the Burns Center, where surgical treatment with amniotic membranes was used. These were applied over denuded areas, replaced after three days and removed on day 4 of the second application, resulting in a complete resolution of the skin changes (Figure 1C, D). Now, 12 months after allo-HSCT, the patient's condition is stable. The PET scan is free of lymphoma.

Discussion

GVHD is the most common and debilitating complication after allo-HSCT [2]. Some forms of severe aGvHD with bullae, widespread skin involvement and skin sloughing can occasionally bear a striking clinical resemblance to TEN [9]. TEN is a potentially life-threatening acute mucocutaneous syndrome. It is usually caused by an inappropriate immune response to certain drugs, including antibiotics, antiepileptics, non-steroidal anti-inflammatory drugs (NSAIDs), and antivirals [5]. TEN is a rare but possible complication that occurs in fewer than one in 1,000 patients treated with nivolumab [6], a human anti-programmed cell death-1 (anti-PD-1) antibody that triggers a T-cell response that leads to the control of tumors [7]. Several cases of TEN following allo-HSCT have previously been described. Due to bone marrow suppression, the prognosis is poor, and the mortality rate is up to 100% [8].

Both cutaneous aGVHD and TEN are diagnosed mainly on the basis of the rash, making the clinical presentation of both diseases remarkably similar [3]. Some forms of severe aGVHD, especially those with blistering and scaling, cause difficulties in differentiating between GVHD and TEN [9]. Skin biopsy is recommended in all cases despite it not allowing for entirely certain distinction between these entities.

Establishing the correct diagnosis (i.e. aGVHD or TEN) is also important in terms of choosing the most appropriate management. In TEN, firstly the responsible drug should be urgently discontinued [8]. And secondly, broad supportive care with intravenous fluid resuscitation, nutritional support, and amniotic membrane transplantation should be initiated [10]. The use of post-transplantation cyclophosphamide may alleviate the risk of GVHD resulting from prior treatment with a CPI [11].

To the best of our knowledge, we are presenting the first documented case of TEN after allo-HSCT for HL that was successfully treated.

Article information and declarations

Acknowledgments

Not applicable.

Authors' contributions

KC – manuscript preparation; KC, AS, PR – data collection; GH – supervision, final approval.

Conflicts of interest

The authors declare no conflict of interest.

Ethics statement

Authors obtained patient informed consent for publication.

Financial support

None.

Supplementary material

None.

References

1. Ansell SM. Hodgkin lymphoma: 2023 update on diagnosis, risk-stratification, and management. *Am J Hematol*. 2022; 97(11): 1478–1488, doi: [10.1002/ajh.26717](https://doi.org/10.1002/ajh.26717), indexed in Pubmed: [36215668](https://pubmed.ncbi.nlm.nih.gov/36215668/).
2. Dambricourt V, Bassompierre A, Calve CLe, et al. High frequency of cutaneous eruptions within the first year after allogeneic hematopoietic stem cell transplantation. *J EADV Clinical Practice*. 2023; 2(3): 456–464, doi: [10.1002/jvc2.125](https://doi.org/10.1002/jvc2.125).
3. Hung YT, Chen YW, Huang Y, et al. Acute graft-versus-host disease presenting as Stevens-Johnson syndrome and toxic epidermal necrolysis: A retrospective cohort study. *J Am Acad Dermatol*. 2023; 88(4): 792–801, doi: [10.1016/j.jaad.2022.10.035](https://doi.org/10.1016/j.jaad.2022.10.035), indexed in Pubmed: [36280000](https://pubmed.ncbi.nlm.nih.gov/36280000/).
4. Srinagesh HK, Özbek U, Kapoor U, et al. The MAGIC algorithm probability is a validated response biomarker of treatment of acute graft-versus-host disease. *Blood Adv*. 2019; 3(23): 4034–4042, doi: [10.1182/bloodadvances.2019000791](https://doi.org/10.1182/bloodadvances.2019000791), indexed in Pubmed: [31816061](https://pubmed.ncbi.nlm.nih.gov/31816061/).
5. Labib A, Milroy C. Toxic Epidermal Necrolysis. <https://www.statpearls.com/point-of-care/135196> (15.08.2024).
6. Watanabe Y, Yamaguchi Y, Takamura N, et al. Toxic epidermal necrolysis accompanied by several immune-related adverse events developed after discontinuation of nivolumab. *Eur J Cancer*. 2020; 131: 1–4, doi: [10.1016/j.ejca.2020.02.044](https://doi.org/10.1016/j.ejca.2020.02.044), indexed in Pubmed: [32248069](https://pubmed.ncbi.nlm.nih.gov/32248069/).
7. Griffin LL, Cove-Smith L, Alachkar H, et al. Toxic epidermal necrolysis (TEN) associated with the use of nivolumab (PD-1 inhibitor) for lymphoma. *JAAD Case Rep*. 2018; 4(3): 229–231, doi: [10.1016/j.jdc.2017.09.028](https://doi.org/10.1016/j.jdc.2017.09.028), indexed in Pubmed: [29687056](https://pubmed.ncbi.nlm.nih.gov/29687056/).
8. Macedo FI, Faris J, Lum LG, et al. Extensive toxic epidermal necrolysis versus acute graft versus host disease after allogeneic hematopoietic stem-cell transplantation: challenges in diagnosis and management. *J Burn Care Res*. 2014; 35(6): e431–e435, doi: [10.1097/BCR.000000000000040](https://doi.org/10.1097/BCR.000000000000040), indexed in Pubmed: [24476990](https://pubmed.ncbi.nlm.nih.gov/24476990/).
9. Jeanmonod P, Hubbuch M, Grünhage F, et al. Graft-versus-host disease or toxic epidermal necrolysis: diagnostic dilemma after liver transplantation. *Transpl Infect Dis*. 2012; 14(4): 422–426, doi: [10.1111/j.1399-3062.2012.00746.x](https://doi.org/10.1111/j.1399-3062.2012.00746.x), indexed in Pubmed: [22650490](https://pubmed.ncbi.nlm.nih.gov/22650490/).
10. Bashiri Aliabadi S, Haghani Dogahe Z, Feizkhah A, et al. Management of toxic epidermal necrolysis using early combination therapy of intravenous immunoglobulin and amniotic membrane grafting: a case report. *J Burn Care Res*. 2023; 44(2): 467–470, doi: [10.1093/jbcr/irac167](https://doi.org/10.1093/jbcr/irac167), indexed in Pubmed: [36455871](https://pubmed.ncbi.nlm.nih.gov/36455871/).
11. McCurdy SR, Kasamon YL, Kanakry CG, et al. Comparable composite endpoints after HLA-matched and HLA-haploidentical transplantation with post-transplantation cyclophosphamide. *Haematologica*. 2017; 102(2): 391–400, doi: [10.3324/haematol.2016.144139](https://doi.org/10.3324/haematol.2016.144139), indexed in Pubmed: [27846611](https://pubmed.ncbi.nlm.nih.gov/27846611/).