

# Retrograde iliac endarterectomy — modified technique combining conventional surgical and interventional procedures

Alfred Schröder<sup>1</sup>, Kersten Mückner<sup>2</sup>, Steffen Vogel<sup>1</sup>

<sup>1</sup>Klinik für Gefäßchirurgie, Klinikum Chemnitz gGmbH, <sup>2</sup>Department of Clinical Radiology, General Hospital Hamburg-Harburg, Germany

## Abstract

**Background.** Retrograde ring-stripper endarterectomy of iliac arteries through an inguinal approach modified by combining interventional procedures.

**Material and methods.** 52 iliac arteries underwent modified retrograde ring-stripper endarterectomy. Passage of the lesions with a guide wire permits endarterectomy over the wire as a central splint under fluoroscopic control. Residual lesions are corrected by balloon or stent angioplasty.

**Results.** Conversion to a conventional operation was required in 8 limbs. Initial technical success was achieved in 44 limbs. Cumulative secondary patency was 95.8% at 24 months (S.E. 4.7%).

**Conclusion.** Modified ring-stripper endarterectomy with angioplasty is a safe and effective procedure. Long-term results are required.

**Key words:** iliac, occlusion, stenosis, endarterectomy, intraoperative angioplasty, inguinal exposure

## Introduction

The retrograde ring stripper endarterectomy is one of the oldest procedures in vascular surgery. It has been successfully used to treat occlusions of the external iliac artery [1]. On the other hand, for short iliac lesions, predominantly in the common iliac arteries, transluminal angioplasty has demonstrated good results [2]. By combining both techniques it should be possible to treat through a single groin incision extensive lesions, including the common and external iliac arteries as well as the common and deep femoral arteries. It would, moreover, be possible to optimise the results of the retrograde ring stripper endarterectomy. We therefore modified the conventional technique by combining surgical and interventional procedures. Our modified technique has been described previously [3], but can be summarised as follows.

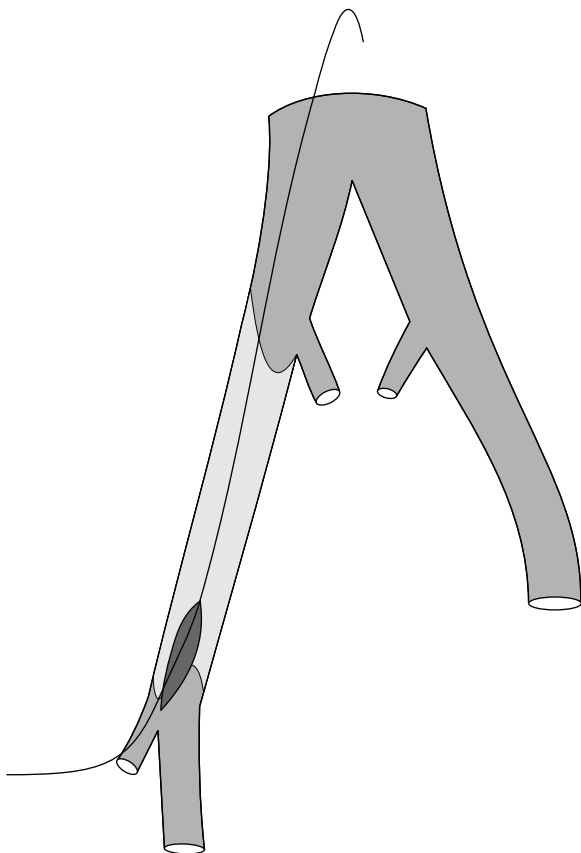
## Technique

After exposure of the femoral bifurcation through a groin incision on the affected side we start by re-

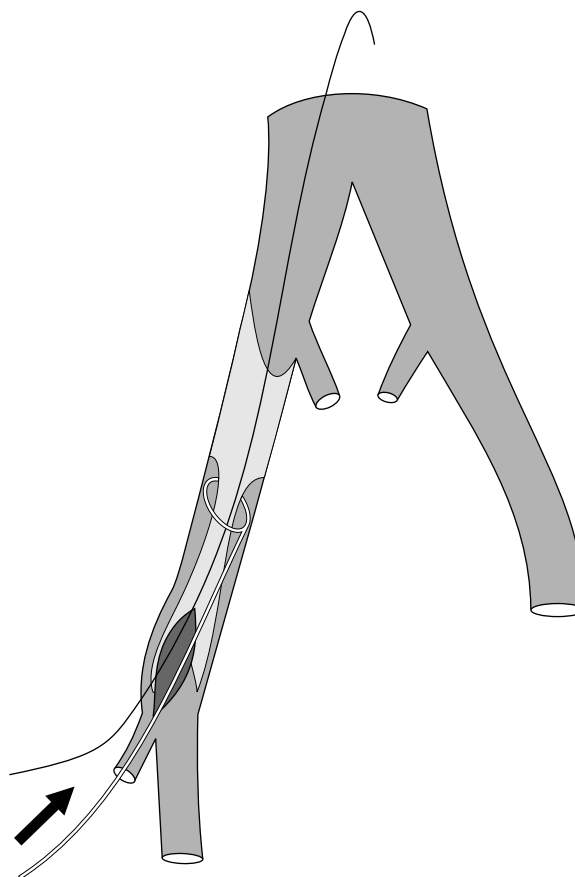
canalising the occluded iliac artery under fluoroscopic control with a combination of a guide wire and an angled directional catheter (Fig. 1). After workmap angiographic documentation, we replace the catheter with a stiff wire positioned high up in the aorta. The stiff wire straightens the frequently elongated iliac artery and serves as a guiding splint when advancing the ring stripper under fluoroscopic control in the cleavage plane obtained after having isolated the endarterectomy core in the common femoral artery (Fig. 2). At the proximal end of the iliac occlusion the endarterectomised intima is torn off by a twisting-pulling manoeuvre of the ring stripper. The endarterectomy core is extracted and a repeated angiography is done through a flush catheter positioned in the distal aorta and through the introducer sheath placed in the endarterectomised lumen of the common femoral artery. In case the angiography demonstrates a residual stenosis, an intimal flap or a dissection at the proximal endpoint of the retrograde endarterectomy, balloon an-

Address for correspondence (Adres do korespondencji):

Dr med. Alfred Schröder, Klinik für Gefäßchirurgie, Bürgerstraße 2, 09–113 Chemnitz, Germany  
 tel 0371 333 43435, fax 0371 333 43433, e-mail: a.schroeder@skc.de



**Figure 1.** Retrograde ring-stripper endarterectomy: recanalising with a guide wire under fluoroscopic control



**Figure 2.** Retrograde ring-stripper endarterectomy: advancing the ring-stripper with a stiff wire as a splint under fluoroscopic control

gioplasty or stent deployment is performed to ensure the anatomic adequacy of the procedure (Fig. 3).

The described manoeuvres are, however, not always feasible. If the wire passage through the occluded iliac artery from the ipsilateral side fails, the first alternative is the retrograde ring-stripper endarterectomy without a guide wire as a central splint, but still under fluoroscopic control. A further attempt to pass the guide wire ipsilaterally follows. If it fails, a second alternative is to puncture the contralateral groin and to insert a crossover guide wire over the aortic bifurcation into the origin of the occluded iliac artery. By means of a sidewinder type catheter, the crossover wire is manoeuvred through the remaining proximal iliac occlusion. The wire is caught through the arteriotomy in the ipsilateral groin. Over the crossover wire an ipsilateral catheter is guided into the aorta and replaced by a stiff wire. Finally we have guide wires on both sides and we can do all the manoeuvres required, including stentangioplasty in the kissing balloon technique in order to obtain the optimal result shown in completion angiography (Fig. 4a, b). Eventually the arteriotomy is usually extended into the

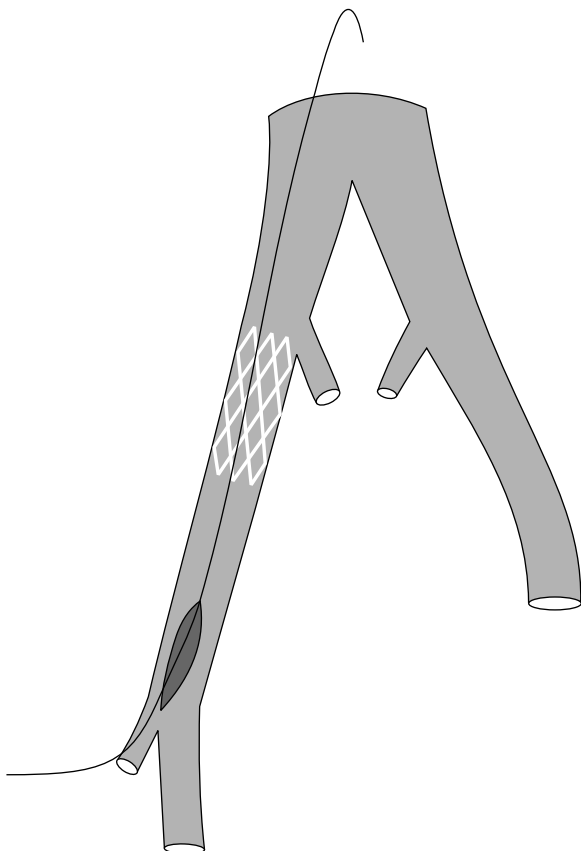
deep femoral artery, permitting endarterectomy and patchplasty.

### Patients

Between January 1999 and March 2001 52 iliac arteries in 51 patients underwent retrograde iliac endarterectomy by the described technique. The patients were followed prospectively in our institution (Klinikum Chemnitz). The median age was 64 years (range 41–84). Long occlusions including the common and external iliac arteries were present in 3 limbs, occlusion of the common iliac artery in 4 limbs, occlusions or extensive stenoses of the external iliac artery in the remaining 45 limbs.

### Results

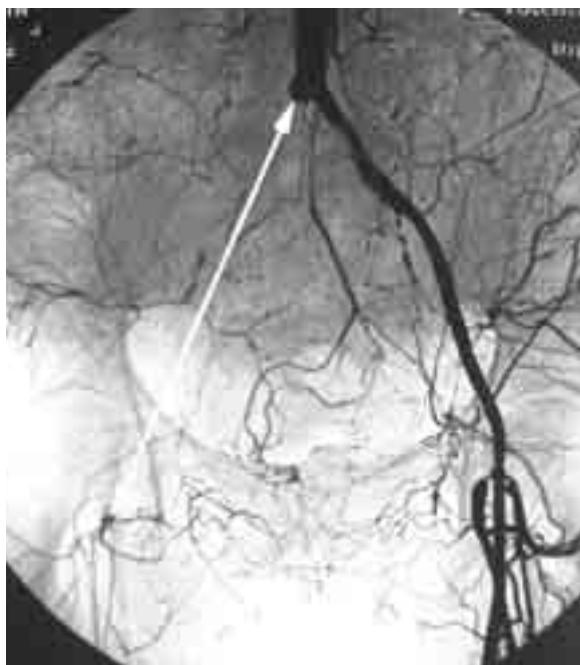Technical failure requiring conversion to a standard operative procedure occurred in 8 limbs (15%), one of which had occlusions of the common and external iliac artery, and two of the common iliac artery. In 7 cases ipsilateral passage of the iliac lesion could not be realised. In two of these 7 cases crossover passage of



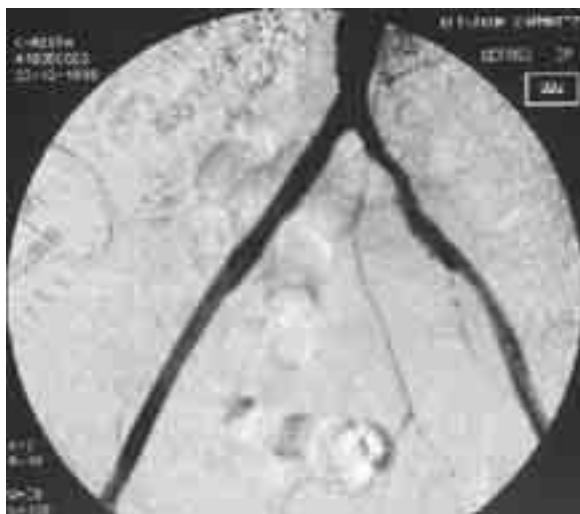**Figure 3.** Retrograde ring-stripper endarterectomy: stent angioplasty of residual lesion after endarterectomy and femoral patchplasty

a guide wire from the contralateral groin was tried and failed. A further attempt of retrograde ring stripper endarterectomy without the guide wire in four cases resulted in incomplete desobliteration or dissection. In one case after successful passage of the wire the ringstripper could not be advanced in a retrograde fashion. Conversion operations consisted of thrombendarterectomy from an extraperitoneal approach in 4 of 8 failures, in an ipsilateral bypass procedure in one and in crossover bypasses in three cases, one of which needed an additional stent angioplasty of the donor iliac artery.

Immediate technical success was achieved in the remaining 44 limbs. Ipsilateral guide wire passage prior to recanalisation was achieved in 22 of 44 limbs. Ipsilateral wire passage after recanalisation by ring stripper endarterectomy without a guide wire as a central splint was successful in 16 cases. In the remaining six cases the guide wire was inserted through the lesion by the crossover manoeuvre. Recanalisation was obtained by ring stripper endarterectomy in all 44 cases. To ensure technical success and anatomic adequacy, recanalisation required additional angioplasty in 41 of



**Figure 4a.** Preoperative angiography showing a long occlusion of the common and external iliac artery



**Figure 4b.** Intraoperative completion angiography after modified ring-stripper endarterectomy and stent angioplasty

44 cases (93%), 12 of which had a balloon angioplasty, 29 a stent angioplasty.

Adjunctive procedures to ensure an adequate outflow consisted in patchplasty of the common femoral artery, femoral bifurcation or profunda femoris in all 44 cases, combined with thrombendarterectomy in most cases.

The mean operation time (skin-to-skin) was 147 min (range 90–245) in the 44 successful cases, the mean blood loss 155 mL (range 50–450).

Postoperative complications consisted in superficial wound infections in 3 cases. No death and no early occlusion of the recanalised iliac artery occurred. The patency rate was calculated according to the life table method [4]. Cumulative secondary patency was 95.8% at 24 months (S.E. 4.7%), one occlusion occurred, one redo operation with stent angioplasty was necessary to preserve patency after an initial retrograde endarterectomy without additional angioplasty.

### Discussion

In the past the technique of retrograde ring-stripper endarterectomy was limited to lesions of the external iliac artery. Residual stenoses and intimal flaps moreover limited the early and late results of the conventional technique. Technical feasibility of our modified retrograde iliac endarterectomy technique, which was demonstrated in an earlier series published in 1998 [3], was confirmed in the present series of 44 successful cases. Even extensive stenoses and occlusions of the common and external iliac arteries could be included. Residual lesions after retrograde ring stripper endarterectomy in 93% of cases could be adequately corrected by combining balloon or stent angioplasty. The 24-month results with 95.8% secondary patency are encouraging but do not yet allow for long-term follow-up. Our early results show a decreased mortality and morbidity when compared to the results of transabdominal reconstructive procedures. Moreover, exposure of the aortic bifurcation, which is often associated with loss of sexual potency, is avoided. Performing a retrograde iliac endarterectomy through an inguinal approach would also be especially valuable in cases of a 'hostile abdomen' due to numerous previous laparatomies.

An alternative technique with low morbidity and mortality for extensive iliac lesions is femoro-femoral or iliofemoral crossover bypass. The crossover bypass may be combined with angioplasty of the donor vessel [5]. However, the infection rate of prosthetic crossover bypasses may be higher [6]. The crossover bypass, therefore, has become a second choice procedure in our institution.

The mean operating time of 147 min is obviously longer than that of a conventional unilateral iliac reconstruction or a crossover bypass. The procedure time however tends to fall with experience. The blood loss in the present series was very low (155 mL). The

conversion rate, however, is rather high (15%) and is related to the willingness to abandon the described technique in favour of a conventional operative procedure after a short trial time. We feel this willingness should be higher when the vascular surgeon is equally qualified to perform both procedures, the conventional surgical and the interventional, thereby reducing the operating time. Although experience shows that heavily and extensively calcified vessels are less suited to the described technique of retrograde ring-stripper endarterectomy, the degree of vessel calcification is not predictive of the failure to achieve the procedure. Our data so far do not allow a precise selection of lesions best suited to our technique. We are however convinced that the advantages of the described technique outweigh a rather high conversion rate and longer operating time.

Our present strategy is to try our described technique in all cases of extensive stenoses of the external and common iliac artery and of occlusions of the external iliac artery with or without additional stenoses of the common iliac artery. In cases of long occlusions of the common and external iliac artery our first choice is a crossover prosthetic bypass except in those cases where local or general conditions predict an increased infection risk. Here again our first choice is our modified ring-stripper endarterectomy.

### References

1. Vollmar J (1982) *Rekonstruktive Chirurgie der Arterien*. Georg Thieme Verlag, Stuttgart, New York, 298–301.
2. Sullivan TM, Childs MB, Bacharach JM, Gray BH, Piedmonte MR (1997) Percutaneous transluminal angioplasty and primary stenting of the iliac arteries in 288 patients. *J Vasc Surg*, 25: 829–839.
3. Schröder A, Mückner K, Riepe G, Siemens P, Gross-Fengels W, Imig H (1998) Semiclosed iliac recanalisation by an inguinal approach — Modified Surgical techniques integrating interventional procedures. *Eur J Vasc Endovasc Surg*, 16: 501–508.
4. Rutherford RB, Baker JD, Ernst C, Johnston KW, Porter JM, Ahn S, Jones DN (1997) Recommended standards for reports dealing with lower extremity ischemia: Revised version. *J Vasc Surg*, 26: 517–538.
5. Schröder A, Gross-Fengels W, Daum H, Riepe G (1994) Percutaneous transluminal angioplasty combined with surgery to treat bilateral iliac occlusive disease. *Langenbecks Arch Chir Suppl Kongressbd*, 970–975.
6. Schweiger H, Storz W (1993) Bypass oder Thrombendarterektomie? — Rekonstruktive Verfahren der arteriellen Verschlusskrankheit in der Beckenenge. *Chirurg*, 64: 259–263.